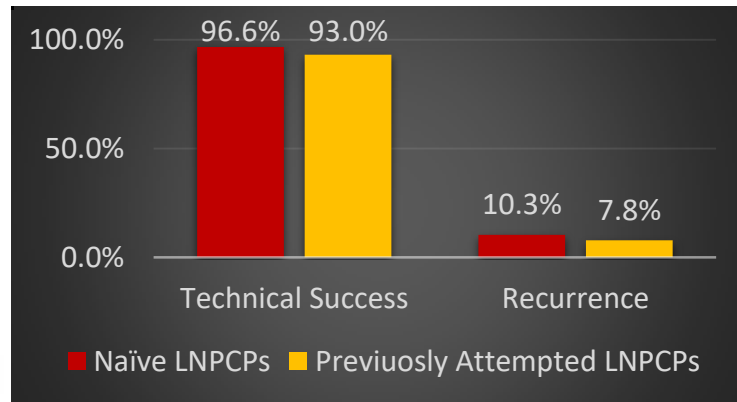
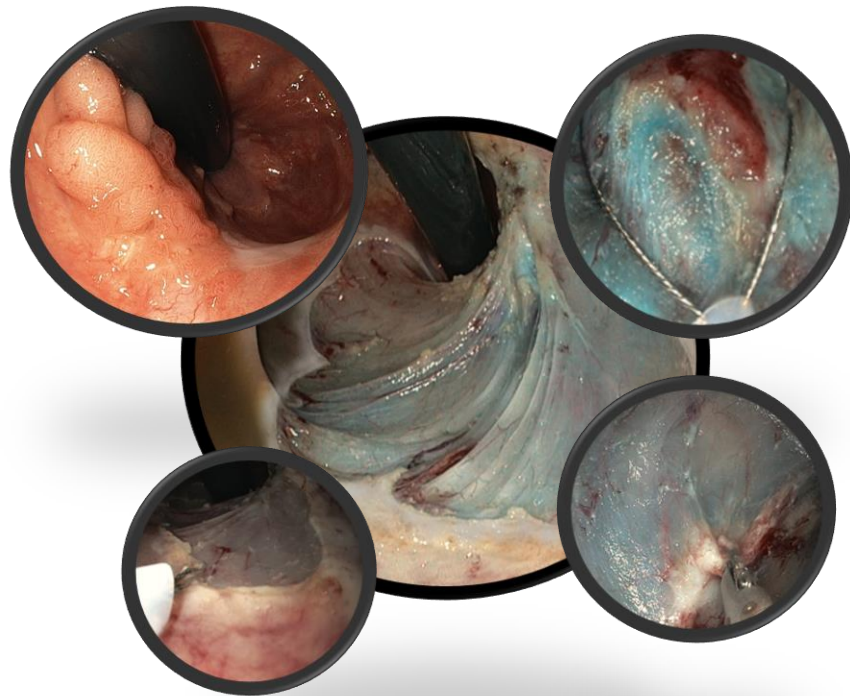


Previously attempted large non-pedunculated colorectal polyps are effectively managed by endoscopic mucosal resection



Using evidence-based auxillary techniques, previously attempted LNCPs ≥ 20 mm are effectively managed by EMR