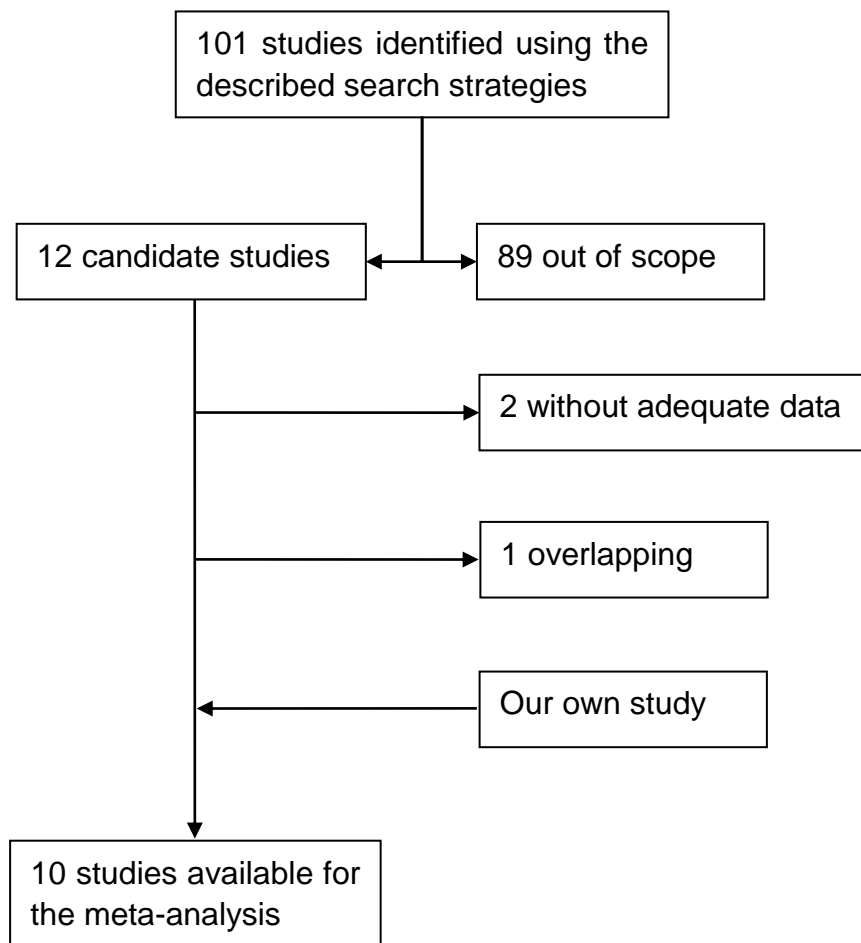


Supplement figure 1. Representative results of immunohistochemistry of HIF-1 α in cervical cancer tissues are shown. HIF-1 α was overexpressed predominantly in nuclear. A, weak expression; B, moderate expression; and C, strong expression. ($\times 400$)



Supplement figure 2: Flow chart of the meta-analysis