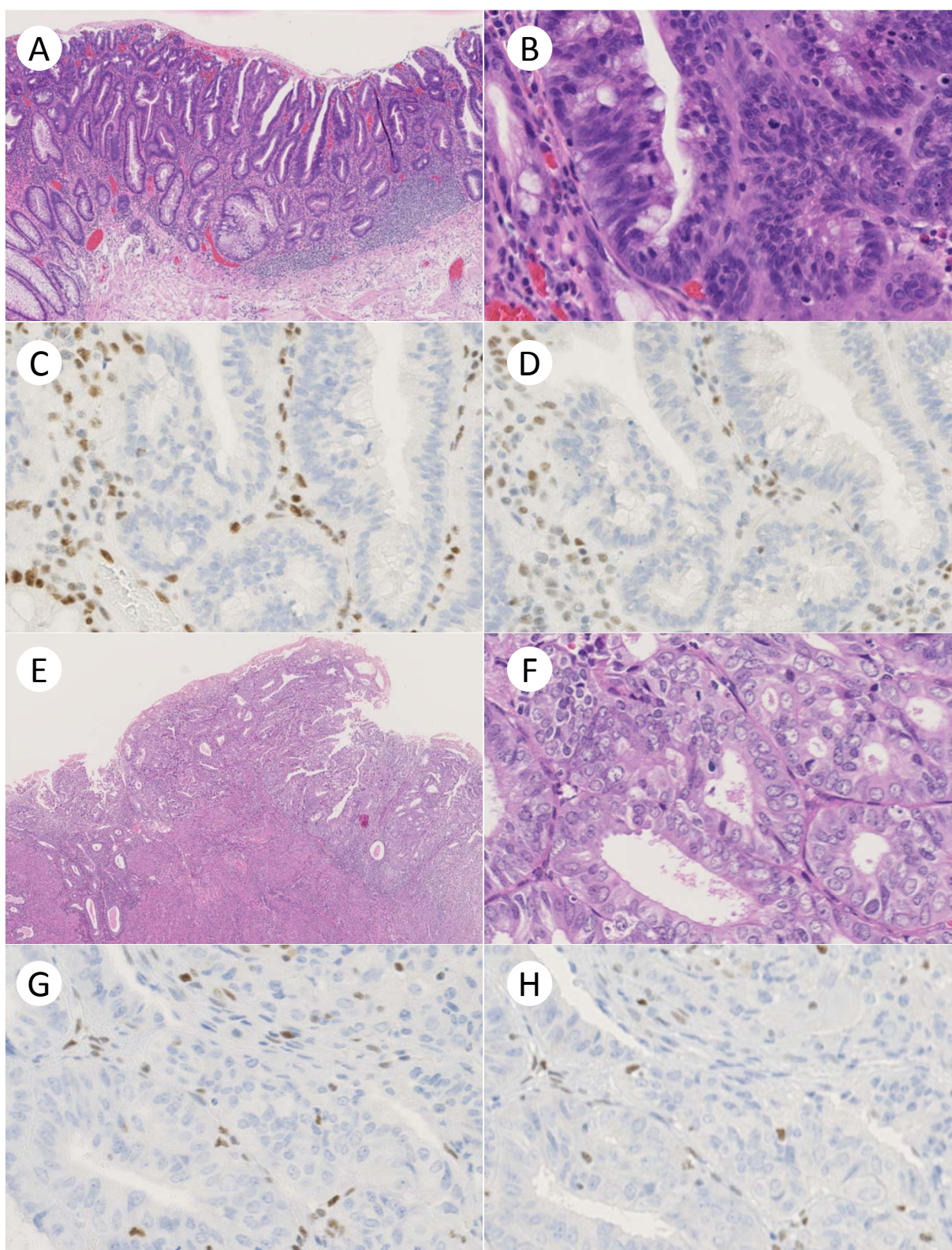
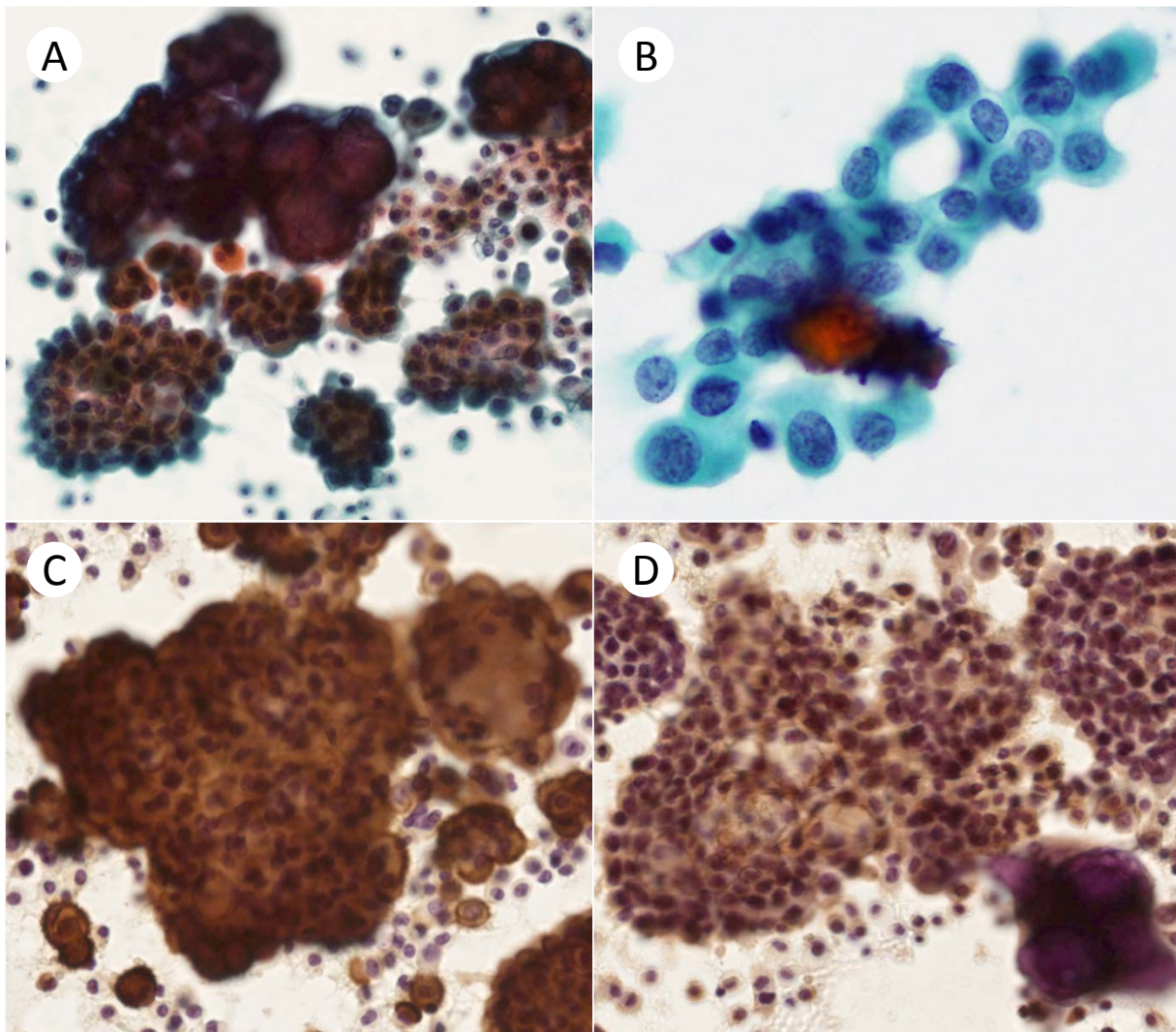


Supplementary Figure 1. Pathological findings of the past colon cancer and endometrial cancer





Supplementary Figure 2. Cytopathological findings of peritoneal fluid



Supplementary Figure 3. Immunohistochemical staining of PAX8

