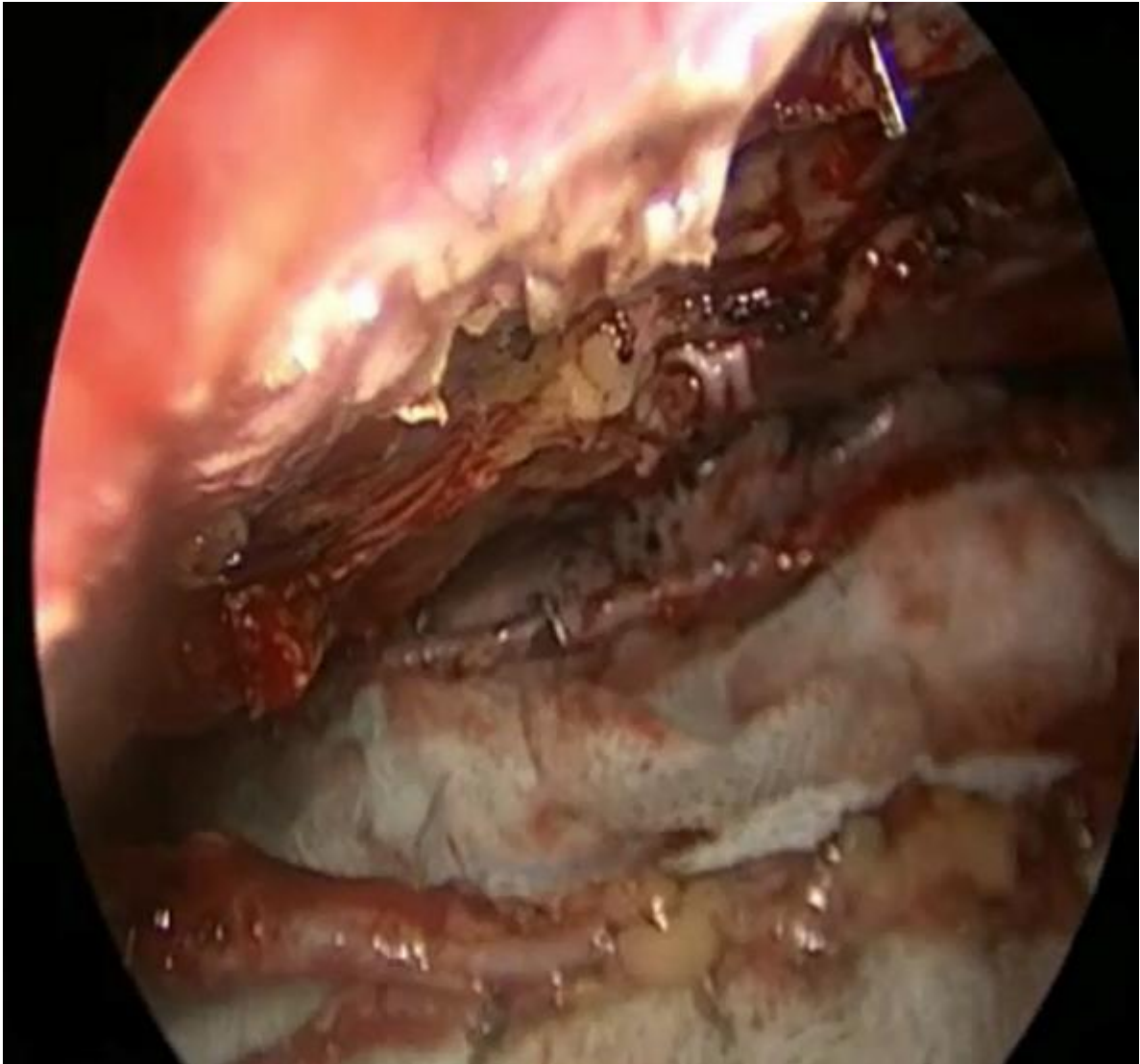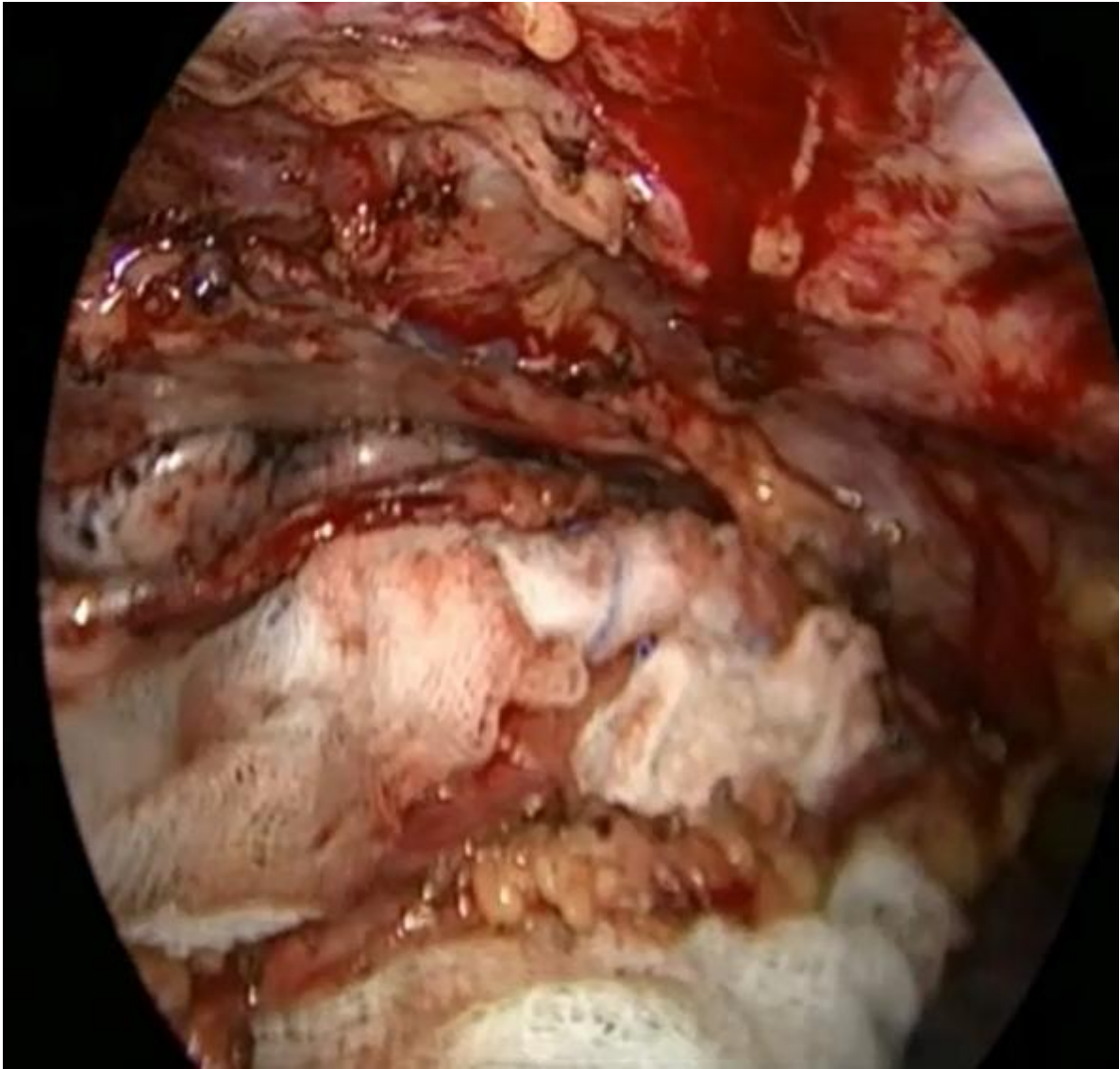
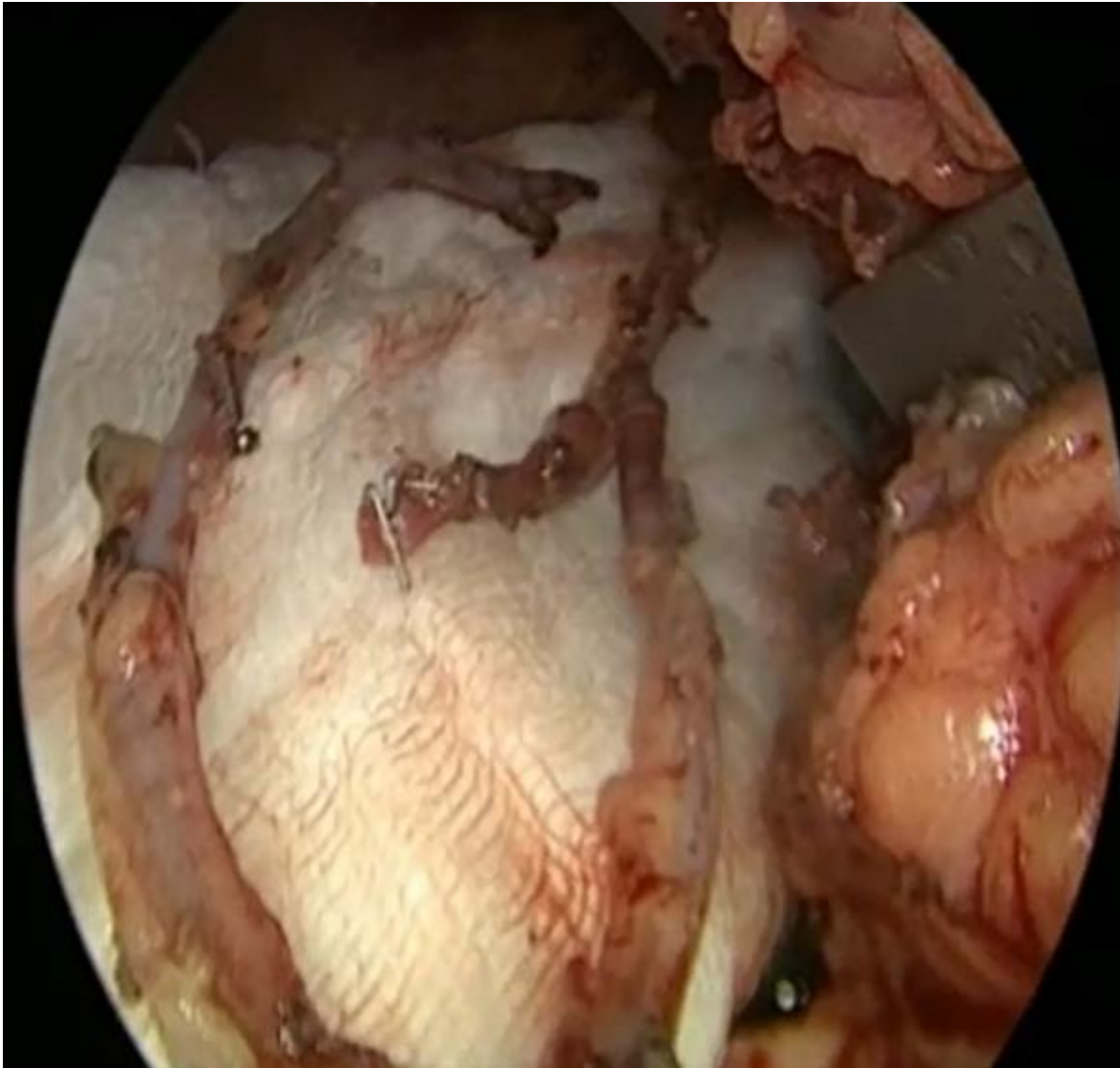


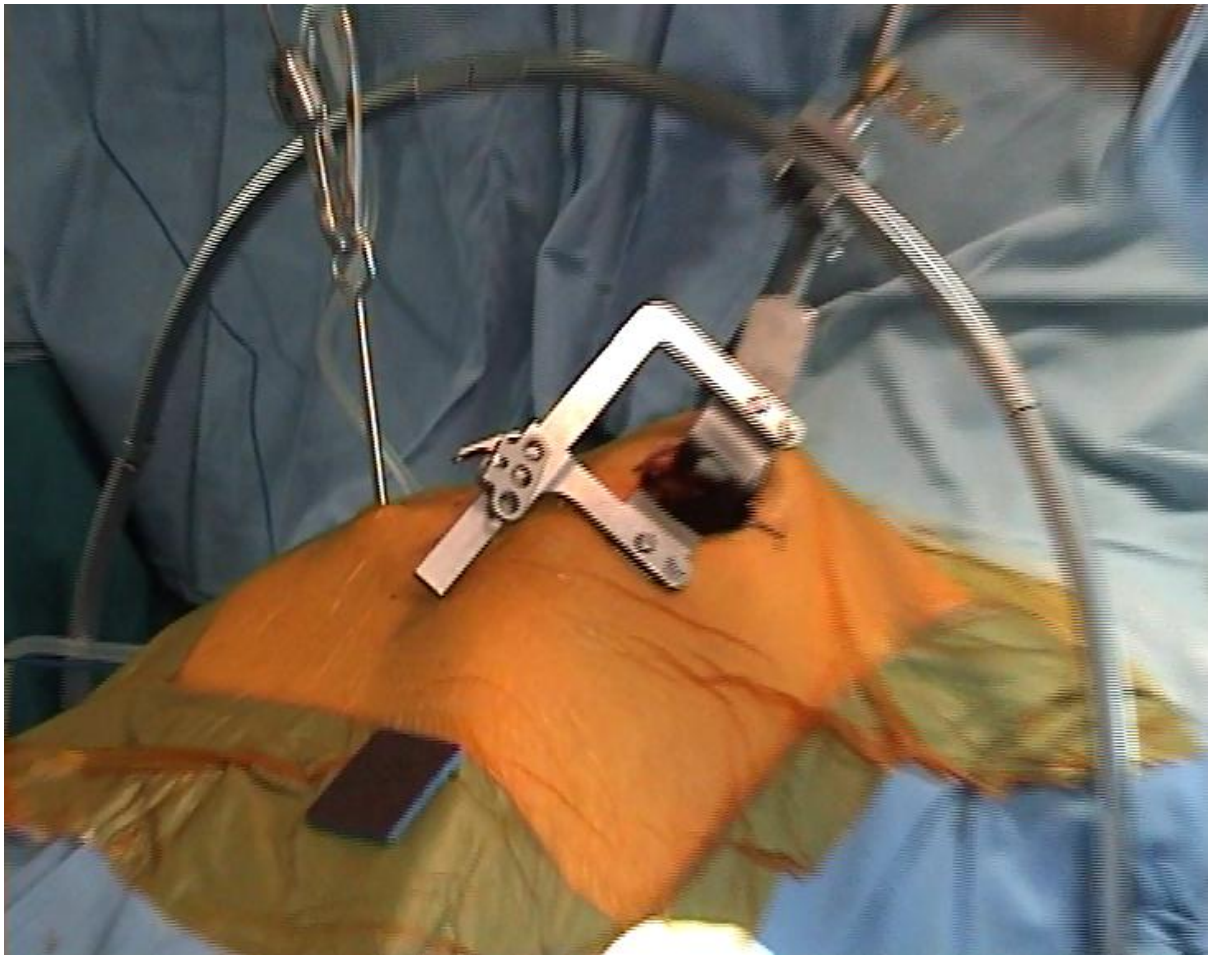
Harvested Right Internal Thoracic artery – Left Internal Thoracic artery distal view



Harvested Left Internal Thoracic artery – Right Internal Thoracic artery proximal view



Left Internal Thoracic artery – Right Internal Thoracic artery Y composite conduit



Set up for Minimally Invasive Coronary Surgery (Close up)