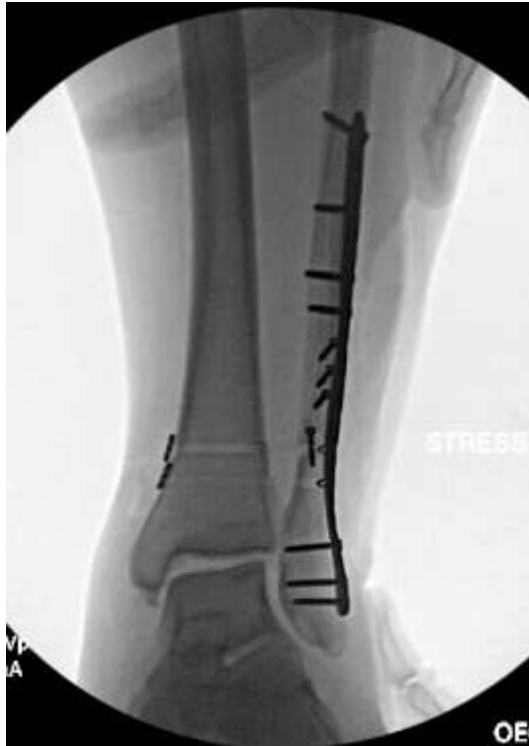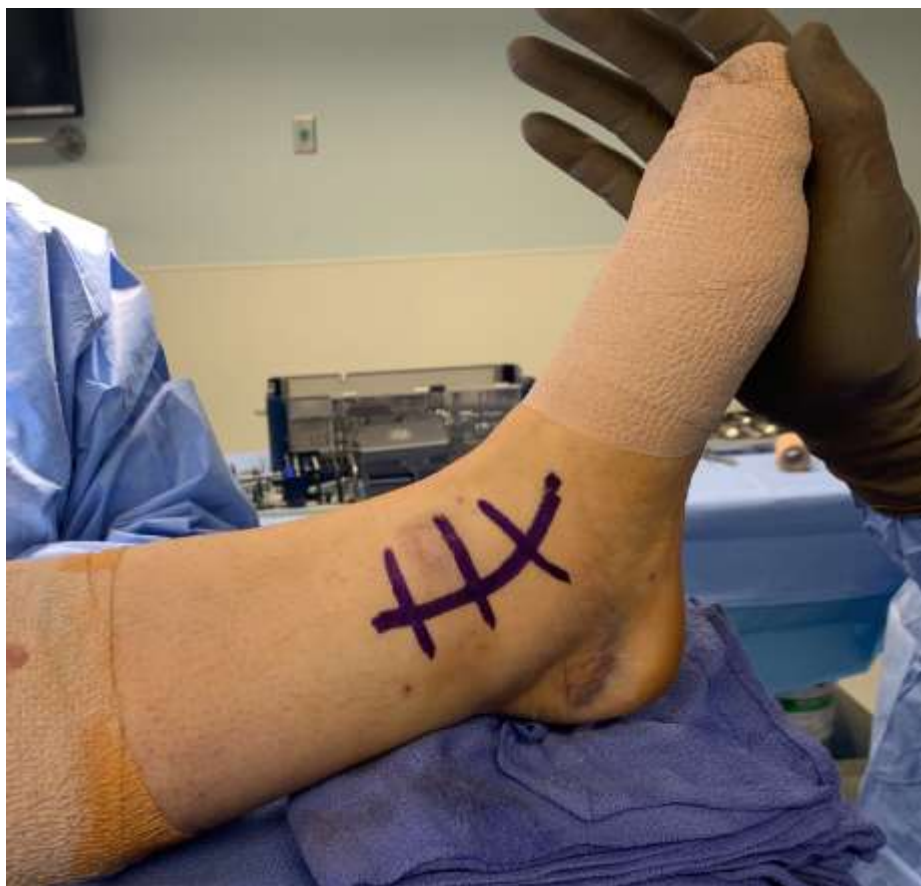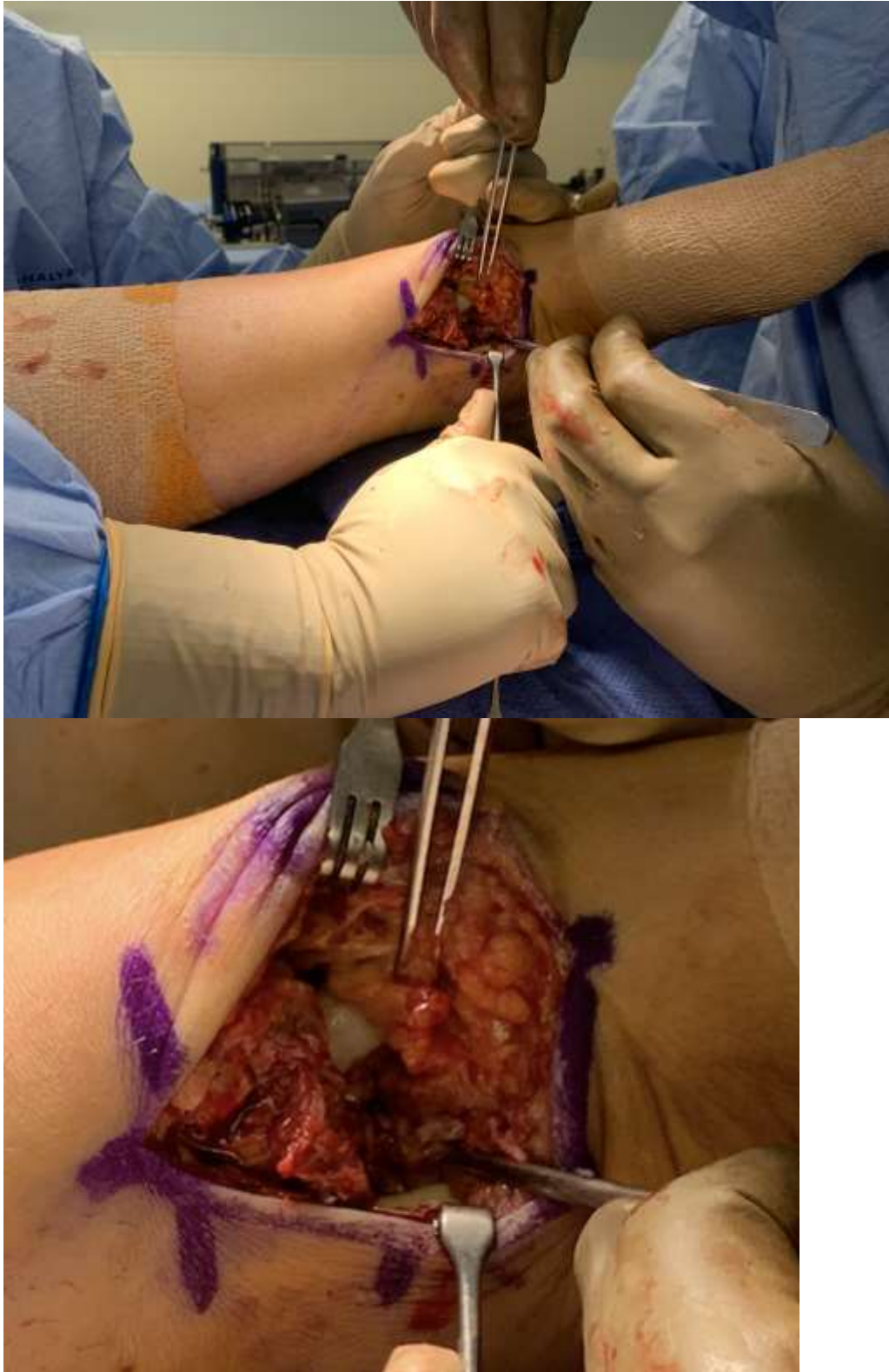




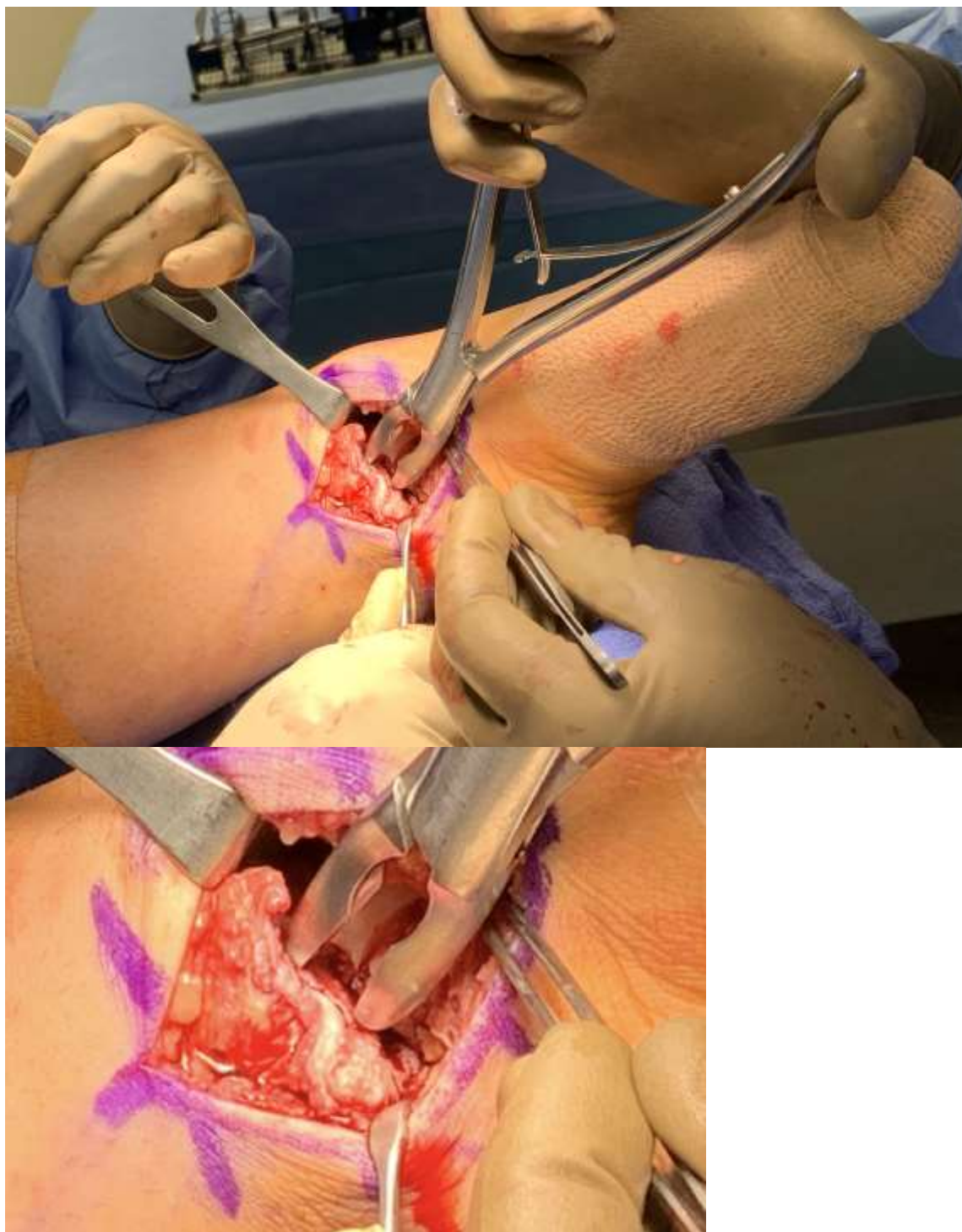
Supplemental Image 1 – Continued valgus talar tilt despite lateral column and syndesmotic fixation



Supplemental Image 2 – Curvilinear incision at medial ankle

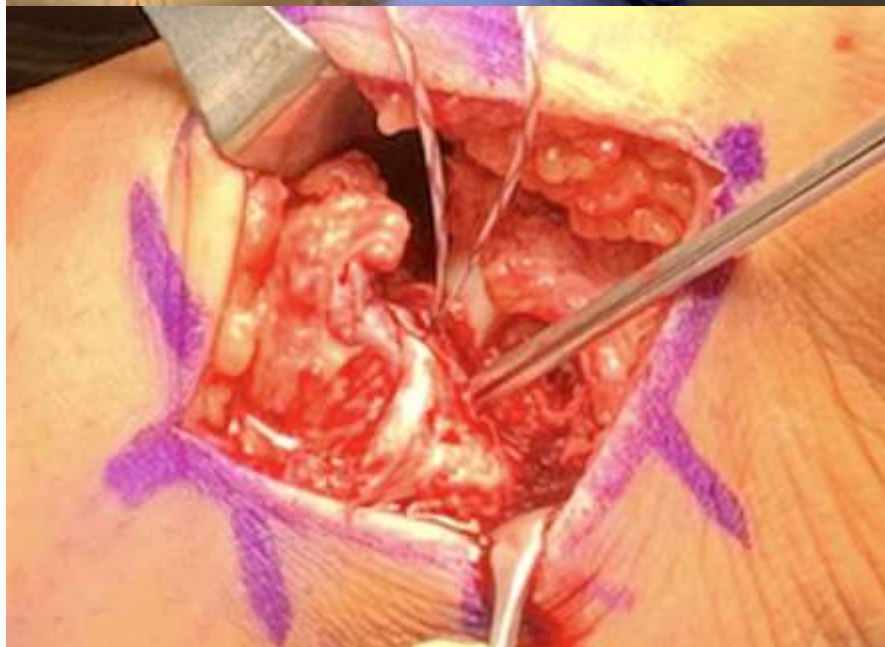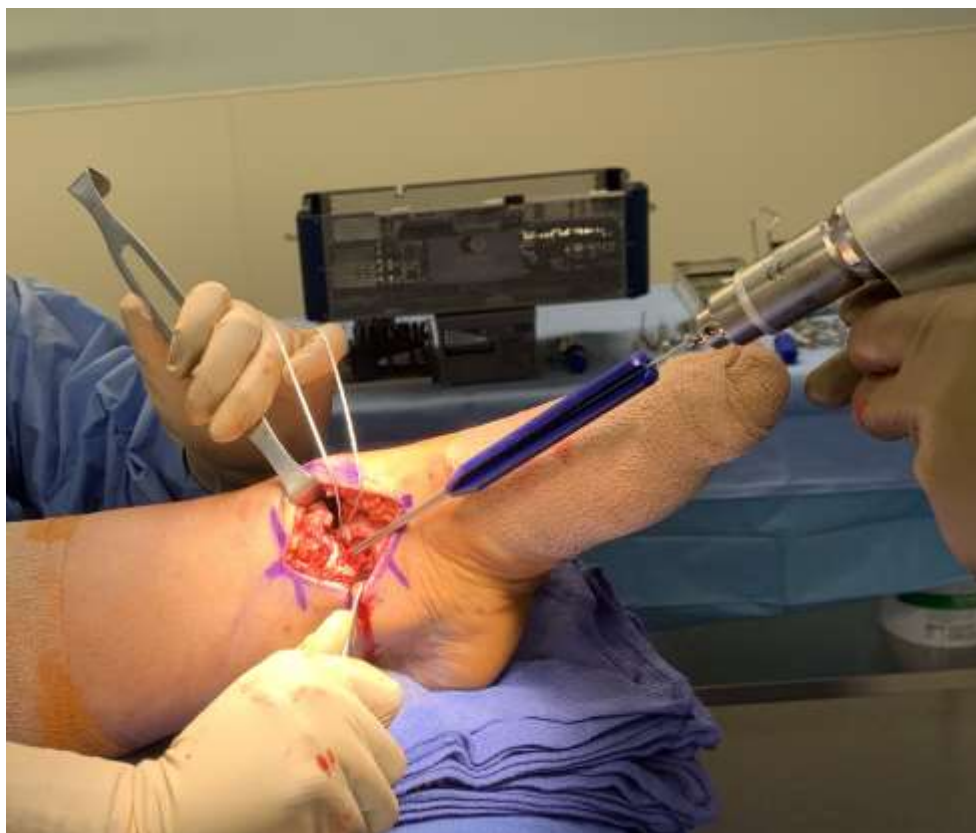


Supplemental Image 3 – Demonstrating the complete deltoid ligament avulsion off medial malleolus with talar dome cartilage showing deep as well as the posterior tibial tendon posteriorly in the incision (with zoomed in version).

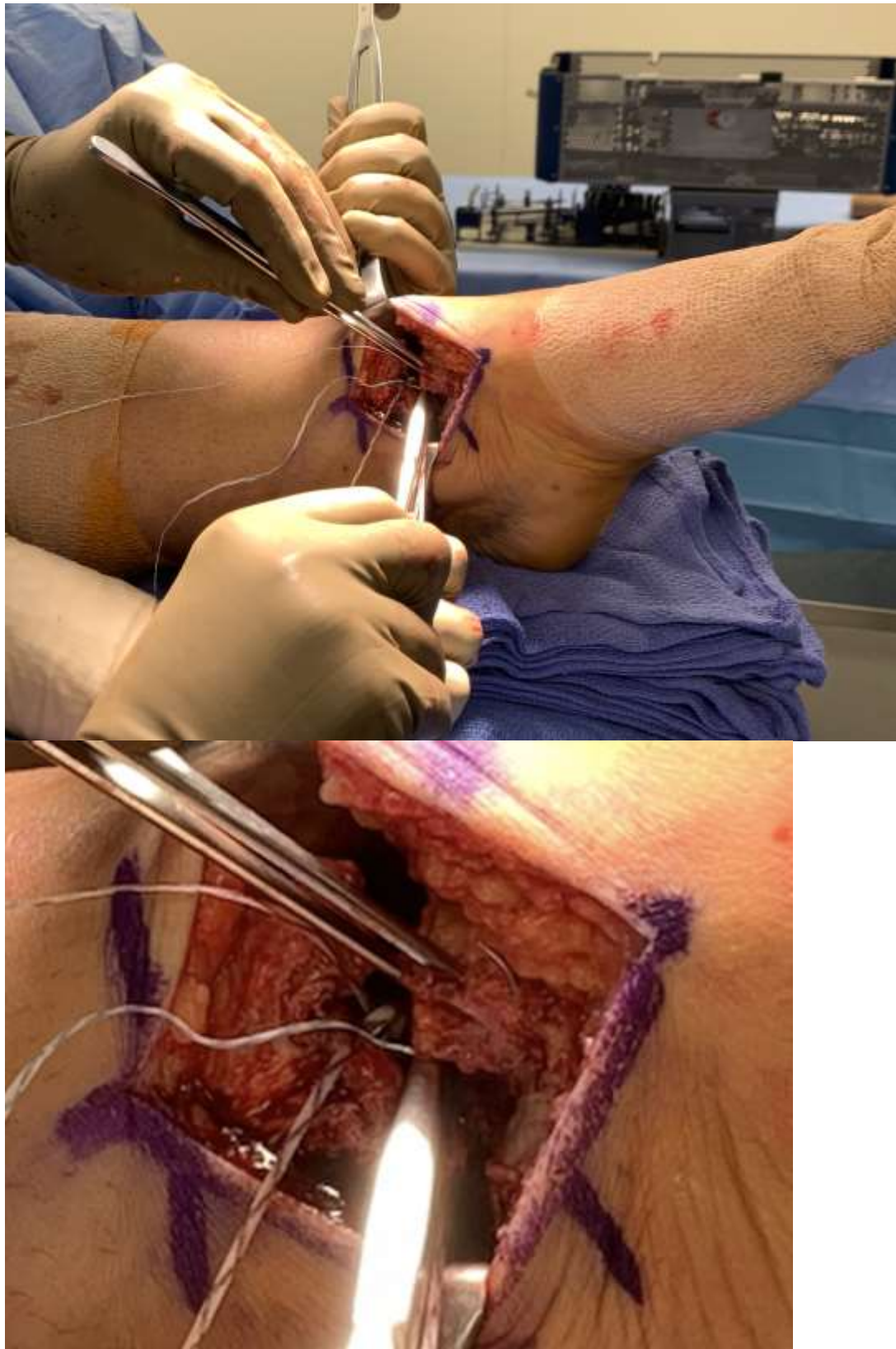


Supplemental Image 4 – Rongeur at tip of medial malleolus to create bleeding cancellous bony surface prior to anchor placement (with zoomed in version).



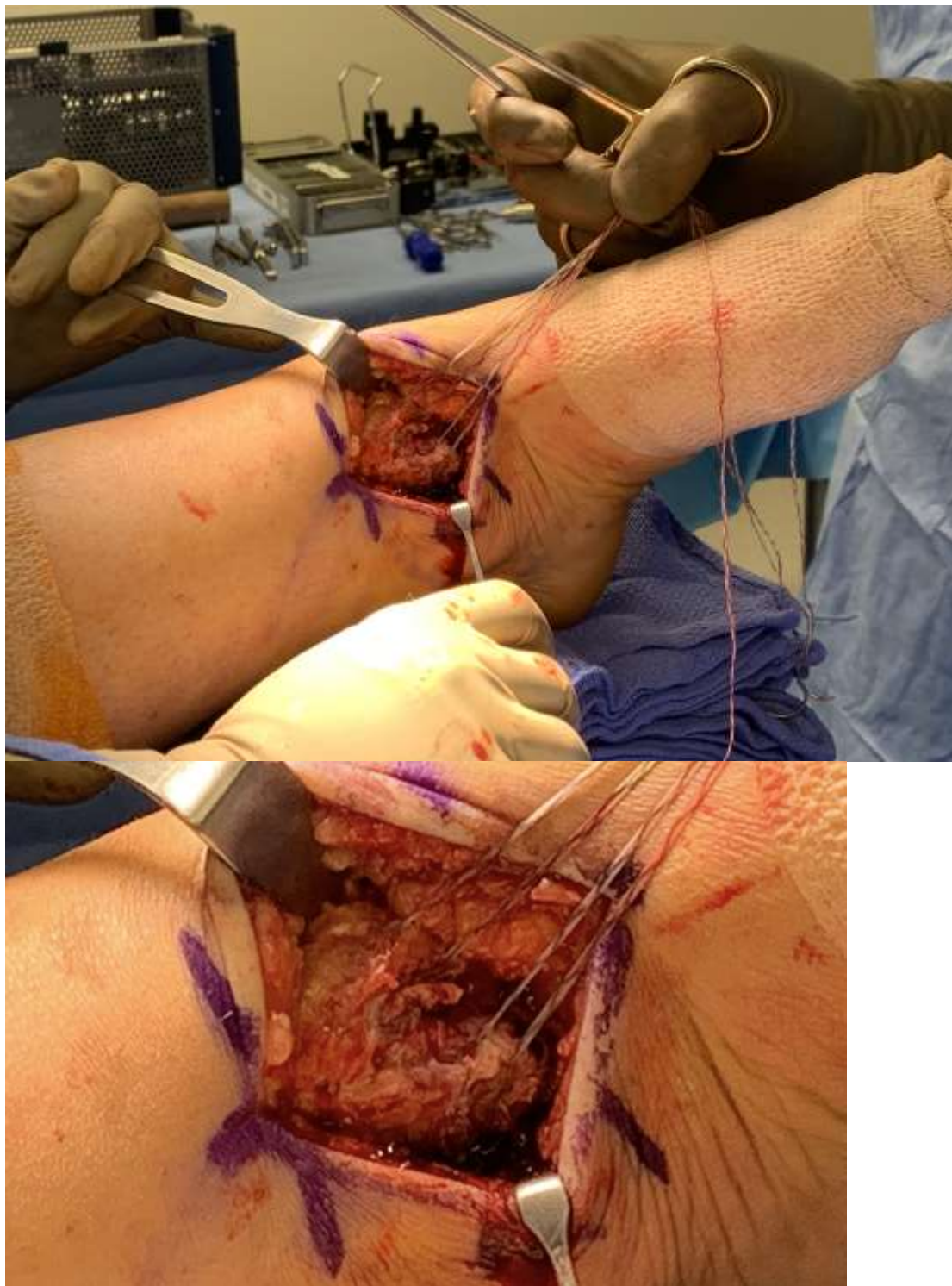


Supplemental Image 5 – Drilling two suture anchors 1 cm apart from each other at tip of the medial malleolus (with zoomed in version).

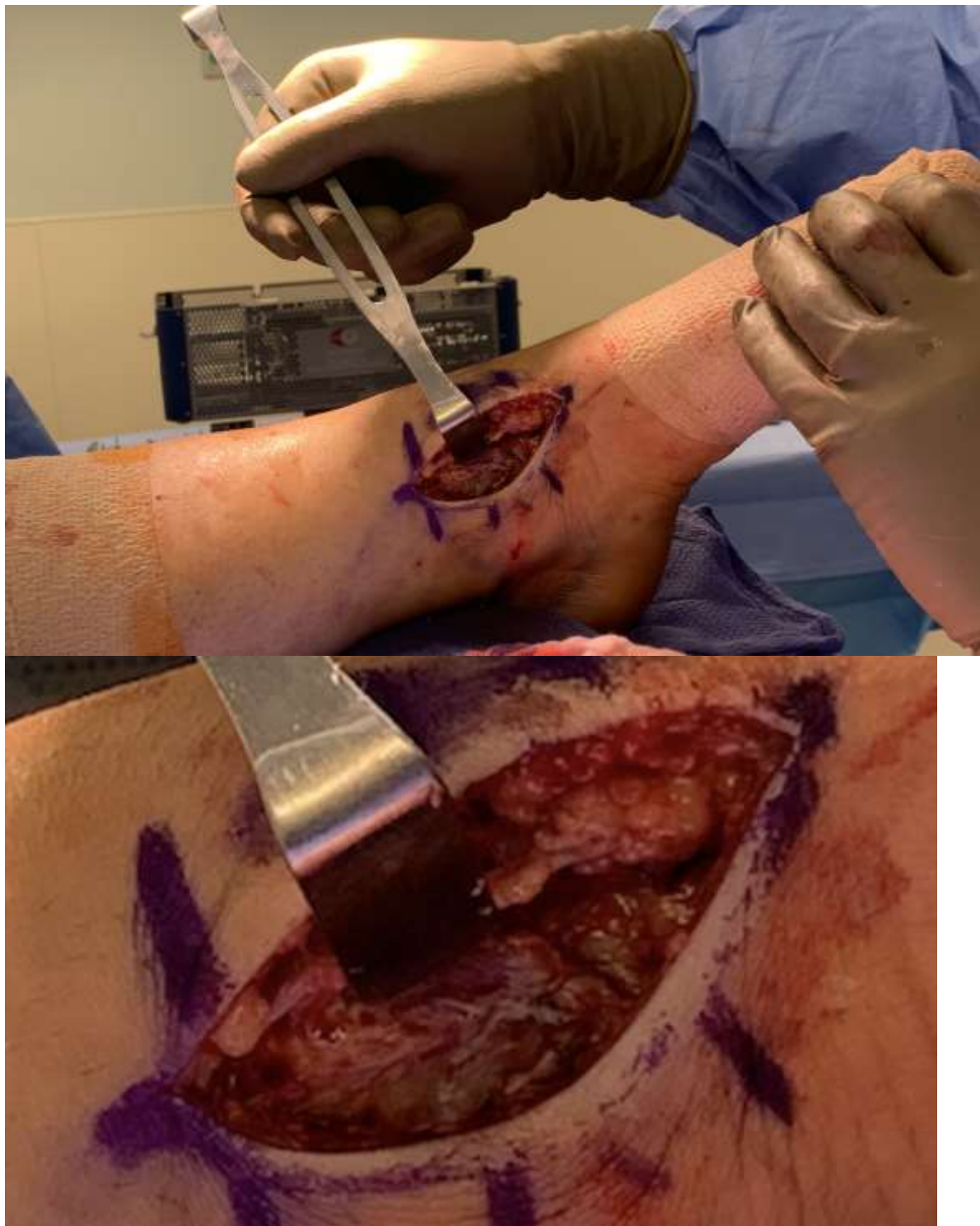

Supplemental Image 6 – Horizontal mattress sutures placed through deltoid tissue (with zoomed in version).



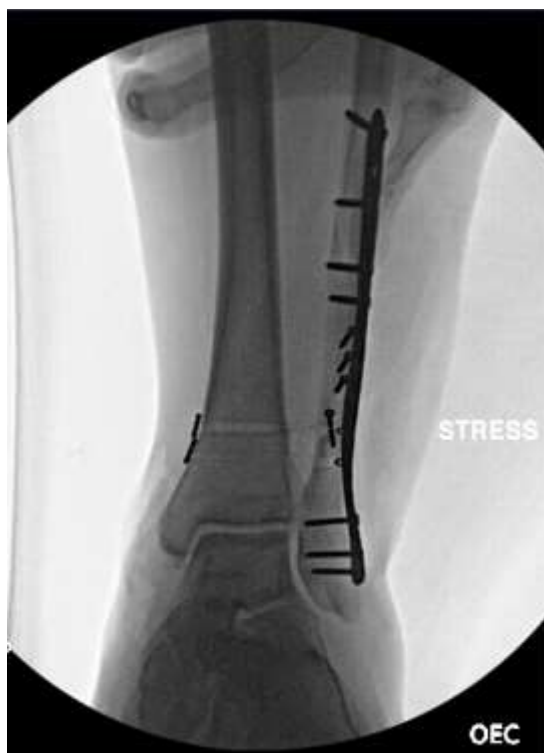

Supplemental Image 7 – Tensioning the sutures with ankle held in slight inversion (with zoomed in version).



Supplemental Image 8 – Repair demonstrating confluence of deltoid ligament tissue (with zoomed in version).





Supplemental Image 9 – Stable ankle mortise after deltoid ligament repair