

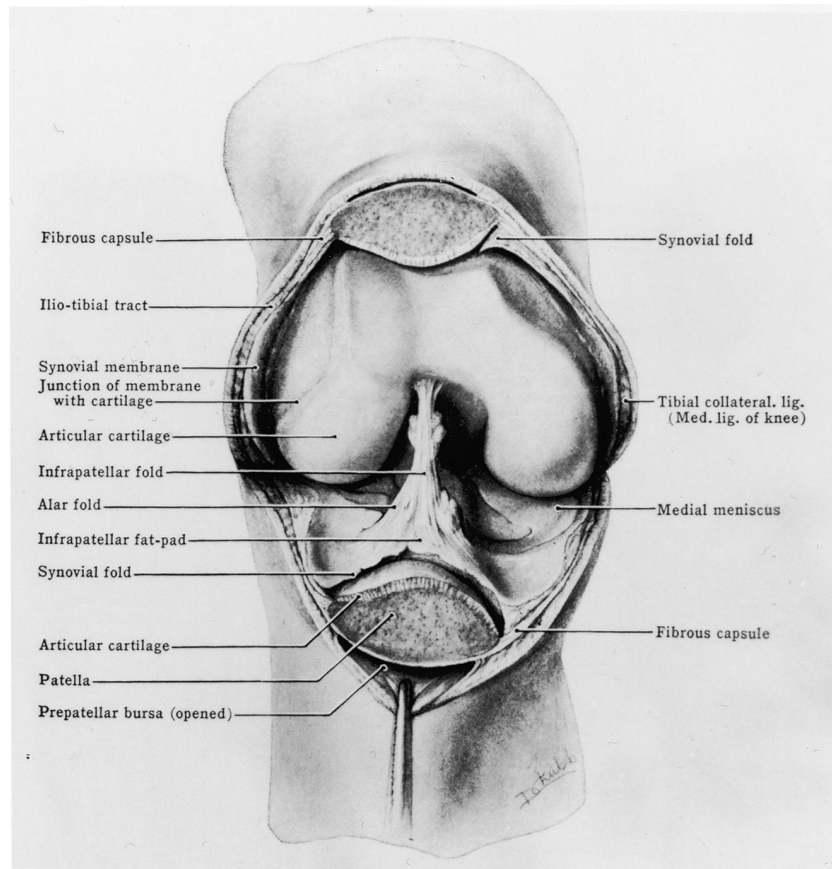Fig. E-1

Illustration from *Grant's Atlas of Anatomy*, eighth edition, showing a single prepatellar bursa (opened). From: Grant JCB. *Grant's atlas of anatomy*. 8th ed. Anderson JE, editor. Baltimore: Williams and Wilkins; 1983. Permission was granted to use this figure.

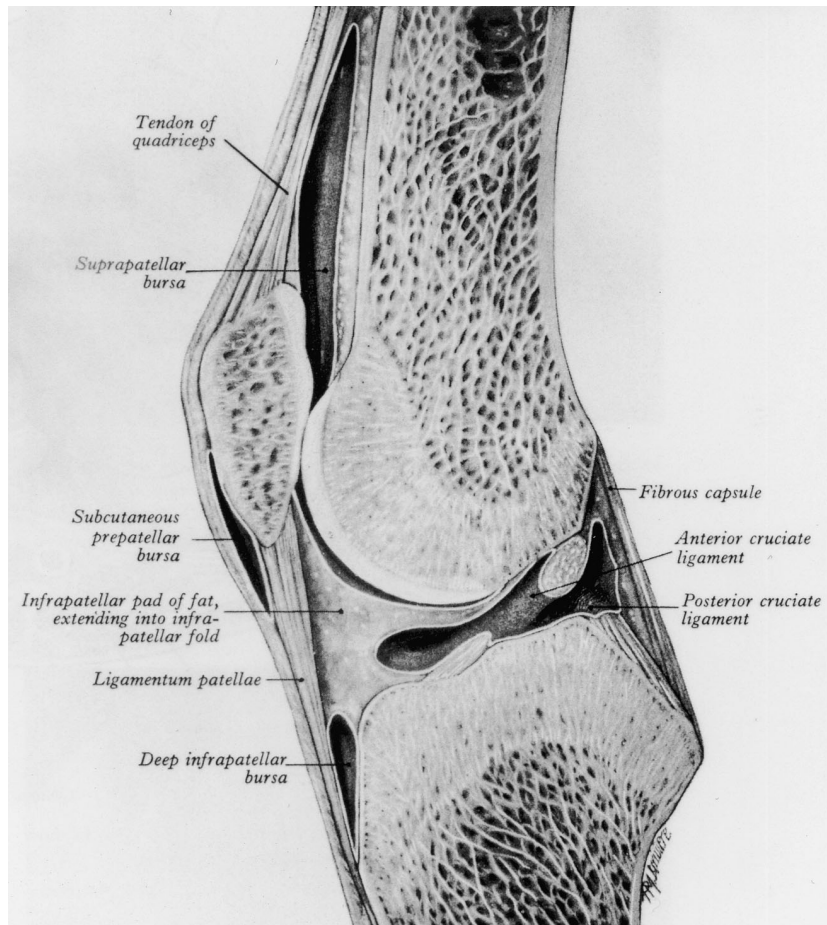


Fig. E-2

Illustration from *Gray's Anatomy*, showing a single (subcutaneous) prepatellar bursa.

From: Gray H. *Gray's anatomy*. 35th ed. Warwick R, Williams PL, editors. Philadelphia: WB Saunders; 1973. Permission was granted to use this figure.

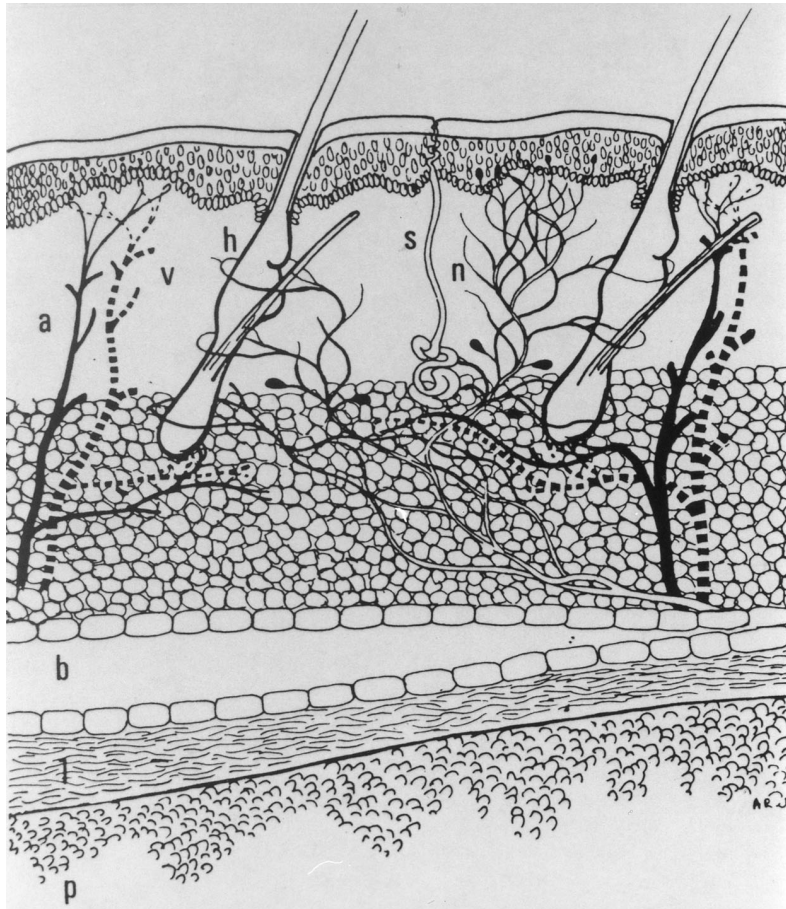


Fig. E-3

Incorrect schematic representation of the prepatellar soft tissues, showing only one prepatellar bursa. Note the absence of any representation of fascial, aponeurotic, or tendinous structures anterior to the patella. (a = arteriole; v = vein; h = hair follicle; s = sweat gland; n = nerve; b = prepatellar bursa; l = loose areolar tissue; p = patellar bone.) From: Quayle JB, Robinson MP. An operation for chronic prepatellar bursitis. *J Bone Joint Surg Br.* 1976;58:504-6. Permission was granted to use this figure.

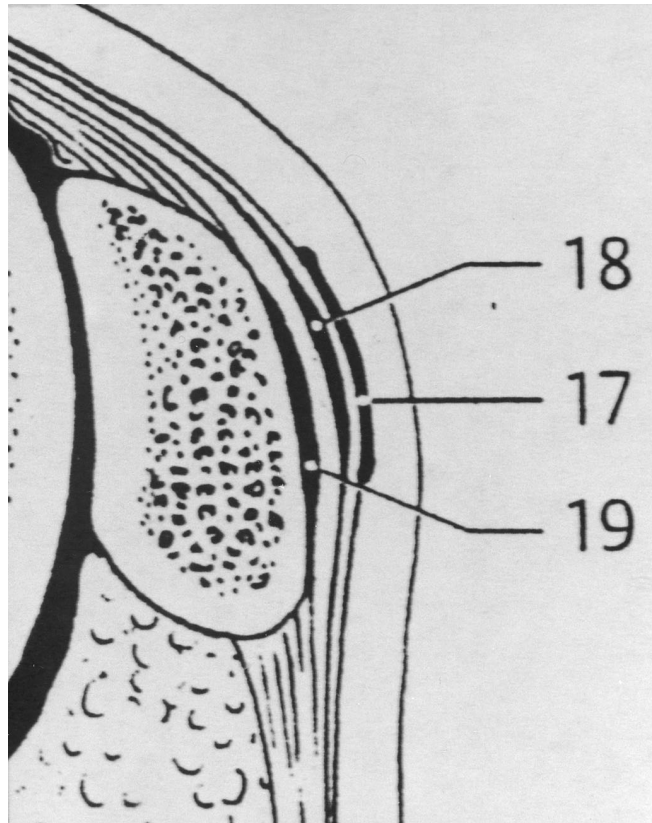


Fig. E-4

Incorrect schematic representation of the prepatellar soft tissues indicating the presence of a prepatellar subtendinous bursa (19). No such bursa was found in any of the sixty-one knees dissected in the present study. 17 = prepatellar subcutaneous bursa; 18 = prepatellar subfascial bursa. From: Feneis H, Dauber W. Anatomisches Bildwörterbuch der internationalen Nomenklatur. New York: G Thieme; 2000. Permission was granted to use this figure.