

# AP RADIOLUCENT ZONES

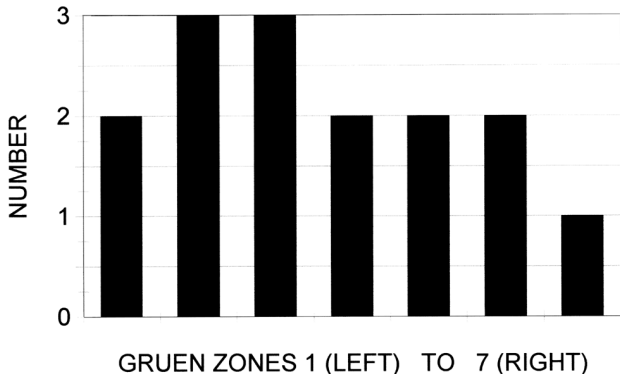


Fig. E-1

Graph of the radiolucent lines, according to the zones of Gruen et al., on the follow-up anteroposterior (AP) radiographs.

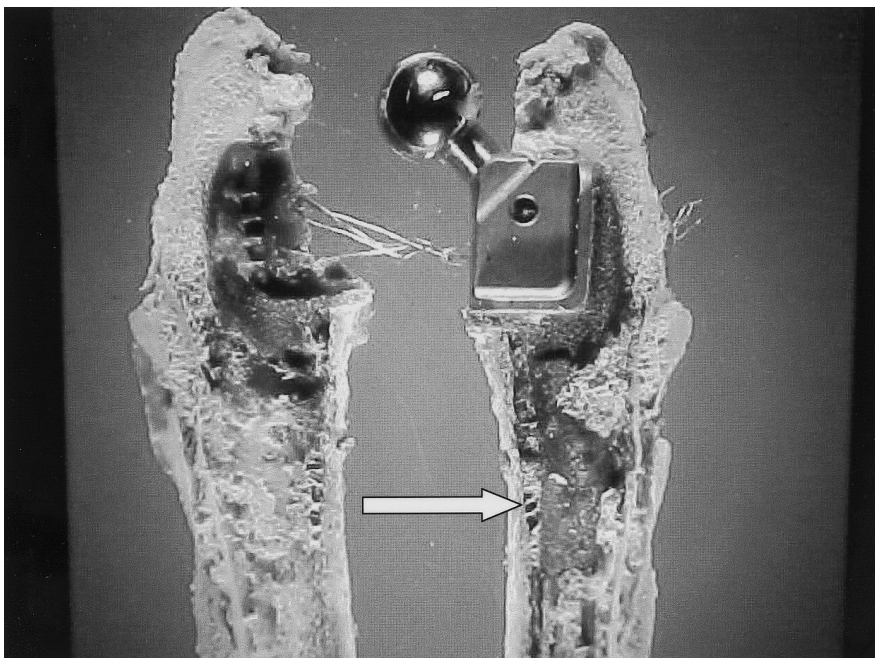


Fig. E2-A

A calcar-replacement implant retrieved four years postoperatively. The arrow indicates a bone bridge from the cortex to the implant, which corresponds to the trabecular bridging seen on the radiographs in Figures 3-A and 3-B.

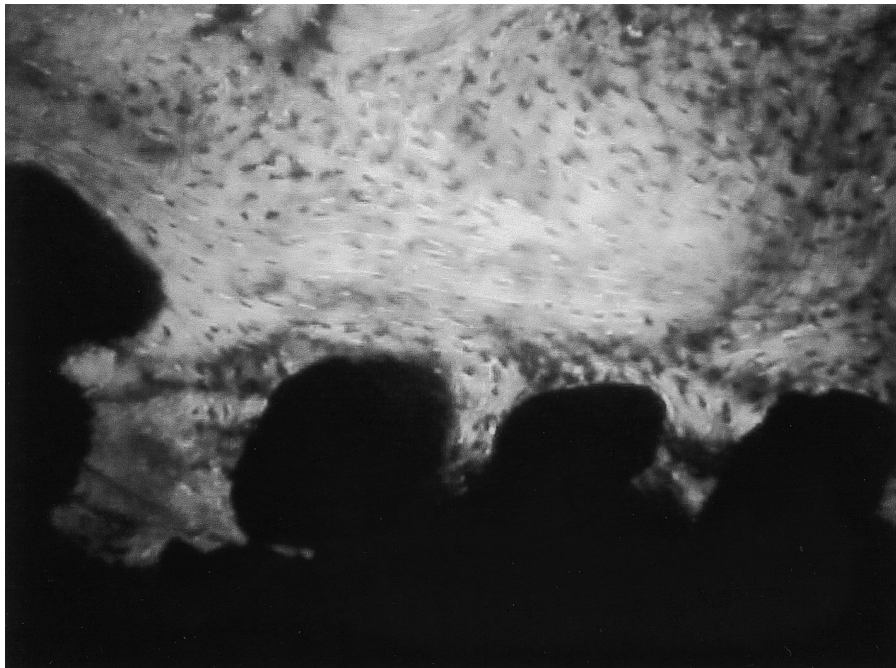

Fig. E2-B

Micrograph of the bone ingrowth, showing cortical bone extending into the porous surface.