

Triple Osteotomy of the Innominate Bone

BY HOWARD H. STEEL, M.D.*, PHILADELPHIA, PENNSYLVANIA

From the Shriners Hospital for Crippled Children, Philadelphia

ABSTRACT: In forty-five patients, twenty-three with congenital dislocations and the rest with paralytic or other disturbances, this new displacement osteotomy of the hip joint was done when other iliac osteotomies were considered ineffective. The patients seven to seventeen years old were followed two to ten years. Of the fifty-two procedures, forty were satisfactory. Most of the unsatisfactory results were in cases of myelodysplasia, peroneal atrophy, and cerebral palsy.

The procedure which is being described in this paper—triple osteotomy of the innominate bone—is mechanically equivalent to a displacement arthroplasty at the hip accomplished by circumacetabular osteotomy.

Its goal is to establish a stable hip at the anatomical level of the acetabulum in situations where the hip either is dislocated or subluxated. A prerequisite of the operation is that articular surfaces of the joint will be congruous or will become so, so that a functional pain-free range of motion will be achieved without a Trendelenburg gait, provided, of course, that the neuromuscular deficit is not prohibitive.

The indication for the procedure is an affection of the hip joint in a child that has resulted in a faulty femoral head-acetabular relationship and where restoration of stability to the hip is not possible by any one of the displacement osteotomies (Salter's, Pemberton's or Chiari's) or by the arthroplasty of Colonna.

Materials and Method

A consecutive series of fifty-two procedures done on forty-five patients constitutes the case material of this report. All patients were followed for a minimum of two years. The longest follow-up was ten years. The oldest patient operated on was seventeen years of age and the youngest was seven years of age.

The etiology of the dislocations or subluxations was congenital dislocation of the hip in twenty-three hips, cerebral palsy in seven hips, poliomyelitic residua in eight hips, spina bifida in seven hips, progressive peroneal muscular atrophy in six hips, and unreduced traumatic dislocation of the hip in one patient.

Many of the operations were performed on patients who had had previous surgery and this made postoperative evaluation and analysis difficult. Results, therefore, were categorized as satisfactory if the patient's hip was painless and stable and reasonably mobile, or unsatisfactory if the hip did not become stable or if the patient's condition worsened either because of loss of function or pain. One preoperative finding common to all patients was an unstable, lurching gait (Trendelenburg). A common finding was loss of flexion to such an extent that sitting was uncomfortable. Easy fatigability and pain were recorded as the most frequent preoperative complaints. The most common postoperative finding in a result considered unsatisfactory was persistence or aggravation of the unstable lurching gait.

Operative Procedure

Prior to triple osteotomy, continuous skeletal traction with effective counter-

* Shriners Hospitals for Crippled Children, Philadelphia Unit, 8400 Roosevelt Boulevard, Philadelphia, Pennsylvania 19152.

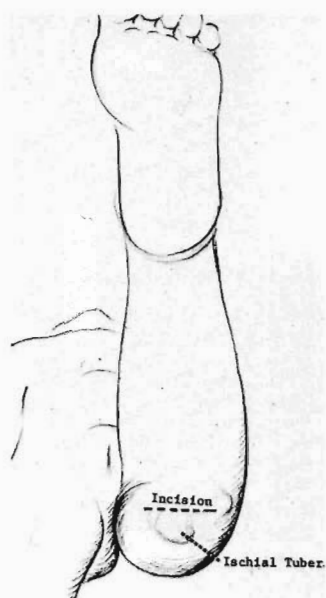


FIG. 1

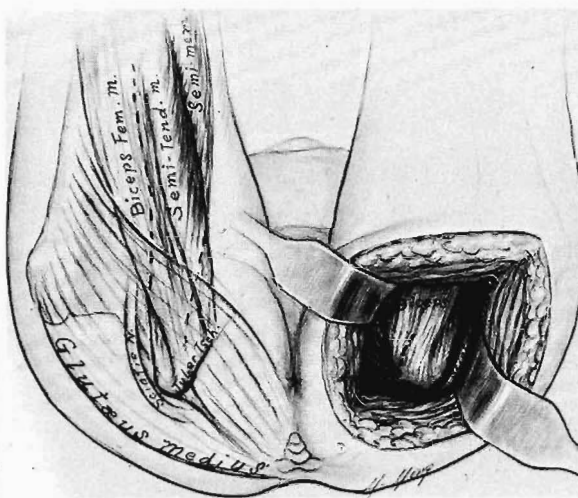


FIG. 2

Fig. 1: Patient supine on fracture table for ischial phase. Hip head flexed 90 degrees neutral abduction, adduction, and rotation. The knee is held at 90 degrees. The incision is parallel to and one centimeter cephalad to the subnatal crease.

Fig. 2: Approach to the ischial ramus. Gluteus maximus reflected to expose ischial tuberosity. Note conjoined tendon of biceps femoris and semitendinosus. Sciatic nerve lateral to tendinous origin of semimembranosus. (Reprinted from *Pediatric Orthopedics* by Mihran O. Tachdjian by permission of W. B. Saunders Company.)

traction must be applied until the femoral head is brought down to the level of the acetabulum. If a surgical release of the muscles about the hip is necessary to accomplish this, it must be done.

The patient is positioned supine for the operation with the hip flexed at 90 degrees in neutral, abduction-adduction, and rotation, and with the knee flexed to 90 degrees (Fig. 1). The incision to approach the ischium is horizontal, one centimeter proximal to the gluteal crease and perpendicular to the axis of the femoral shaft. The gluteus maximus (Fig. 2) is retracted laterally and the hamstrings are exposed at their origin on the ischial tuberosity. The most superficial is the biceps femoris which is sharply dissected from the ischium exposing the interval between the origins of the semimembranosus and the semitendinosus. Generally, the sciatic nerve is situated far enough laterally so as not to be jeopardized by the exposure, but stimulation of the nerve may be necessary to identify it prior to careful retraction.

A curved hemostatic forceps is passed into the interval between the origins of the semimembranosus and semitendinosus and behind the ischium into the obturator foramen. The origins of the obturator internus and externus are elevated and the tip of the instrument is brought out at the inferior margin of the ischial ramus. Every effort should be made to maintain the forceps in contact with bone during its passage behind the ischial ramus since the internal pudendal artery, vein, and nerve (which serve the external genitalia and thus are structures of some substance) course in the obturator fascia close by and parallel to the ischial ramus in Alcock's canal. They thus may be structures at risk.

An osteotome the same width as the ramus is driven across the ischial ramus directed laterally and posteriorly 45 degrees from the perpendicular, completely dividing the bone (Fig. 3). The origin of the biceps is allowed to fall back in place and the gluteus maximus is then sutured to the deep fascial envelope and closure is completed. Gloves and gowns are changed and a duplicate set of instruments is utilized for the second stage of the procedure, the ilipubic osteotomy.

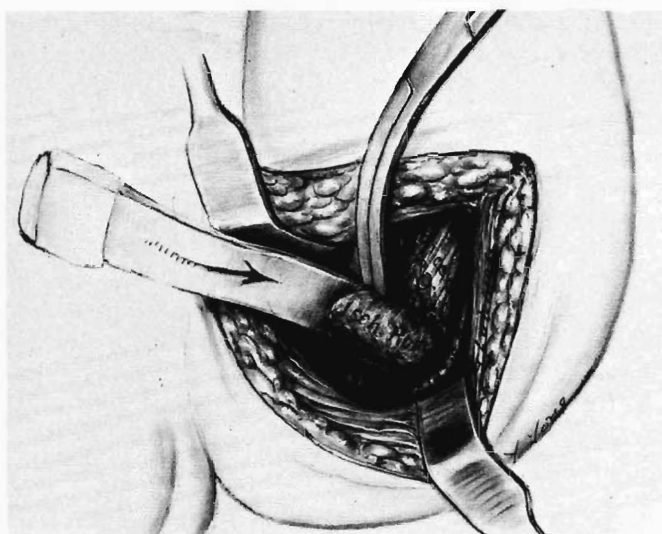


FIG. 3

Left biceps origin reflected off ischial ramus. Hemostatic forceps passed between attachments of semimembranosus and semitendinosus and around ischial ramus. Ramus divided by osteotome directed posterolaterally. (Reprinted from *Pediatric Orthopedics* by Mihran O. Tachdjian by permission of W. B. Saunders Company.)

Through an anterior iliofemoral approach, the iliacus and gluteal muscles are reflected from the wing of the ilium. The origin of the sartorius muscle and the lateral attachments of the inguinal ligament are detached from the anterior superior iliac spine and reflected medially (Fig. 4). The iliacus and psoas are reflected subperioste-

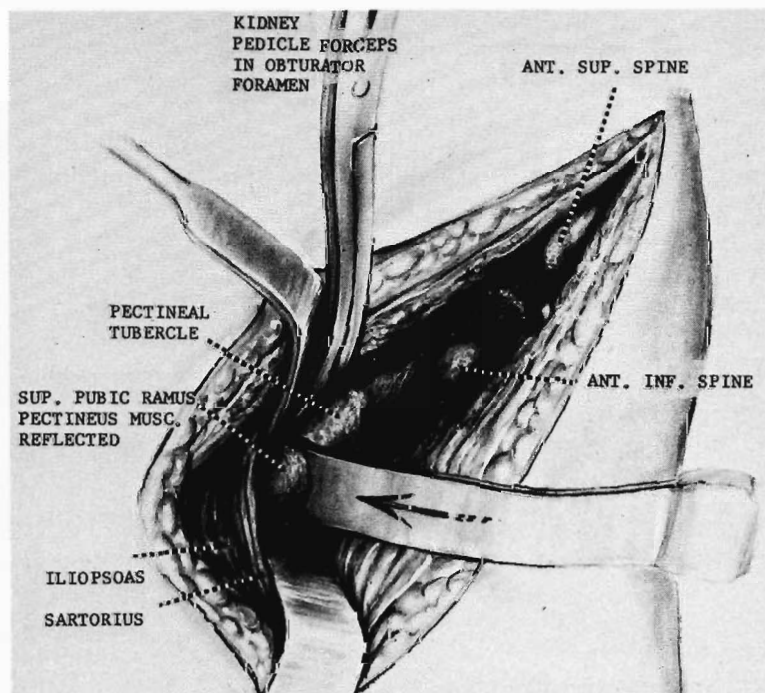


FIG. 4

Diagram of pubic osteotomy. (Reprinted from *Pediatric Orthopedics* by Mihran O. Tachdjian by permission of W. B. Saunders Company.)

teally off the pelvis, affording adequate protection for the femoral nerve, artery, and vein which lie anterior to them. The tendinous part of the origin of the iliopsoas is divided to facilitate exposure of the pectineal tubercle.

The pectineal muscle is detached subperiosteally from the pubic ramus. When the pubic ramus has been adequately exposed—usually about one centimeter medial to the pectineal tubercle—a curved hemostatic forceps is passed superior to the pubic ramus and into the obturator foramen, close to the bone. It is carried through the obturator fascia and its tip is brought out inferior to the ramus. If the bone is too thick to permit this, a second forceps is passed inferior to the pubic ramus cephalad to contact the superior one. An osteotomy is then done directing the instrument posteriorly and medially, 15 degrees from the perpendicular. The obturator artery, vein, and nerve are situated medial to this cut and are protected by the forceps.

The iliac osteotomy is accomplished with a Gigli saw by the technique of Salter (Fig. 5) introduced posteriorly and subperiosteally at the greater sciatic notch and carried through anteriorly to a mid-point between the anterior superior spine and the anterior inferior spine. The periosteum and fascia of the medial pelvic wall are cut to further free the acetabular segment.

At this point, if the femoral head was subluxated or dislocated laterally, the capsule must be opened and the tissue obstructing the reduction removed. The integrity of the articular surface is maintained and no dissection of cartilage and bone should be done in order to avoid excessive scarring and necrosis. Reduction of the femoral head should be as near as possible to the center of the triradiate cartilage epiphysis, that is the middle of the old acetabulum. Once reduction is complete, the capsule of the joint is closed.

With a towel clip gripping the anterior inferior iliac spine, the mobile acetabular segment can be rotated in almost any direction and is rotated anteriorly and laterally until it adequately covers the head (Fig. 6). The displacement can be facilitated by a

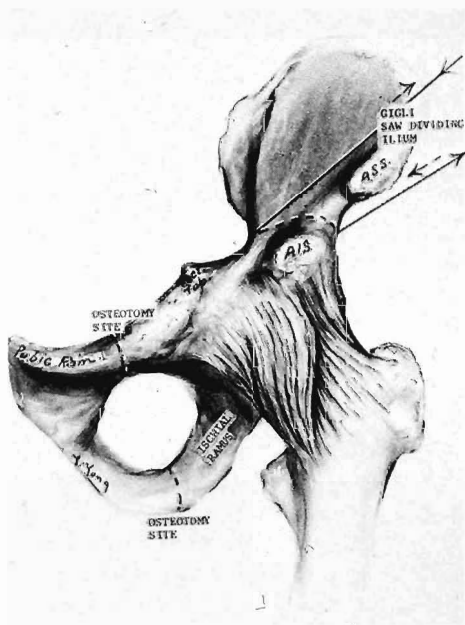


FIG. 5



FIG. 6

Fig. 5: Iliac osteotomy and sites of pubic and ischial osteotomies. (Reprinted from *Pediatric Orthopedics* by Mihran O. Tachdjian by permission of W. B. Saunders Company.)

Fig. 6: Acetabular segment rotated laterally and anteriorly and stabilized with bone block and pins.

spreader in the iliac osteotomy site. This instrument can be used quite effectively without displacing the proximal iliac fragment, particularly in the older child, because there is sufficient stability at the sacro-iliac joint so that force is transmitted only to the completely mobile acetabular segment.

The acetabular fragment is stabilized with a bone graft removed from the superior wing of the ilium (Fig. 6) and fixed with two extra-articular pins penetrating to the inner table of the ilium (Fig. 7). The rectus femoris is then reattached to the anterior inferior iliac spine and the pectineus and iliopsoas are allowed to fall back into place.

The sartorius and lateral end of the inguinal ligament are reattached to the anterior superior spine. The wound is closed in layers and the spica cast applied with the hip in 20 degrees abduction, 5 degrees flexion and neutral rotation.

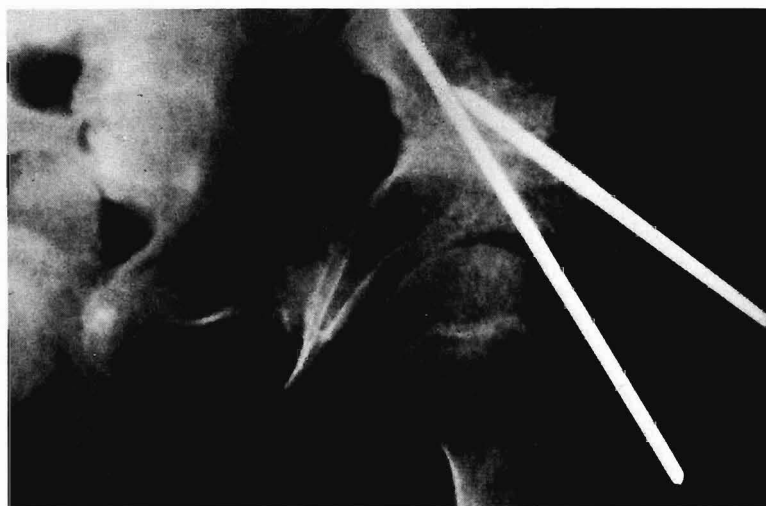

FIG. 7

Postoperative status of a triple osteotomy of the innominate bone with fixation pins in situ.

Complications

Our immediate postoperative complications included two patients with paralytic ileus, both relieved by the use of nasogastric suction and a rectal tube and by removal of the abdominal window in the cast. One infection occurred in this series. It was in the ischial wound and was evident in the third postoperative day. A pure culture of *Escherichia coli* was obtained. It responded to adequate drainage and did not compromise the patient's end result, which was satisfactory. Two patients had pressure necrosis of the skin occurring over the anterior inferior spine of the displaced acetabular segment as complications. They responded to the release of pressure from the overlying cast and healed by third intention without affecting the end results. The dead space between the gluteus maximus and the ilium created by the lateral displacement of the acetabulum undoubtedly was filled with a hematoma, but in no instance was drainage necessary. Union was prompt and complete within twelve weeks in all the osteotomy sites in all patients in this series. The cast was ordinarily maintained for a period of eight to ten weeks, at which time the pins were removed and passive and active motion was started, emphasizing restoration of gluteus medius function. Weight-bearing was begun with crutches at twelve to fourteen weeks and all patients in the series (where neuromuscular complications of the patient's disease did not contravene) were walking independently at the end of six months.

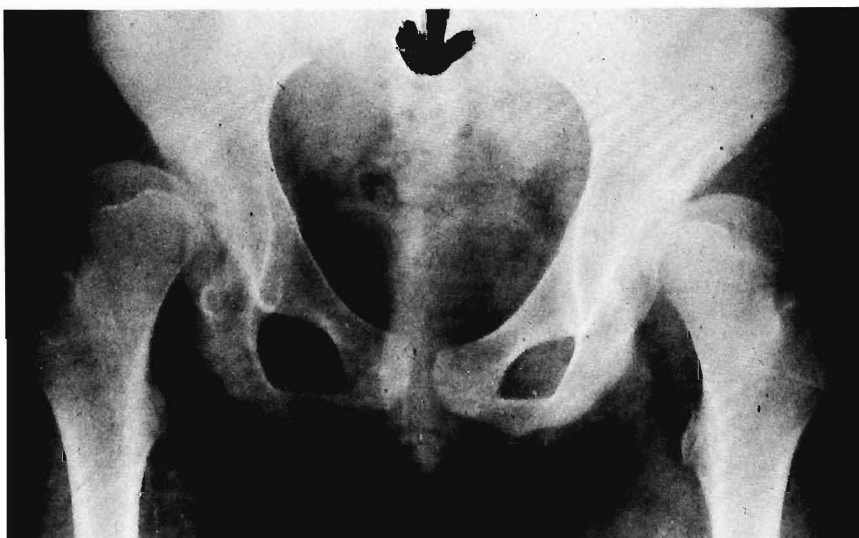


FIG. 8-A

Bilateral congenitally subluxated hips.

Results

In the total of fifty-two operations performed, forty results were satisfactory and twelve unsatisfactory. There were six patients with myelodysplasia in whom seven hips had been operated on. The result in the patient who had the procedure done bilaterally was a failure because of loss of motion in the flexion plane, making sitting difficult. The results in both hips in this patient are listed as unsatisfactory. The other failure resulted from inadequate preoperative traction where the head was not brought down enough before the osteotomy. This led to severe pressure on the femoral head, causing a formation of a Charcot joint with progressive loss of motion. Thus, three hips out of seven in the myelodysplasia group had unsatisfactory results.

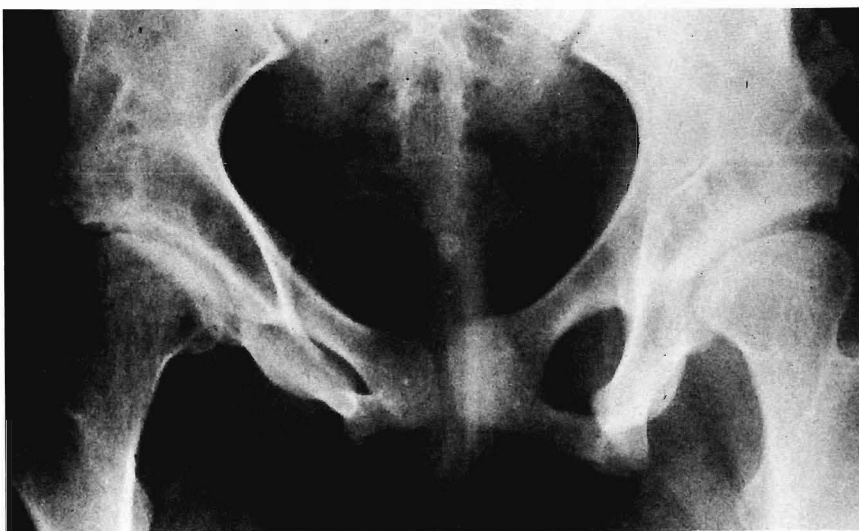

FIG. 8-B

Ten-year follow-up postoperative triple osteotomy of innominate bone for bilateral congenitally subluxated hips.

Four patients with peroneal muscular atrophy had a total of six hips operated on. Three results were in the satisfactory category. One of the two patients who had the procedure done bilaterally had a Trendelenburg gait eleven months postoperatively, despite having satisfactory pain-free motion and a functioning fulcrum, and the result was included in the unsatisfactory group. One failure also occurred in a patient with a unilateral procedure. The progression of their hip weakness as a result of their disease may have been a contributing factor.

Seven operations were done on patients with cerebral palsy. In two patients, unsatisfactory results were recorded because of pain. Both had failure of adequate reduction of the femoral head at the time of circumacetabular osteotomy. The bilateral procedure in this group was satisfactory.

There were eight patients in the series with a diagnosis of post-poliomyelitic weakness. Each had unilateral involvement. A satisfactory result was recorded in all these patients. All had a positive Trendelenburg gait prior to surgery because of their neuromuscular disease and the result in each was a pain-free hip with normal motion and a stable fulcrum. Four patients had a striking lessening of their Trendelenburg gait because of the more effective mechanical advantage of the gluteus medius after the osteotomy had been performed.

Twenty-three procedures were done on twenty patients with congenital dislocation of the hip and one on a patient with traumatic unreduced dislocation. The result of the latter was satisfactory. All twenty patients with congenital dislocation had a Trendelenburg gait preoperatively. This was of varying severity; four complained additionally of incapacitating loss of motion; five of limited endurance and easy fatigue; and five had complaints of pain with activity which ranged from tolerable and inconstant to intolerable and continuous. In the twenty-three congenitally dislocated hips, three patients first appeared with the problem bilaterally, and a bilateral triple osteotomy of the innominate bone spaced three months apart was done. These patients had satisfactory results. The remaining seventeen patients had only four unsatisfactory results; one patient had the same pain after the operation as preosteotomy, two patients had persistent Trendelenburg gait and easy fatigability, and one had the same incapacitating loss of motion as before the operation. The

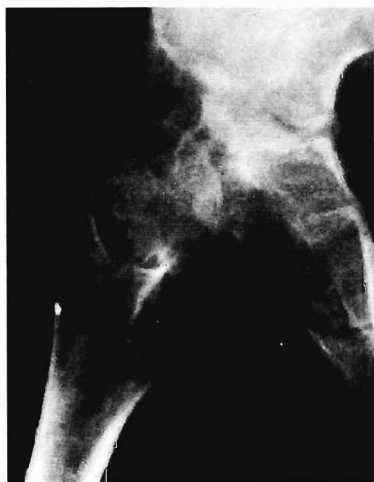

FIG. 9-A

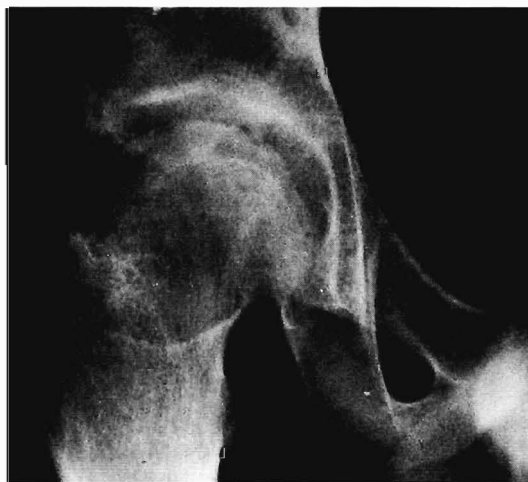

FIG. 9-B

Fig. 9-A: Ten-year-old white boy. Congenital dislocation of the right hip. Four years after attempted reduction and iliac osteotomy.

Fig. 9-B: Six-year follow-up open reduction and triple osteotomy of innominate bone. Motion limitation minimum at extremes of motion. No pain or limp. Head conformation not normal, but congruent with acetabulum.

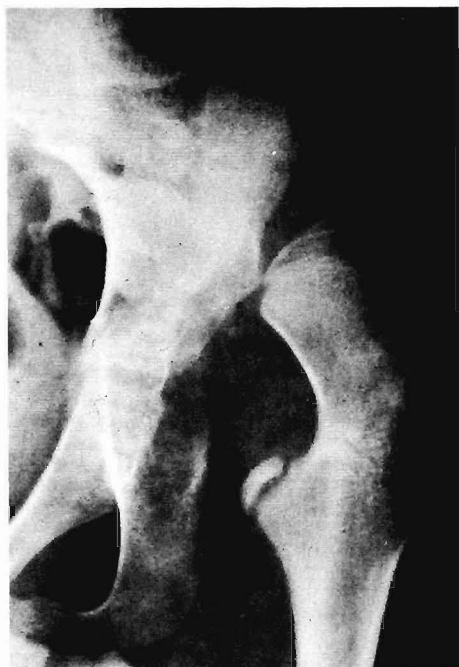

FIG. 10-A

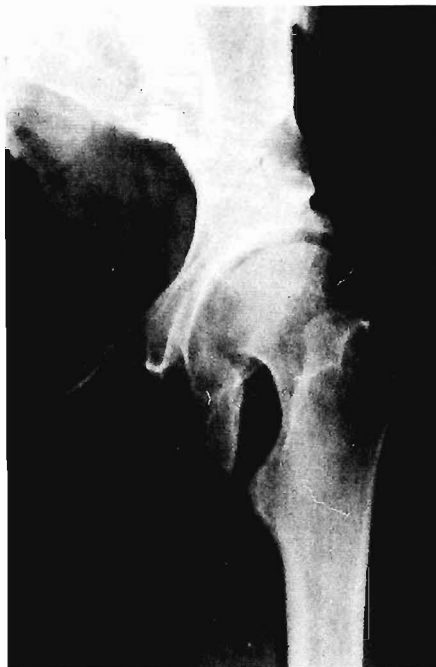

FIG. 10-B

Fig. 10-A: Twelve-year-old white boy. Untreated congenital dislocation of the left hip. Before operative triple osteotomy of innominate bone.

Fig. 10-B: Ten-year follow-up after open reduction of hip and triple osteotomy of innominate bone. Normal, pain-free motion with no limp. (Figs. 10-A and 10-B are reprinted from *Pediatric Orthopedics* by Mihran O. Tachdjian by permission of W. B. Saunders Company.)

probable reason for failure in the last three patients was inadequate coverage of the head during the maneuver of mobilization and placement of the acetabular segment. The longest follow-ups on these patients are illustrated in Figures 8 through 10.

Conclusion

The procedure of triple osteotomy of the innominate bone is a satisfactory method to achieve adequate coverage of the femoral head and restoration of a functioning acetabulum in children with subluxation or dislocation of the hip joint. It is indicated particularly in the older child and young adult in whom other osteotomies would not be adequate. It must be preceded by skeletal traction to restore the femoral head to the acetabular level. If the head can be reduced to this area without excessive pressure, the triple osteotomy of the innominate bone can afford adequate head coverage and result in a satisfactory head-acetabular relationship.

The series of forty-five patients with fifty-two procedures and a two to ten-year follow-up showed forty to be satisfactory and twelve unsatisfactory. The best results can be expected when there is no disease progression and when muscle strength is adequate. Cases of subluxation or dislocation were included with the following etiologies: congenital dislocation of the hip, myelodysplasia, cerebral palsy, and poliomyelitis.