

Transchondral Fractures (Osteochondritis Dissecans) of the Talus*

BY ALBERT L. BERNDT, M.D., M.SC.(MED.), PORTSMOUTH, OHIO, AND
MICHAEL HARTY, F.R.C.S., PHILADELPHIA, PENNSYLVANIA

From the Departments of Anatomy and Orthopaedics, the Graduate School of Medicine, University of Pennsylvania, the Department of Orthopaedic Surgery, The Cleveland Clinic Foundation, and the Frank E. Bunts Educational Institute, Cleveland, Ohio.

Alexander Monro⁵² has been credited, possibly erroneously †, with being the first to report the finding of loose osteocartilaginous bodies in the ankle joint. He attributed the condition to trauma but did not classify it as a fracture. Stevenson⁷³ used the same term in describing a case which he reported in 1925.

In 1888 König⁴³ observed loose bodies in joints other than the ankle. He referred to them as corpora mobile and speculated about their etiology. He decided that they could not have been caused by any known disease, tumor, or trauma, and concluded, without substantiating evidence, that they must have been produced by a process of spontaneous necrosis. For this hypothetical mechanism he coined the term *osteochondritis dissecans*.

The first use of the term *osteochondritis dissecans* as applied to the ankle joint was made by Kappis⁴¹ in 1922. After that time the names formerly used—loose bodies, joint mice, and corpora mobile—were used as secondary terms. Osteochondritis dissecans became the accepted name and has been used by the majority of authors since 1922.

In 1932 Rendu⁶⁰ reported a case of intra-articular fragmentary fracture of the talus. The lesion, as shown by his roentgenograms and as described in his operative note, was the same type that had been reported by Monro and Kappis. Rendu's term has since been used by a few authors.

Since 1932 two separate series of reports of osteocartilaginous lesions of the dome of the talus were published. In one report the lesions were called fractures, in the other they were labeled osteochondritis dissecans. When the case histories and roentgenograms in these reports were studied carefully, it became evident that the authors of the two sets of reports were describing the same condition. In fact, in twenty-eight of the cases reported the authors used the two terms interchangeably.

Because the condition rarely occurs and has been reported under many diagnostic terms, misconceptions and misunderstandings of the lesion have developed. These erroneous ideas have obscured the characteristics of the condition that are significant to the patient, the attending surgeon, and the organizations involved in compensatory payments.

This report is intended to draw attention to the points of misunderstanding and to clarify them in the light of the information gained from a thorough study.

PRESENT SERIES

The following case histories are included for two reasons: to emphasize certain characteristics of the condition, and to illustrate the present-day differences of opinion among surgeons concerning the nomenclature, etiology, and treatment of the lesions.

* Abridgment of the thesis submitted to the Faculty of the Graduate School of Medicine of the University of Pennsylvania in partial fulfillment of the requirements for the degree of Master of Medical Science for graduate work in Orthopaedic Surgery.

† Monro's original report was not available to us. That report was cited by Barth⁶, who said that Monro's lesion was located in the knee, and by Phemister⁵⁶, who said it was in the ankle.

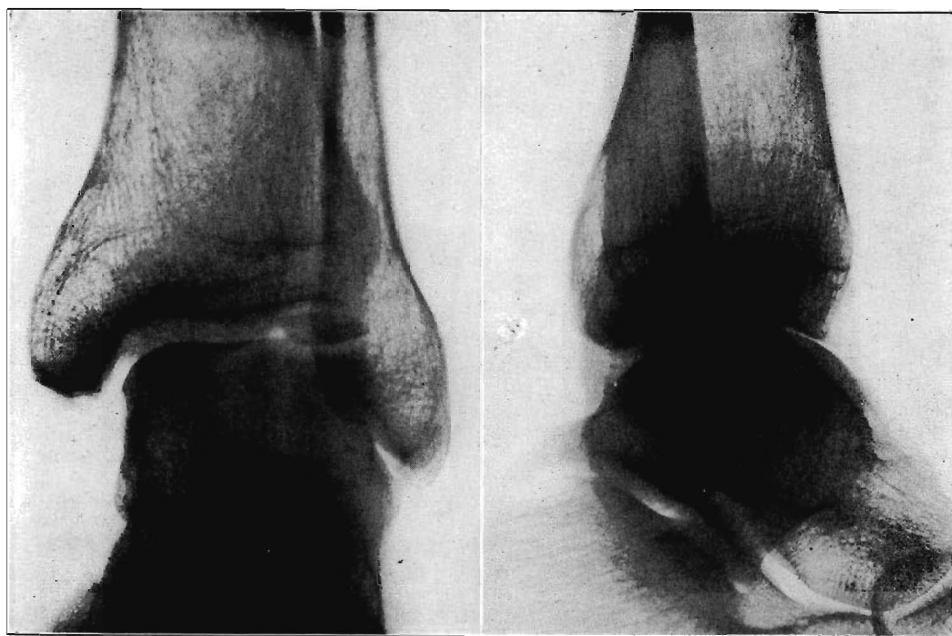


Fig. 1

Case 1. Roentgenograms of the ankle five hours after injury showing avulsion fracture from the lateral border of the talar dome with detached chip lying upside down in its bed.

CASE 1. R.E.B., a male railroad worker, thirty years old, had no history of ankle disability until June 7, 1949, when, descending from a locomotive, he stepped down with his left foot on an air hose and turned his ankle. There was a snapping sound in the ankle, accompanied by pain anterior to the lateral malleolus. He was able to walk, but with a limp, and reported that he had sprained his ankle. The ankle showed the characteristics of an inversion sprain: tenderness about the malleolus, increased pain on passive inversion, soft-tissue swelling, ecchymosis, and limitation of motion. Roentgenographic examination on the same day showed a chip fracture of the lateral border of the dome of the talus, the chip lying upside down in the bed from which it had been detached. The other bone components of the ankle joint appeared to be normal (Fig. 1).

An anterolateral incision was made at operation on June 9, 1949. The anterior and middle fasciculi of the lateral collateral ligament were found to be completely disrupted; but the posterior fasciculus was intact, as were the deltoid and interosseous ligaments. The joint was distended with partly clotted blood. Plantar flexion of the foot brought the anterior portion of the fracture into view beneath the anterior lip of the tibia. The inverted loose fragment was extracted; it was a single, intact piece, eighteen by thirteen by five millimeters. One surface was covered with normal articular cartilage; the opposite surface was fresh trabecular bone. The crater from which the fragment had been removed also showed a surface of raw, bleeding bone. The lesion was clearly a new fracture. Since the fragment constituted about one-third of the articular surface of the talar dome, it was deemed advisable to replace it rather than discard it. (The chip could be removed later if lack of blood supply should prevent union.) The chip was inserted in its proper position and impacted, as well as the limited access permitted, into the main fragment of the talus. A toe-to-groin cast was then applied.

Roentgenograms made three weeks later (Fig. 2-A) showed no change from the immediate postoperative films. The cast was replaced by a posterior metal splint for an additional five weeks at which time graduated weight-bearing was begun.

Roentgenograms made at fourteen and twenty weeks with the ankle in plantar flexion showed what appeared to be progressive healing of the fracture with obliteration of the fracture line (Figs. 2-B and 2-C). Clinical improvement was also noted.

During the ninth month, however, with no further injury, there was an increase in pain on walking. Roentgenograms were made with the ankle in dorsiflexion and in plantar flexion. In the plantar-flexion view, the fracture line appeared to be healed, but in dorsiflexion, the fracture line was clearly seen. Its appearance (Fig. 2-D) was almost identical with that seen on the roentgenogram made immediately after reduction. Lateral views showed the fracture line to be visible, but indistinct. Operative removal of the fragment was suggested, but declined by the patient.

Five years after operation the patient returned for examination. He had had no further treatment for the ankle. He was operating a small farm as well as working full time as a

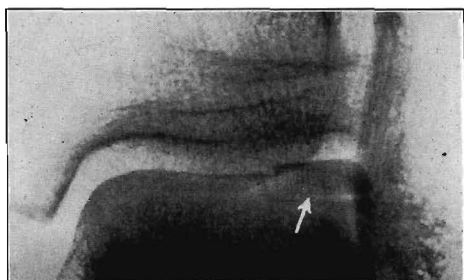


FIG. 2-A

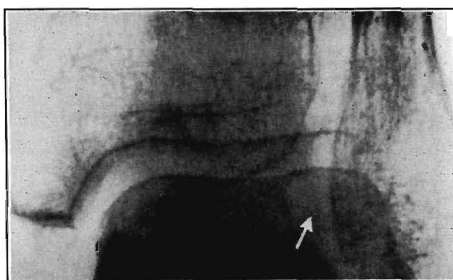


FIG. 2-B

Figs. 2-A through 2-D: Case 1. Follow-up roentgenograms made with the ankle in plantar flexion at fourteen weeks and twenty weeks gave a false impression of progressing bone union because the chip was viewed through the intervening intact dome. At nine months in the projection made with the ankle in dorsiflexion the fracture line was still visible. For correct interpretation of healing, the chip must be shown in profile on top of the dome.

Fig. 2-A: Three weeks after operation.

Fig. 2-B: Fourteen weeks after operation.

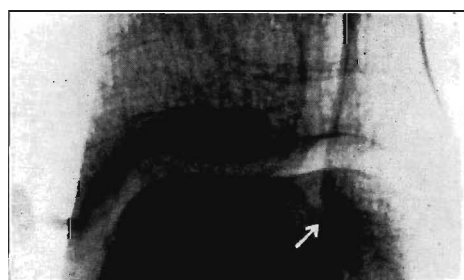


FIG. 2-C

Twenty weeks after operation.

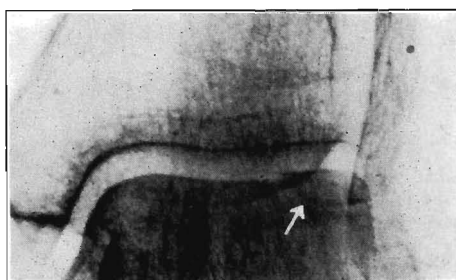


FIG. 2-D

Nine months after operation.

laborer, carrying logs and brush on hillsides. Notwithstanding those trying conditions, the ankle performed normally. The fracture line was still visible on roentgenograms made March 1, 1954, five years after operation.

The good clinical result, together with the roentgenographic evidence of failure of bone union, was interpreted as showing that the patient had attained solid fibrous union which provided a useful, painless ankle. It was apparent that the eight weeks of immobilization had been inadequate for the formation of bone union.

CASE 3. J.R.R., a seventeen-year-old boy, had had no pain in his right ankle until November 19, 1954, when he injured it in a basketball game. The symptoms and signs were those of an inversion sprain. Roentgenograms showed a small chip fracture of the middle third of the lateral margin of the talar dome (Fig. 3-B). Immobilization in a walking cast for three weeks brought no improvement. A partially detached chip fracture of the dome was found at operation on December 13, 1954. The fragment, larger than the roentgenogram had indicated, was removed, and the resulting crater curetted. Immobilization in a cast was continued for five weeks. At the end of the sixth week the ankle was considered clinically normal. Nine months after operation the patient was free of symptoms.

CASE 6. E.J.S. was thirty-five years old and a tooler in an automobile-manufacturing plant. He had had no complaint of pain in his ankles until October 2, 1953, when he fell eighteen feet, from a ladder to the floor, injuring his back, pelvis, and ankles. He was taken to a hospital where he was found to have a fracture of the pelvis, a compression fracture of the second lumbar vertebra, and sprains of both ankles. With treatment at that hospital he recovered from the fractures of the spine and pelvis, except for occasional, residual aching in the lumbar region. He was not told of any ankle fracture and received no treatment for the sprains other than the bed rest necessitated by the fractures of the spine and pelvis. He returned to his work after discharge from the hospital.

One year after his accident he was seen at The Cleveland Clinic because of swelling and aching in the right ankle; both symptoms being relieved by rest, but aggravated by active motion. The left ankle remained free of pain unless used excessively to spare the right ankle. Examination showed the left ankle to be normal, but the right to be somewhat swollen, with

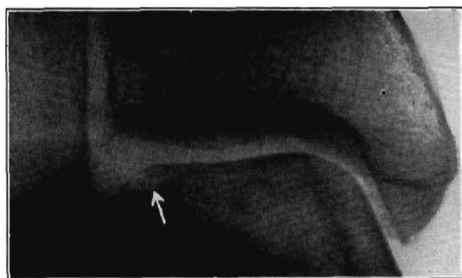


FIG. 3-A

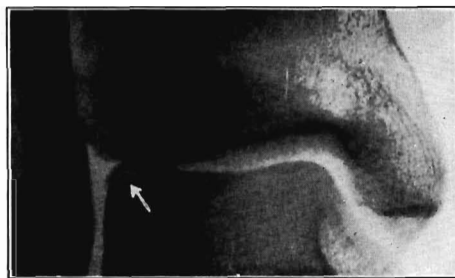

FIG. 3-B

Figs. 3-A through 3-H: Roentgenograms showing the four stages of transcondylar fractures of the talar dome—those of the lateral margin in 3-A, 3-C, 3-E, and 3-G in the left column and those of the medial margin in 3-B, 3-D, 3-F, and 3-H in the right column. In Figure 3-H the displaced chip is not seen clearly, but the lateral view of the same fracture (Fig. 15-B) shows it to occupy the anterior compartment of the ankle.

Fig. 3-A: Case 2. Lateral fracture, Stage One.

Fig. 3-B: Case 3. Lateral fracture, Stage Two.

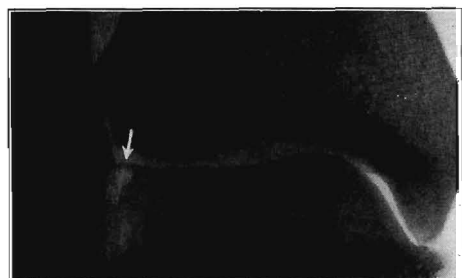

FIG. 3-C

Case 4. Lateral fracture, Stage Three.

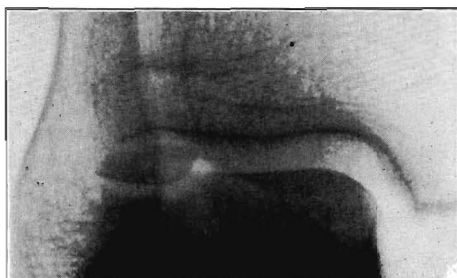

FIG. 3-D

Case 1. Lateral fracture, Stage Four.

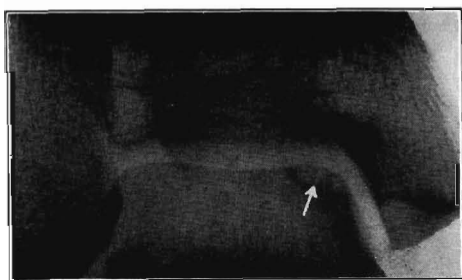


FIG. 3-E

Case 11. Medial fracture, Stage One.

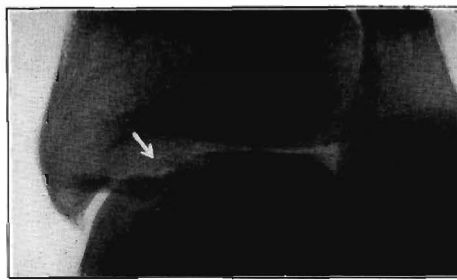


FIG. 3-F

Case 13. Medial fracture, Stage Two.

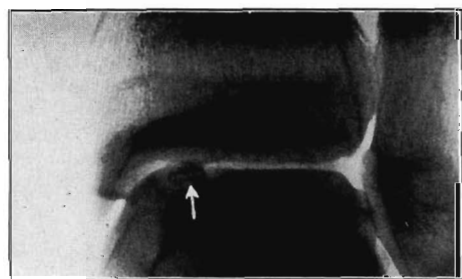


FIG. 3-G

Case 17. Medial fracture, Stage Three.

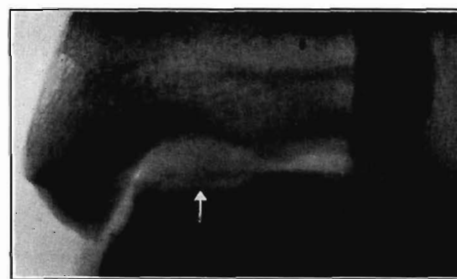


FIG. 3-H

Case 7. Medial fracture, Stage Four.

tenderness anterior to the lateral malleolus. The ankle dorsiflexed to 90 degrees and plantar flexed to 115 degrees. Roentgenograms made October 15, 1954, showed a normal left ankle.

There was an area of cortical elevation on the lateral margin of the right talus. In the roentgenographic report the possibility of osteochondritis dissecans was suggested and a small, loose body was noted in the medial margin of the ankle opposite the medial malleolus as well as an osteophytic spur that protruded from the anterior lip of the tibia (Figs. 14-C and 14-D).

Four months of conservative treatment with physical therapy gave no relief; operation was performed on February 22, 1955. A transverse osteotomy of the lateral malleolus gave wide exposure of the ankle joint. The osteocartilaginous fragment, measuring 2.5 by 1.3 by 1.3 centimeters, was detached from the crater in the middle third of the lateral margin of the talus. Two small, loose bodies were found—one lying between the talus and medial malleolus, and the other attached to the anterior inferior lip of the tibia. All three fragments were removed. The crater of the large fragment was curetted down to trabecular bone. The osteotomy was secured by a screw, and a toe-to-groin cast was applied. The pathological report read: "Necrosis of bone adjacent to cartilaginous cap. No evidence of healing at present".

Immobilization was continued for ten weeks. The patient returned to light work in August 1955, and to his regular work the following month. Six months after operation he had only occasional slight aching in the affected ankle and was not restricting its use.

CASE 7. M.D.F., an eighteen-year-old laborer, had had no complaint concerning his left ankle until November 9, 1950, when, in jumping over a conveyor system, he caught his left heel and fell, striking the lateral aspect of the left ankle against a steel support. Roentgenograms showed a large defect in the middle third of the medial border of the talar dome and a large, loose body, eighteen by seven millimeters, occupying the anterior portion of the ankle joint (Figs. 3-H and 15-B). At operation, on November 28, 1950, the loose fragment was removed; it had healthy cartilage on one surface and raw trabecular bone on the other.

Seven months after operation the patient passed the physical examination for the United States Air Force, but for the next three years he continued to have some aching in the ankle on prolonged marching. Roentgenograms made two years after operation showed some filling in of the osseous defect of the talus and a small flake distal to the tip of the medial malleolus.

CASE 11. M.C., a housewife, sixty-two years old, had had no disability in the right ankle until March 16, 1953, when she fell in a ditch, injuring the right foot and ankle. Roentgenograms showed a fracture of the calcaneus which was treated by immobilization and which healed without incident. No injury to the talus was noted. Fourteen months later, on May 3, 1954, the patient complained of pain in the right ankle. The pain was aggravated by walking but relieved by resting. Swelling and tenderness were present about the medial malleolus. The original roentgenograms were re-examined and were found to show a small lesion of the medial border of the talus (Fig. 3-E). Additional roentgenograms, including planigrams, showed the lesion still present, apparently increased in size. A diagnosis of osteochondritis dissecans was made. On June 2, 1954, arthrotomy of the right ankle showed a soft spot in the cartilage of the mid-portion of the medial border of the talar dome. The cartilage was intact. The soft spot was not incised or removed. A coincidental finding of stenosis of the sheaths of the peroneal tendons was treated by tenovagotomy.

During the year following arthrotomy the patient continued to complain of the same symptoms that she had had prior to operation. Roentgenograms made on May 2, 1955, showed the lesion to be still present, and the roentgenographic diagnosis at this time was compression fracture.

The point of interest in this case was the healing of the calcaneal fracture although the talar fracture remained unchanged.

CASE 13. P.P.M., a housewife, forty-seven years old, was treated for a ganglion of the peroneal tendon sheath of the right ankle. The ganglion was ruptured by digital pressure and did not recur. Routine roentgenograms made February 4, 1954, at the first visit, showed a fairly large area of osteochondritis dissecans of the medial margin of the talar dome (Fig. 3-F). The patient at first denied any injury to, or complaint of pain in, the ankle and declined treatment for the bone lesion. However, on October 13, 1955, when questioned again, she recalled that she had had instability of the ankle for years, that the ankle turned in while walking, and that she had occasionally experienced sharp, lightning pains in the ankle. She attributed these pains to arthritis and did not consider either the pains or the roentgenographic evidence to be serious enough to justify operation. Follow-up roentgenograms made September 30, 1955, showed the lesion unchanged in appearance.

CASE 17. L.B., a beauty-parlor operator, thirty-four years old, complained of pain in the right ankle for six months, beginning in June 1951. She said that she had sprained the ankle severely in 1946 but had had no medical attention at that time. During the five-year interim the ankle was free of pain. In June 1951, with no further injury, she began to experience a sensation of "the bones in the right ankle seeming to slide over each other", and the foot inverted frequently, becoming progressively more painful until she could wear only low-heeled shoes. The foot was held in pronation, and the local skin showed numerous callosities. When the foot was forced in plantar flexion there was a suggestion of a palpable defect on

the medial margin of the superior surface of the talus. Roentgenograms made on January 2, 1952, showed a partly detached fragment on the medial aspect of the superior articulating surface of the talus, apparently under the posterior rim of the medial malleolus (Fig. 3-G). Operative removal of the chip was recommended, but the patient declined the suggestion.

The symptoms subsided during the following three months. Follow-up roentgenograms made on May 13, 1952, eleven months after the onset of symptoms, showed: "marked improvement in the appearance of the osteochondritic lesion with apparent loss of definition of the loose body and with resolution in the area of increased density."

On December 8, 1952, fourteen months after the onset of symptoms, the patient again complained of crepitus in the ankle. Roentgenograms made on December 15, 1952, were reported as showing no change from those of the previous May.

On March 2, 1954, thirty-three months after the onset of symptoms and twenty-seven months after the first roentgenograms, re-examination showed the lesion to have the same appearance as in the first examination. The state of healing was not found to be as reported at the interim examinations.

Until May 1954, the patient continued to have intermittent and variable discomfort in the ankle, but was able to continue working.

In this patient the time from original injury to follow-up was eight years; symptoms were present for thirty-five months; and there was roentgenographic proof of the existence of the lesion for twenty-seven months.

CASE 18. On September 12, 1949, H.R., a tabulator-machine operator, thirty-three years old, complained of pain of two months' duration in the left ankle. She denied injury and said that the pain had been gradual in onset and aggravated by walking. Adhesive strapping had given partial relief. Both feet were pronated; there was tenderness over the anterior aspect of the left ankle and slight swelling of the lower third of the leg and the ankle. Range of motion was from 90 to 130 degrees. Roentgenograms were reported as showing osteochondritis dissecans of the medial border of the left talar dome. Conservative treatment by leg cast for six weeks brought no improvement.

Two months after the first visit the patient began to complain of occasional "catching" pain in both ankles. Roentgenograms made on November 18, 1949, showed osteochondritis dissecans of the superior surfaces of both tali (Fig. 15-C). Bilateral intermittent pain continued. By March 6, 1950, the pain in the left ankle had become intolerable. Arthrotomy, March 8, 1950, showed a loose body, one centimeter in diameter, in the posterior portion of the left ankle joint. Cartilage over the posterior portion of the medial border of the talar dome was eroded. The cartilage over a small area anterior to this was soft and boggy; this was removed and the underlying bone lightly curetted. The remainder of the joint looked normal. A boot cast was employed for seven and one-half weeks. Subsequent range of motion gradually increased until full movement was present eleven months after operation. During the next two years there were no symptoms referable to the left ankle.

The right ankle, however, continued to be painful at intervals, with increasingly frequent episodes of "catching", stiffness, and aching. By December 1951, locking occurred repeatedly. Arthrotomy of the right ankle, March 5, 1952, showed a loose body, covered by fibrillated soft cartilage, on the medial border of the talar dome. The fragment, which measured one by two centimeters, was removed. Recovery was slower than with the left ankle. Intermittent discomfort and swelling occurred during the next two years (Fig. 15-D). The surgeon in charge of this patient suggested that the persistence of symptoms might be due to one or more small bone fragments still present in the joint cavity.

In an interview with the patient on March 6, 1954, she was asked if she could recall any injury to the ankle, previous to 1949. She then recalled that she had had painful ankles throughout her life; that she had always had to wear low-heeled shoes; that one foot had been in inversion during one winter, when she was a child; and that in 1931 she had fallen off the suspended rings in her high-school gymnasium, spraining her right ankle so severely that she limped for four months. From 1944 until 1947 her work required standing, which caused continuous pain in both ankles—worse in the afternoon and better after a night's rest. For the two years immediately preceding the date of onset, as given by her during the first examination, she had had a sedentary occupation and less discomfort in the ankle. During her original examination, when asked about the occurrence of trauma, she gave a negative answer because she thought the question referred only to recent trauma.

CASE 23. W.C., a man, forty-seven years of age, had no complaint concerning his left ankle until August 15, 1957, when, descending from a truck, he set his foot on a small rock which turned with him and sprained his ankle.

When examined at the hospital immediately after his injury there was tenderness over the posterior fasciculus of the deltoid ligament and over the entire lateral malleolus, together with a moderate degree of swelling of the ankle and limitation of motion of the foot in both plantar and dorsal flexion. There was no other associated injury.

Roentgenographic examination made at the time of the first visit showed a tiny chip of

TABLE I

ANALYSIS OF TWENTY-FOUR CASES OF LESIONS OF THE DOME OF THE TALUS

Case number	1	2	3†	4	5	6†	7†	8†	9	10	11
Sex of patient	M	F	M	M	M	M	M	F	NR*	M	F
Age at onset of symptoms (years)	30	62	17	32	36	35	18	52	NR	30	62
Duration of symptoms (months)	0	0	0	0	0	14	0	36	NR	96	14
History of trauma	Yes	Yes	Yes	Yes	Yes	Yes	Yes	Yes	NR	Yes	Yes
Type of symptoms (sprain or arthritis)	Spr.	Spr.	Spr.	Spr.	Spr.	Arthr.	Spr.	Arthr.	NR	Arthr.	Arthr.
Ankle affected (left or right)	L	R	R	R	R	R	L	R	L	R	R
Site of lesion (medial or lateral)	Lat.	Lat.	Lat.	Lat.	Lat.	Lat.	Med.	Med.	Med.	Med.	Med.
Stage of lesion ** (1, 2, 3, or 4)	4	1	2	2	3	3	4	2	1	2	1
Diagnoses recorded (fracture, osteochondritis dissecans, or both)	Both	Fract.	Fract.	Fract.	Fract.	Both	Fract.	Both	Both	Both	Both
Concomitant injuries	No	No	No	No	No	Yes	No	No	NR		Yes
Conservative treatment:											
Duration of treatment (months)	0	½	¾	2	2	16	¾	36	NR	96	14
Clinical results of treatment	0	?	Poor	Good	Good	Poor	Poor	Poor	NR	Fair	Poor
Operative treatment:											
Type of operation (arthrotomy only, removal of chip, or replacement of chip)	Replace.	0	Remov.	0	0	Remov.	Remov.	Remov.	0	0	Arthr.
Pathological examination	0	0	Yes	0	0	Yes	Yes	NR	0	0	0
Subsequent immobilization (months)	2	0	1¼	0	0	2½	NR	1½	0	0	NR
Clinical results of treatment	Good	0	Good	0	0	Good	Good	Good	NR	Fair	Poor
Follow-up duration (months)	60	½	9	2	2	6	58	7	NR	0	12
X-ray appraisal of results	Good	0	Good	Good	Good	Good	Good	NR	Fair	0	Poor

* Items that were not recorded in the original histories are indicated by NR.

** One feature not included in tabulations in previous reports is the stage of lesion. This is an arbitrary classification which was developed to aid understanding of the etiological mechanism of the fracture and to help in determining the appropriate treatment. The stages are:

Stage One—a small compression fracture.

Stage Two—incomplete avulsion of a fragment.

Stage Three—complete avulsion without displacement.

the bone below the medial margin of the articulating surface of the talus, apparently coming from the medial margin of the talus. Treatment was by compression dressing for three and one-half weeks. There was no improvement during this time, and the patient was admitted to the hospital on September 10, 1957.

Arthrotomy of the ankle was performed on September 11 through a posterior approach, without osteotomy of the malleolus. A small depressed chip fracture of the posteromedial aspect of the dome of the talus was found. This was removed by a bone gouge and the articular cartilage about the edge of the defect, approximately one-half of an inch in diameter, was beveled. A compression dressing without cast immobilization was applied.

Postoperative progress was slow because of persistent edema of the lower leg and foot. The patient returned to work as a highway laborer on March 24, 1958.

The pathological report, which included the scrapings from the crater, showed cartilage and cancellous bone fragment exhibiting some fibrosis and osteoblastic activity. Roentgenographic appraisal showed satisfactory postoperative appearance, and the clinical course was deemed good.

CASE 24. G.H., a boy, eighteen years old, was first seen on November 27, 1956. At age sixteen, while playing high-school basketball, he sprained his right ankle badly; he had an identical injury one year later. The patient had pain, swelling, and crepitus in the ankle after activity; these symptoms subsided with rest. The only treatment was elastic bandage and application of heat. There were no concomitant injuries.

Examination showed a complete range of motion with loud crepitus on motion; there was no swelling or tenderness at the time of examination.

TABLE I—*Continued*

12	13	14†	15	16	17	18 F†		19†	20†	21†	22†	23	24
M	F	F	M	F	F			M	M	M	M	M	M
NR	47	27	15	70	34	33	33	14	24	10	18	47	21
3	"Years"	$\frac{1}{2}$	12	$\frac{3}{4}$	6	"8"	"8"	1	120	12	24	0	0
Yes	No	Yes	Yes	Yes	Yes	Yes	Yes	Yes	Yes	No	Yes	Yes	Yes
NR	Arthr.	Spr.	Arthr.	Spr.	Arthr.	Arthr.	Arthr.	Spr.	Arthr.	Arthr.	Arthr.	Spr.	Spr.
R	R	L	R	R	R	L	R	R	L	L	R	L	R
Med.	Med.	Med.	Med.	Med.	Med.	Med.	Med.	Lat.	Med.	Med.	Lat.	Med.	Lat.
1	2	1	2	2	2	4	3	2	3	4	4	2	2
OD	OD	OD	OD	Both	OD	OD	OD	OD	OD	OD	Both	Fract.	Fract.
	Yes	Yes	Yes	Yes	Yes	Yes	Yes	Yes	Yes			No	No
3	0	1	18	$\frac{3}{4}$	33	9	19	5	122	14	24	1	0
NR	Fair	Poor	Fair	Poor	Poor	Poor	Poor	Poor	Poor	Poor	Poor	Poor	0
NR	0	Remov.	0	0	0	Remov.	Remov.	Remov.	Remov.	Remov.	Remov.	Remov.	Remov.
NR	0	NR	0	0	0	NR	NR	NR	NR	NR	twice Yes	Yes	0
NR	0	NR	0	0	0	2	NR	$\frac{3}{4}$	$2\frac{1}{4}$	$\frac{1}{4}$	$2\frac{1}{4}$	0	1
NR	0	Good	0	0	0	Good	Good	Good	Good	1-Poor 2-Good	Good	Good	Good
NR	20	16	18	0	33	48	24	50	3	48	22	11	4
NR	0	Good	Poor	NR	Poor	Good	Good	Good	Good	Good	Good	Good	Good

Stage Four—avulsed fragment displaced within joint.

† We do not endorse the use of the criteria good, fair, or poor with reference to the appearance of the empty crater in postoperative roentgenographic evaluation of patients in whom the fragment was removed, since the fibrous filling of the crater cannot be seen in films. The chief value of the postoperative roentgenogram is the proof of presence or absence of small bone fragments overlooked at operation. The evaluations of such cases in Table I were those reported by the roentgenologists, and have been included only to permit comparison with Table II of Rödén, Tillegård, and Unander-Scharin.

Roentgenographic examination showed an avulsion fracture of the anterior aspect of the lateral border of the talus, a Stage Four fracture.

Operation, performed on December 4, 1956, consisted in removal of the multiple fragments and osteotomy of the fibula to give access to the ankle joint. A toe-to-groin cast was applied.

The patient returned to work, operating a shoe-making machine, on January 25, 1957. The cast was removed on February 8, 1957. Four months after operation he had no complaints concerning the ankle. All symptoms had been relieved and he was participating in amateur athletics without disability.

The characteristic features of the twenty-four patients with twenty-five osteochondral fractures of the superior surface of the dome of the talus are listed in Table I.

REVIEW OF THE LITERATURE

Our review of medical literature on the subject of osteochondral lesions of the talus has produced reports of two cases of loose bodies in the ankle joint, thirty cases of flake fractures, and 151 cases of osteochondritis dissecans—183 cases in all. Eight of the patients with osteochondritis dissecans had bilateral ankle lesions, giving a total of 191 fractures. These reports are listed in Table II.

TABLE II

PREVIOUSLY PUBLISHED CASES OF TRANCHONDRAL FRACTURES OF THE TALAR DOME

Entity	Authors	Year	No. of Cases	Entity	Authors	Year	No. of Cases
Loose Bodies	Monro	1856	1	Fractures	Vaughan and Stapleton	1947	4
	Stevenson	1925	1		Janes	1947	1*
	Total		2		Lavner	1947	1
Osteochondritis Dissecans	Kappis	1922	1		Ray and Coughlin	1947	13*
	Wolff	1926	2		Eberhard	1947	3
	Breitländer	1927	1		Soeur	1950	1
	Cordes	1927	1		Simpson	1950	1
	Harms	1927	1		Howorth	1952	1
	Vogel	1927	1		Green and Banks	1953	1
	Deutschländer	1928	1		Rödén, Tillegård, and Unander-Scharin	1954	55**
	Axhausen	1928	1*		Anderson and LeCocq	1954	6
	Diaz Garcia	1928	1		DeGinder	1955	19
	Läwen	1929	4		Cameron	1956	1
	Sidler	1929	1		Total		151
	Radicke	1930	1	Flake	Rendu	1932	1
	von Staa	1930	1		Eskesen	1942	6
	Fairbank	1933	1		Wilner	1946	1
	Pérez Dueño	1933	2		Kleiger	1948	8
	Hellström	1934	1		Marks	1952	1
	Ribbing	1937	1		Coltart	1952	1
	Myhre	1939	3		Nisbet	1954	3
	Hoffmann	1939	1		Bosien, Staples, and Russell	1955	9
	Burr	1939	1		Total		30
	Brickey and Grow	1940	1	Grand Total, Cases			183
	Mensor and Melody	1941	1				
	Eskesen	1942	1				
	Lewis	1942	1				
	Aronsson	1942	4				
	Cobey	1943	3				
	Cohen	1943	1				
	Dawson	1943	1				
	Hutchison	1943	2				
	Lagomarsino	1944	1				
	Wilner	1946	1		Grand Total, Fractures		191

* 1 bilateral case each

** 5 bilateral cases

NOMENCLATURE

The lesions discussed herein have been classified and reported under many different names. None of the names presently in use is at the same time accurate, comprehensive, and specific. Since the fracture concerned is a specific type with individual characteristics that set it apart from other fractures, it deserves both recognition and a distinctive name. The name proposed for this entity is *transchondral fracture*, a name which is correct from both anatomical and etiological points of view.

TRANCHONDRAL FRACTURES

Definition

A transchondral fracture is a fracture of the articular surface of a bone, produced by a force transmitted from the articular surface of a contiguous bone across the joint and through the articular cartilage to the subchondral trabeculae of the fractured bone. Either of two physical types of fracture may result. First, the fracture may result in a small area of compressed trabeculae, with or without demonstrable damage to the overlying cartilage. Or it may be an avulsion of an osteocartilaginous flake.

The transchondral fracture differs from other small compression or chip fractures because of several unique characteristics. It is difficult to recognize clinically

as a fracture since it may occur as a result of trauma so trivial that it passes unnoticed, or its presence may be masked by more painful nearby soft-tissue injuries. The compressed or avulsed segment of bone has no soft-tissue attachments, no blood supply, and no nerve supply, and is consequently unusually susceptible to the development of avascular, aseptic necrosis.

Incidence

Numerical incidence: Two hundred and fourteen transchondral fractures of the dome of the talus have been identified. This figure is certainly too small. It has been necessary, on the grounds of accuracy, to exclude cases of chip or avulsion fractures of the talus that have not been described or located with sufficient pre-

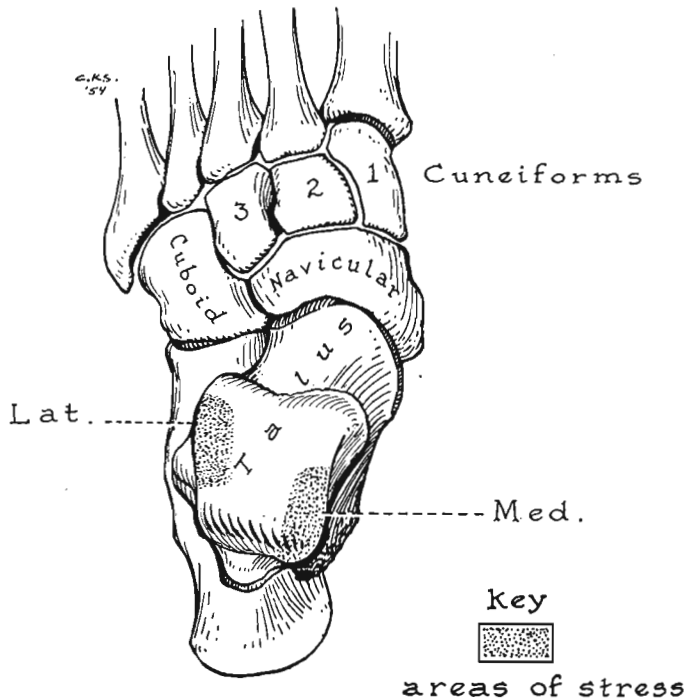


FIG. 4

Drawing showing the usual sites of transchondral fractures of the talar dome. Of 201 cases there were eighty-eight fractures in the lateral border (43.7 per cent), most of which were located in the middle third of the border. The medial border was involved in 113 fractures (56.3 per cent), usually in the posterior third of the border.

cision to make certain their identity. Coltart¹⁹ reported fifty-six chip or avulsion fractures of the talus, but located only one. Lipscomb and Ghormley⁴⁹ reported sixteen but located none. Wilson⁸¹ reported four cases but located none. Boyd and Knight⁸ gave no statistics. Only a short abstract of Brewer's report¹¹ could be obtained*.

Comparative incidence: Coltart¹⁹, reviewing statistics of the Royal Air Force from 1940 to 1945, listed a total of 25,000 fractures of all bones. Of this number, 4,000 affected the ankle and foot. There were 114 cases of fracture of the

*Three cases that were included in previous reviews of flake fractures of the ankle are not included in the present study on the ground that they did not concern fractures of the dome of the talus: Schnaberth's⁸⁵ lesion was in the subtalar joint, Schosserer's⁸⁶ fracture was of the anterior corner of the tibia, and Schulte-Tenckhoff's⁸⁷, from the lateral malleolus. The two lesions reported by Schulte-Tenckhoff draw attention to the fact that the margins of the talus usually give way before the impacting areas of the tibia or fibula are damaged.

talus of which fifty-six were chip or avulsion fractures. Wilson listed seventeen fractures of the talus, of which four were chip or sprain fractures but, since he specified that these were caused by ligamentous avulsion, it is doubtful if his cases should be included. Lipscomb and Ghormley⁴⁹ reported 114 fractures of the talus, of which sixteen were chip fractures. On the basis of these statistics, approximately 0.09 per cent of all fractures are transchondral fractures of the talus.

Bosien, Staples, and Russell⁷, in 1955, reviewed a series of ankle sprains in men in two college classes. They reported that 113 patients had incurred 133 sprains. In this number they identified nine cortical avulsion fractures of the talus, an incidence of 6.75 per cent.

Anderson and LeCocq¹, in 1954, reported osteochondritis dissecans in six of twenty-seven cases of sprains of the lateral collateral ligament of the ankle.

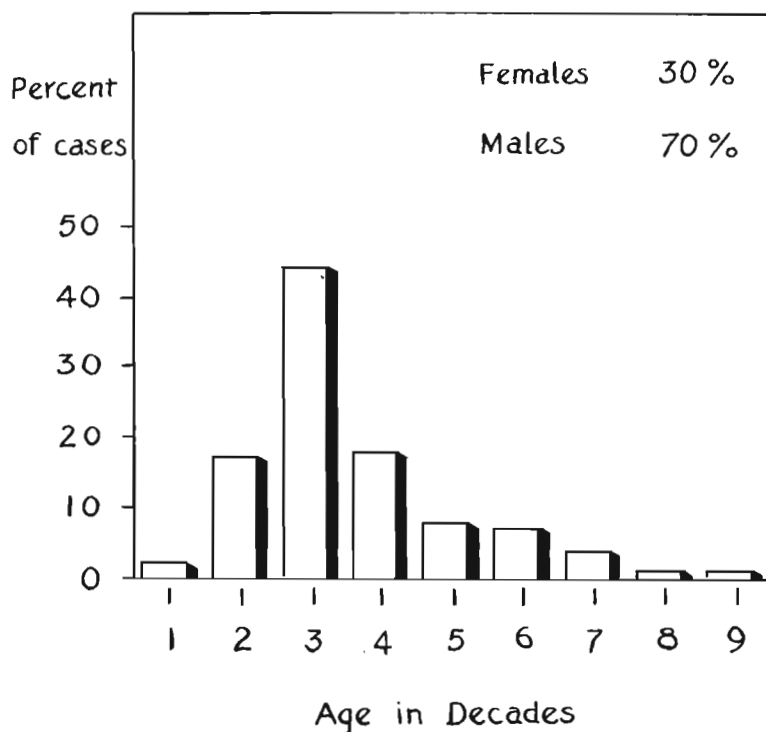


CHART 1

The incidence of transchondral fractures on the basis of sex and age. The sex of the patient was mentioned in 173 cases, of which there were 123 male and fifty female patients. The age of the patient was recorded in 164 cases; the peak incidence was in the third decade.

Sex incidence: Of the 214 fractures reviewed, the sex of the patients was given in 174 cases: male, 124 cases (approximately 70 per cent); female, fifty cases (30 per cent). Most of the cases included in these figures were reported from military sources which could be expected to have a predominantly male population.

Age incidence: The patient's age was reported in 165 cases. The youngest patient was five years old, the oldest was eighty. The age incidence, by decades, is shown in Chart I.

Ankle affected: Of 166 fractures, the right talus was affected in eighty-nine patients (53.6 per cent), the left talus in seventy-seven (46.4 per cent).

Site of lesion: Of 201 fractures in which the site was described in the text or shown in roentgenograms, the lesion involved the lateral border of the talus

in eighty-eight patients (43.7 per cent) and the medial border in 113 (56.3 per cent) (Fig. 4).

Stage of lesion: The stage of the lesion was indicated in 100 patients: Stage One, 15 per cent; Stage Two, 36 per cent; Stage Three, 28 per cent; and Stage Four, 21 per cent.

Etiology

The etiological mechanism that produces a fracture is usually obvious. The symptoms and roentgenographic appearance are characteristic. Treatment by reduction and adequate immobilization ordinarily results in healing, but if immobilization is incomplete or of too short a duration, delayed union or non-union ensues and may last indefinitely.

The mechanism that causes osteochondritis dissecans, on the other hand, has been a matter of dispute for almost seventy years. In 1931 Wagoner and Cohn⁷⁷ made a complete review of the literature up to that time. They listed sixty-four reports; trauma was noted as the causative agent in forty-one. The remaining twenty-three offered eighteen causes other than trauma; of these eighteen causes only one, arthritis, was acceptable enough to be selected by four authors.

Most of the theories of causation, other than that of trauma, have been discarded on the grounds of lack of evidence, but some continue to have their advocates. The hereditary factor, favored by Wagoner and Cohn, was revived in 1955 by Gardiner³¹ and Pick⁵⁷. However, only six families were reported as having osteochondritis dissecans in more than one of their members, a fact which makes the hereditary theory statistically untenable.

The theory of spontaneous necrosis has had strong supporters whose chief point of argument has been the fact that no other etiological factor has been completely proved.

The theory of trauma as the etiological factor has had the greatest number of adherents and has become increasingly popular. Yet some of the authors who espouse the case for trauma say that the exact mechanism is still unknown and they have been hesitant to identify osteochondritis dissecans as a fracture. Rödén and his associates⁶³ reported fifty-five cases and attributed all of their lateral-margin lesions, except one, to trauma, noting that 61 per cent of their forty-one patients with medial-margin lesions had had trauma. DeGinder²⁴ attributed all of his nineteen cases to trauma.

Lesions with identical characteristics have been called fractures by some authors and osteochondritis dissecans by others. Eskesen²⁸ and Wilner⁸⁰ presented cases of fractures and of osteochondritis dissecans as different entities, but failed to indicate the distinctive features.

Why have not all the cases been called fractures? The answer lies in the fact that it has not been demonstrated clearly that the diagnosis of fracture could be compatible with three characteristics that usually do not pertain to fractures: (1) that a fracture could occur without recognizable trauma, (2) that the resulting fracture could be painless, and (3) that proper reduction followed by immobilization for a reasonable length of time would not produce bone union. Each of these three characteristics appears to be at odds with one of the basic concepts of fractures.

If fractures embodying all three of these characteristics could be produced experimentally or confirmed by clinical evidence, there should remain no reasonable objection to classifying the lesions of osteochondritis dissecans as osteochondral fractures.

Anatomical Investigation

Purpose: Experiments were undertaken with the hope of discovering whether typical lesions of osteochondral fractures and osteochondritis dissecans of the

dome of the talus could be produced in the laboratory by applying various forces to the ankles of amputation specimens.

Materials: Preliminary experiments using the limbs of cadavera from the dissecting room were unsatisfactory, owing to the age and nutritional condition of the specimens and the alterations in the relative strength of the bone and soft parts caused by the materials used for preservation. Accordingly, above-the-knee specimens were used—ten after temporary preservation by refrigeration, and five immediately after operation. The freshly amputated specimens proved to be the most satisfactory.

Methods: Some difficulty was experienced in holding the foot in the proper position while force was applied to the knee and thigh. The most satisfactory method involved the use of a heavy block of wood made with a deeply slanting groove in the center (Fig. 5). The foot of the specimen was placed in the groove

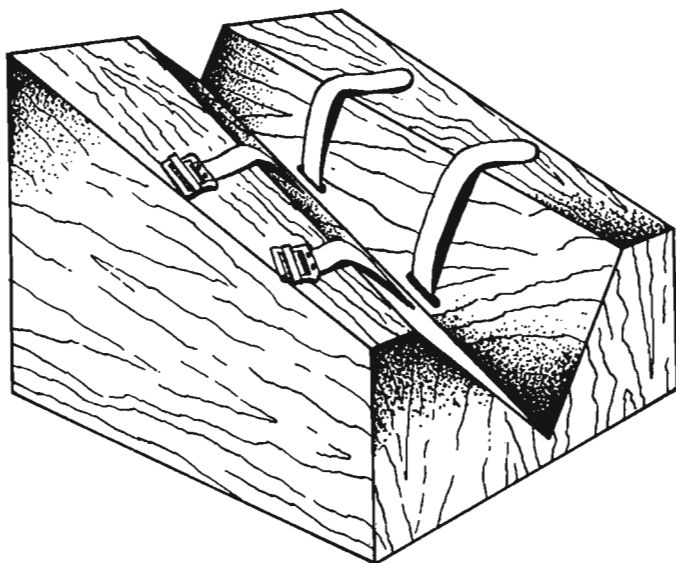


FIG. 5

Drawing of the wooden block used in anatomical experiments to secure the foot of the amputation specimen during manipulation of the knee and thigh. The inclination of the groove made it possible to immobilize the foot with the ankle in any desired position.

and strapped tightly in the desired position. The slant of the groove and the inclination of the sides permitted a choice of any combination of inversion or eversion with plantar flexion or dorsiflexion of the foot, with respect to the vertical lower leg.

The block, holding the foot, was placed on the floor and held immobile by one of us. The other stood beside the block, rested his left hand upon the knee of the specimen which was flexed to 90 degrees, leaned forward with chest upon the left hand to put his body weight on the knee, then with the right hand maneuvered the thigh of the specimen into further inversion, eversion, or rotation of the ankle.

When, during the application of force, the normal range of motion of the joint was exceeded, a cracking, crunching sound was emitted by the ankle, caused by tearing of the collateral ligaments and crushing of the trabeculae of the dome. The ankle then was dissected free and examined for damage. In some experiments no damage to the talus could be found, although the collateral ligaments were torn. In examining the talus it was necessary to recall that apparently undamaged articular cartilage could conceal a Stage One fracture. A report of no damage to the talus should not be made until the talus has been sectioned through the suspected area.

TABLE III
RESULTS OF ANATOMICAL EXPERIMENTS

Type of Manipulation	No. of Specimens	Experimental Fractures Produced	
		Lateral Border	Medial Border
Recent (Refrigerated) Amputation Specimens			
Eversion + dorsiflexion	1		
Eversion + plantar flexion	1		
Inversion + dorsiflexion	2	1	
Inversion + plantar flexion	2		
Inversion + plantar flexion + rotation	4		1
Fresh Amputation Specimens			
Inversion + plantar flexion + rotation	5		1
Totals	15	1	2

The high rate of failure of the methods which occasionally produced fractures was due to the fact that only one experiment could be performed upon one specimen. Dissection of the ankle to determine the condition of the talus rendered the specimen unfit for further testing. Perhaps roentgenographic examination of the specimen after the application of force would have enabled us to determine the absence of fracture and have permitted us to remanipulate specimens in which the first attempts failed to produce fractures.

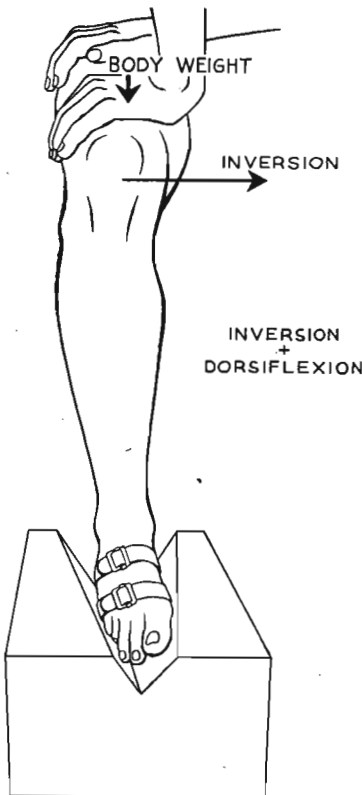


FIG. 6-A

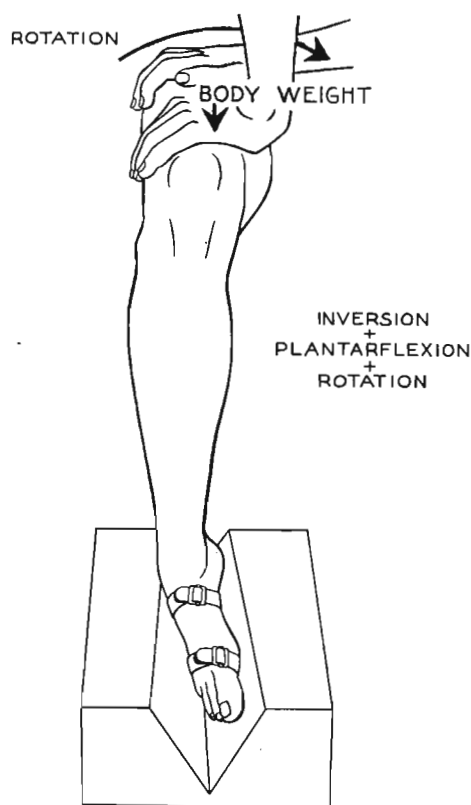


FIG. 6-B

Figs. 6-A and 6-B: Drawings illustrating the methods of manipulation of amputation specimens.

Fig. 6-A: The manipulation that produced fracture of the lateral border of the talus.

Fig. 6-B: The method of producing fracture of the medial border.

Lateral Lesion

A review of the operative findings in clinical cases of lesions of the lateral talar border showed that the following conditions usually were attendant upon the lesion: the lesion was found in the middle or anterior half of the lateral border, and damage was limited to two sites—the talar lesion and the lateral collateral ligament. There was no damage to the malleoli, to the medial collateral ligament, or to the interosseous (tibiofibular) ligament. Any lesion produced by experimental methods must produce the same, and no other, injury.

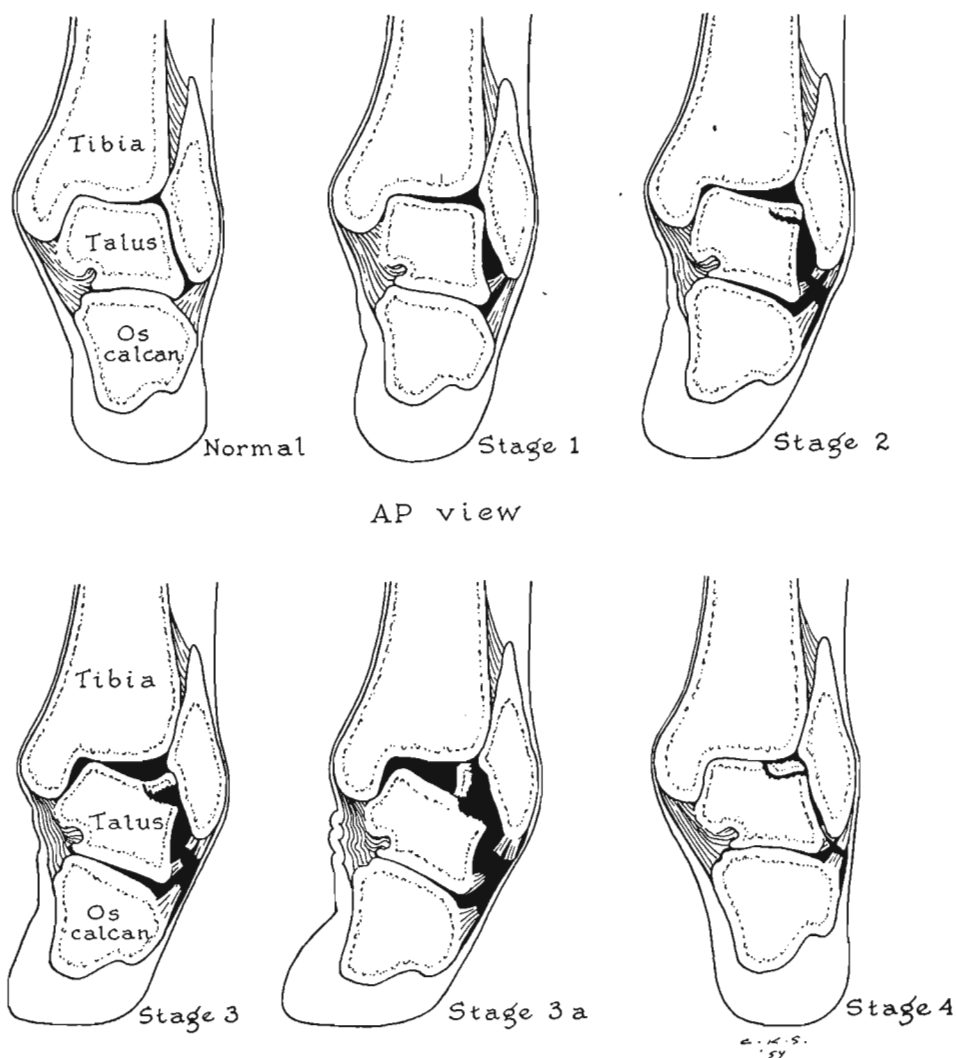


FIG. 7

Diagram showing the etiological mechanism of transchondral fractures of the lateral border of the talar dome. As the foot is inverted on the leg the lateral border of the dome is compressed against the face of the fibula (Stage One), while the collateral ligament remains intact. Further inversion ruptures the lateral ligament and begins avulsion of the chip (Stage Two), which may be completely detached but remain in place (Stage Three) or be displaced by inversion (Stage Four).

In these experiments the damage just described could be inflicted only by the maneuver of strong inversion of the dorsiflexed ankle (Figs. 6-A and 6-B).

In dorsiflexion of the ankle the wider anterior half of the talar dome was moved backward into the mortise, filling it snugly. In this position lateral rota-

tion in the frontal plane of the talus was impossible when only a moderate inverting force was applied. With the use of excessive inverting force, the talus within the mortise was rotated laterally in the frontal plane, impacting and compressing the lateral talar margin against the articular surface of the fibula, producing a small area of indentation in the talar margin—a Stage One lesion. If rotation were continued, a portion of the talar margin remained impacted against the fibula and was sheared off from the main body of the talus. This mechanism is illustrated diagrammatically (Fig. 7) and confirmed clinically (Figs. 3-A through 3-D).

This mechanism produced the experimental fracture of the anterior third of the lateral talar border as shown in Figure 8—a Stage Two lesion.

The importance of the lateral collateral ligament of the ankle in this mechanism should be noted, for it explains the difference in symptoms between the first

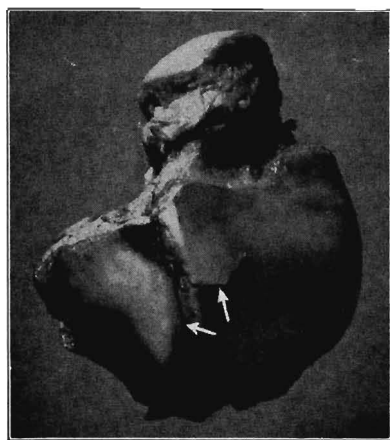


FIG. 8

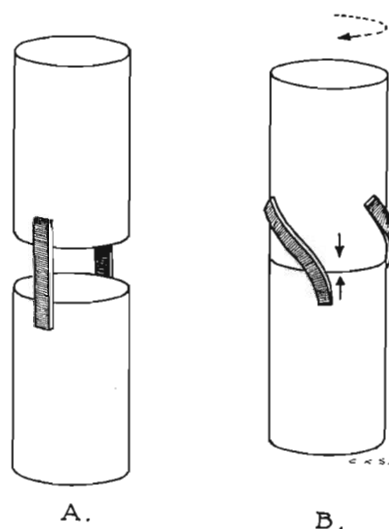


FIG. 9

Fig. 8: Photograph of transcondral fracture of the lateral border of the talar dome which was produced experimentally in an amputation specimen by forcible inversion of the dorsiflexed ankle. The fractured fragment, incompletely avulsed, is a Stage Two fracture of the antero-lateral margin.

Fig. 9: Diagram illustrating the principle of torsional impaction as applied to a diarthrodial joint. In A the bones are represented by cylinders, the joint space is exaggerated for clarity, and the collateral ligaments are shown as thongs. In B, rotation of the upper cylinder on the fixed lower cylinder changes the direction of the ligaments, shortening their effective lengths and drawing the cylinders together until impaction occurs. In the ankle joint where the ligaments are taut at the beginning of rotation, only a few degrees of rotation are necessary to produce great impacting force.

and second stages of the lateral fracture. In the first stage the compression of the talar margin took place before the lateral ligament was stretched to the point of rupture. As a result, a clinical Stage One lesion would be almost painless, the symptoms of sprain being absent or minimal, and the compression fracture being painless in itself owing to the absence of sensory nerve endings in the articular cartilage and the minimal sensation in the cancellous bone which the cartilage overlaps^{5,9,15,20,21,32}.

Before continuation of the rotation of the talus could produce the second stage of the lesion, the middle and anterior fasciculi of the lateral collateral ligament had to rupture, as was found in the patient in Case 1 of this series. Fractures of the second, third, and fourth stages, all painless in themselves, then must be accompanied in clinical cases by the symptoms of acute inversion sprain: pain over the torn lateral ligaments.

In these experiments no injury to the malleoli, to the deltoid, or to the interos-

seous ligaments was found. Attempts to produce the lateral lesion by any other combination of movements of the ankle were fruitless. From our preliminary studies of the ankle joint in motion, utilizing both intact and coronally sectioned specimens, it appeared that eversion could play no part in the production of either lateral or medial fractures because of the shortness and obliquity of the articular face of the medial malleolus, and the strength of the middle fasciculus of the deltoid ligament. We, therefore, did not sacrifice specimens needlessly in eversion manipulations.

Medial Lesions

In a review of the clinical features of medial-margin lesions the following points were noted. In some cases no history of trauma could be identified (in thirty-three of 183 cases—18 per cent—no trauma was reported). Most authors reported that the patient's injury had been caused by inversion or adduction of the foot, but four cases (Harms' ³⁴ case, Burr's ¹³ first case, Ray and Coughlin's ⁵⁹ ninth case, Case 14 of the present series) occurred when the patient attempted to extricate the foot that had been caught by an external weight lying across the instep. Roentgenograms showed that the medial lesions, with one exception, were in the posterior half of the medial margin, that they appeared to be narrow in their anteroposterior diameter, that they were under the posterior inferior lip of the tibia, and that in some cases that lip of tibia appeared to have been indented upward (Fig. 15-A).

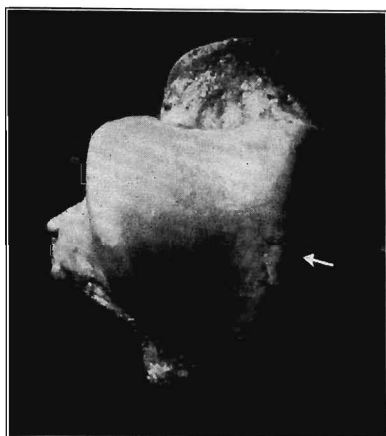

Fig. 10

Fig. 10: Photograph of transchondral fracture of the medial border of the talar dome which was produced experimentally in an amputation specimen by employing, in sequence, the forces of plantar flexion, inversion, and external rotation of the tibia on the talus. The compressed area, a Stage One fracture, is situated in the posterior third of the medial border, the site where most of the medial fractures have been found in clinical cases.

These points suggested that the mechanism might be: (1) plantar flexion of the ankle, (2) slight anterior displacement of the tibia upon the talus, (3) inversion of the ankle, and (4) lateral rotation of the tibia upon the talus (Fig. 6-B). With the employment of this sequence of forces, the following events were noted to take place in the ankle joint.

In plantar flexion of the ankle the narrow posterior half of the talar dome occupied the mortise somewhat loosely, owing to relaxation of the collateral ligaments, and lateral rocking of the talus in the mortise was permitted. Inversion of the talus turned its medial border uppermost so that the articular surface of the tibia rested only upon the ridge formed by the medial border of the talus. Slight forward displacement of the tibia on the inverted talus then removed from contact with the talar border all of the tibial articular surface except the posterior inferior lip. At this stage the two bones touched each other only at the intersection of two narrow ridges, the total area of contact amounting to approximately one-sixteenth of a square inch, or one-sixteenth of the normal area of articular contact. This raised the pressure in this small area to sixteen times the normal, jeop-

ardizing the integrity of this small, thrust-bearing portion of the talar surface.

The impacting force was further increased by the external rotation of the tibia on the talus. This caused the posterior lip of the tibia to move medially, grinding the posterior tibial lip across the talar border until the collateral ligaments became taut. When all slack of the collateral ligaments was fully taken up, further rotation of the tibia introduced an additional and powerful force of impaction owing to

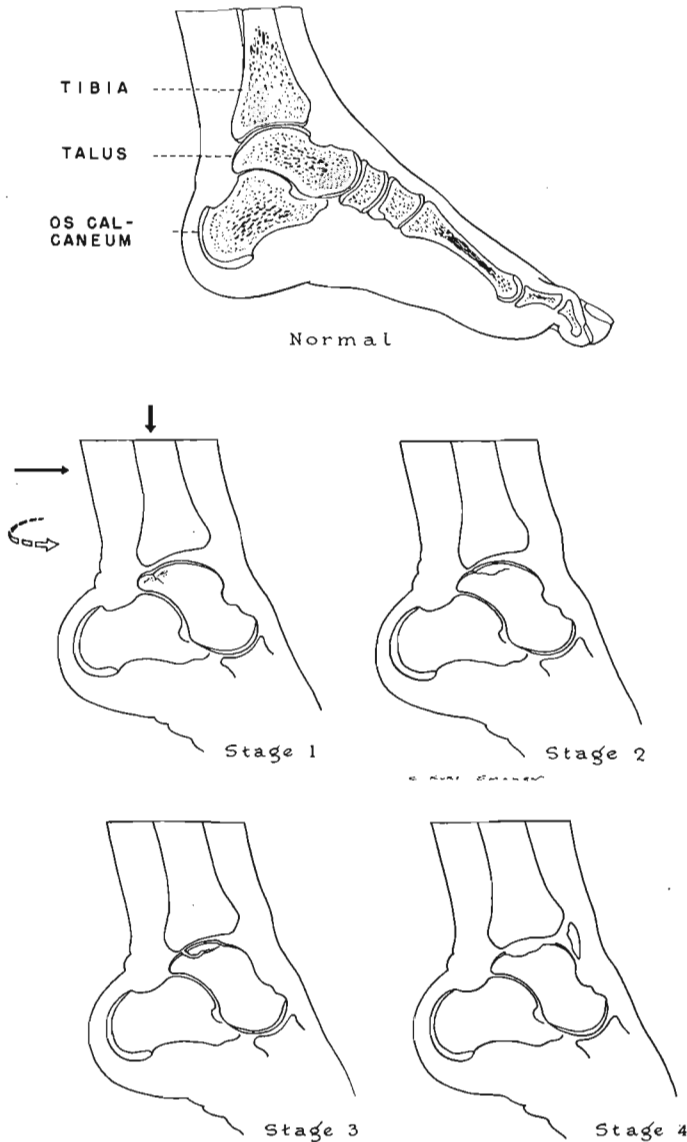


FIG. 11

Diagram showing etiological mechanism of transchondral fractures of the medial border of the talar dome. Plantar flexion of the foot with inversion, followed by rotation of the tibia on the talus produces a small area of compression (Stage One), the collateral ligaments remaining intact. Greater force causes the posteroinferior lip of the tibia to ride medially across the up-turned medial margin of the talus, gouging out an osteochondral chip which is partially detached (Stage Two), completely detached (Stage Three), or displaced within the joint (Stage Four). The second stage usually is accompanied by rupture of the posterior fasciculus of the deltoid ligament or of the anterior fasciculus of the lateral collateral ligament.

the change in direction of the fibers of the collateral ligaments from vertical to spiral, shortening their effective length and drawing the tibia and talus strongly together.

This mechanism might be called rotational or torsional impaction. According to physicists and engineers it has no other name. It resembles, somewhat, the action of a screw being used to join two pieces of wood: when the pieces come into contact, further rotation of the screw through only a few degrees produces a tremendous force of impaction. (An effective nutcracker can be made to illustrate this mechanism by joining two wooden cylinders together end-to-end by leather

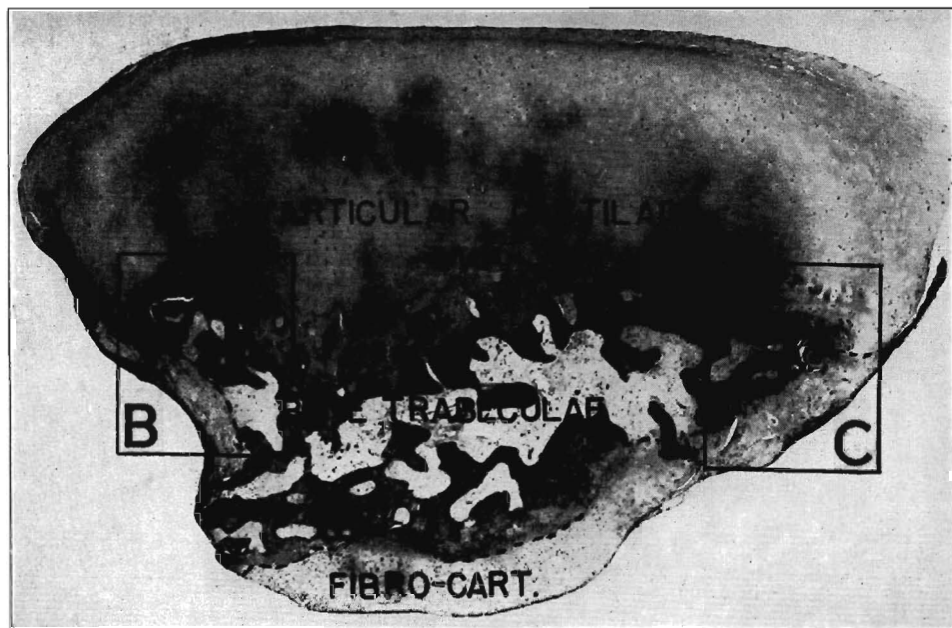


FIG. 12-A

Case 22. Photomicrograph ($\times 9$) of cross section of a transchondral-fracture chip from the talus. This free fragment was removed from the anterolateral compartment of the right ankle of a boy, eighteen years old, who had symptoms of two years' duration (Table I). The fragment had originated from a crater on the lateral border of the dome of the talus which, at operation, was filled with firm fibrous tissue.

The large fragment had an articular surface of hyaline cartilage. The entire fracture surface (broken line) was overgrown with firm fibrous and fibrocartilaginous tissue.

thongs parallel to the long axes of the cylinder. By rotating the cylinders in opposite direction, the adjacent ends are impacted forcefully.) Torsional impaction occurs in any diarthrodial joint when one bone is fixed and the other rotated upon its long axis (Fig. 9).

With the knee flexed to 90 degrees the mechanical advantage of the body weight is forty to one, the short arm being the radius of the tibia (one centimeter), the long arm being the length of the femur (forty to fifty centimeters). This mechanical system makes it possible for damage to occur to the medial margin of the talus even though the rotation is stopped short of the point of tearing the posterior fibers of the deltoid ligament. The force of torsional impaction appears to be the principal agent in the production of the medial-margin Stage One lesion, the so-called atraumatic osteochondritis dissecans, when applied to the previously plantar-flexed, inverted ankle. Clinically observed cases of this lesion have been characterized by a lack of history of trauma, owing to the painlessness of the bone lesion and the fact that the collateral ligaments had not been torn.

Further rotation of the tibia on the talus beyond the production of the Stage One lesion presumably resulted in rupture of the posterior fibers of the deltoid

ligament. The resultant freedom permitted more forward motion of the lip of the tibia upon the edge of the talus. This movement tended to shear off or gouge out a fragment of the talus to produce a Stage Two or Stage Three lesion, or if the fragment was displaced into the anterior compartment of the joint, a Stage Four lesion. This mechanism is shown in diagrammatic form (Fig. 11) and in roentgenograms of clinical cases (Figs. 3-E, 3-F, 3-G, 3-H, and 15-B).

In the clinical cases, Stages Two, Three, and Four have been marked by tenderness and pain over the posterior fasciculus of the deltoid ligament.

This mechanism explains satisfactorily the findings in the clinical cases. The

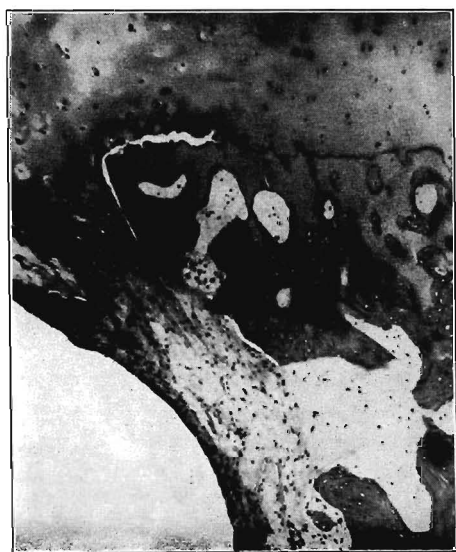

FIG. 12-B

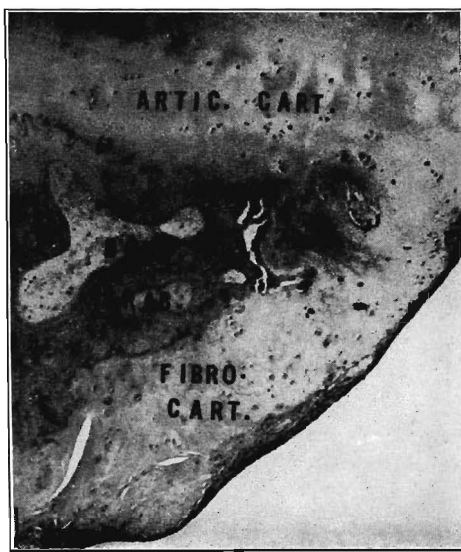

FIG. 12-C

Figs. 12-B and 12-C: Different areas clearly indicate living cells in hyaline cartilage, fibrous tissue, and fibrocartilaginous tissue. The lacunae in the bone trabeculae are vacant and the osteocytes are dead.

In such intra-articular loose bodies—without blood supply and nourished only by synovial fluid—hyaline cartilage, fibrous connective tissue, and fibrocartilage can live and grow for many years, but bone, although it retains its form and appearance, is dead.

Fig. 12-B: Enlargement ($\times 25$) of rectangle B in Fig. 12-A.

Fig. 12-C: Enlargement ($\times 25$) of rectangle C in Fig. 12-A.

lesion which was produced experimentally occurred in the proper location and only in that location; its dimensions were typical of those found in clinical cases, and the damage was confined to the same structures as those found damaged in clinical cases.

The existence and significance of the force of torsional-rotation impaction were not noted by previous investigators of the etiology of osteochondritis dissecans, although two hinted at it. Kappis⁴¹, who first described osteochondritis dissecans of the talar dome, suggested that the mechanism involved a tangential twisting force, and Roesner⁶⁴ described a tangential twisting force as producing the lesions of osteochondritis dissecans of the knee. Neither mentioned the importance of the role played by the collateral ligaments of the joints in producing rotational impaction.

We suggest that it was the failure to recognize and understand the force of torsional impaction that delayed, for so many years, the acceptance of osteochondritis dissecans as a fracture, and that it is this force which unobtrusively produced these small fractures. As previously mentioned, the lack of pain in the Stage One lesions was due to lack of sensory nerves at the fracture site.

Thus, two of the three objections to the inclusion of osteochondritis dissecans

as a fracture have been overcome. The third, the lack of healing after so-called reasonable immobilization, will be discussed under the heading of pathology.

Pathology

Once the osteochondral fracture has occurred—whether lateral or medial, Stage One or Stage Four—it can heal like other fractures, but only if it is reduced and immobilized until bone union has taken place.

In the Stage Four lesion the displaced chip cannot heal unless the fragment




FIG. 13-A

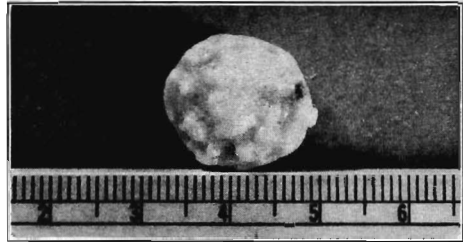


FIG. 13-B

Fig. 13-A: Articular surface of an osteochondral loose body removed from the knee of a man, thirty-two years old. At operation the fragment was lying free in the intercondylar notch, with no attachment to the surrounding tissues. The crater from which it had taken origin on the inferior and lateral aspect of the medial condyle was filled with firm fibrocartilage. Note the smooth normal hyaline cartilage.

Fig. 13-B: Fracture surface of the loose fragment. Note gross appearance of finely nodular cartilage.

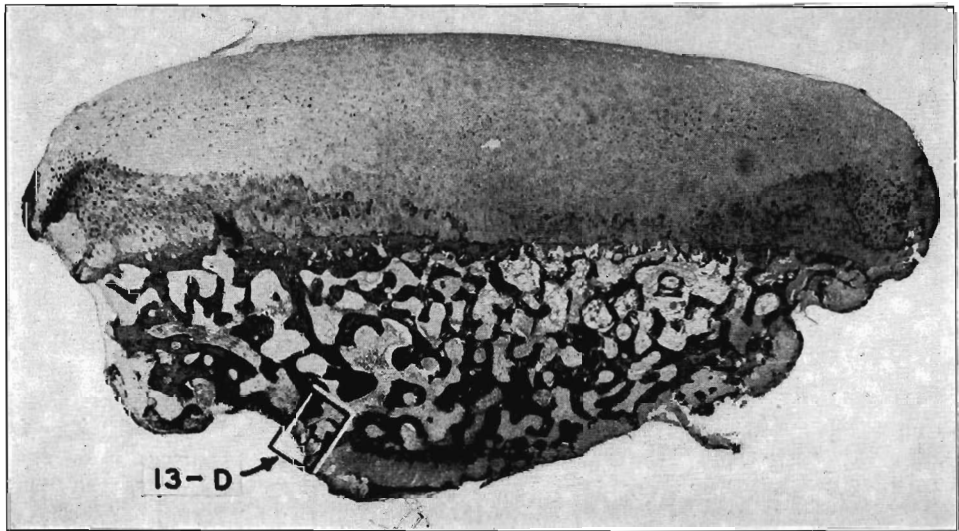


FIG. 13-C

Photomicrograph ($\times 13$) of cross section of osteochondral body. The articular surface (top) is composed of normal hyaline cartilage containing living chondrocytes. In the bone the lacunae are empty and there are no osteoblasts. Fibrous tissue has overgrown the rounded edges of the fragment, covering the fracture surface and penetrating the medullary spaces. About the edges and on the fracture surface the connective tissue has undergone metaplasia to fibrocartilage.

is replaced in its bed. In the other types of fractures—Stages One, Two, and Three—the blood supply of the compressed or avulsed fragment has been cut off at the fracture line. The process of healing can take place only by the growth of capillaries from the parent talus across the fracture line. The bone fragment remains in a condition of avascular, aseptic necrosis until the arrival of a new blood supply to nourish it and to bring scavenger cells to destroy the dead bone.

The cartilaginous portion of the fragment, on the other hand, continues to

live because of its low metabolic requirements. Deprivation of blood supply to the fragment is of no consequence to the cartilage, whose cells receive their nutrition from the synovial fluid. Those cells may grow peripherally about a loose fragment, ultimately investing the trabecular surface with cartilage (Figs. 12-A through 13-D).

Healing of the undisplaced fractures has been reported to occur. Cameron¹⁴ noted in his case report, that it required seven and one-half months for the fracture to show roentgenographic evidence of the establishment of union. In this case, as in others, the recognition of healing was based on roentgenographic evidence and clinical relief of symptoms; both criteria have been shown to be deceiving at times. There have been no reports of exploration or pathological examination of the reportedly healed lesions.

If immobilization of the fracture line is incomplete in degree or inadequate in duration, motion at the fracture line shears off the ingrowing capillaries, and the reparative process ceases. The attempted invasion of capillaries from the host (talus) apparently is a feeble one which is discouraged easily by motion at the fracture line. There have been no reports to tell how much motion can be tolerated, or for what length of time motion can be permitted before spontaneous healing can no longer take place. When the reparative process ceases, the host surface of the fracture becomes covered with dense fibrous connective tissue that seems to be impenetrable to capillaries. The fragment becomes a dead prisoner in a sterile cell.

The condition of the imprisoned fragment cannot improve, but there are several possibilities of further insult. Continued weight-bearing, with alternating application and release of pressure against the cartilaginous attachment of the Stage One or Stage Two fragment, may rupture the attachment, converting the fragment to the detached Stage Three or the displaced Stage Four lesion. Pressure may break off smaller fragments from the original fragment or from the margin of the crater. These satellite fragments may then be dispersed by motion to the various recesses of the ankle joint (Fig. 14-C). Where such fragments lie in contact with the synovial membrane they incite irritative reactions and may become attached to it. The frictional effect of the uneven joint surface during exercise presumably increases the temperature of the joint, producing the characteristic dull aching that accompanies synovial irritation³⁷. Ultimately, degenerative joint disease supervenes. Instability of the damaged talus within the ankle mortise, caused by deficiencies of the previously torn collateral ligaments, may lead to repetitions of the original sprain. Any or all of these eventualities may follow one fracture.

If the necrotic fragment is removed from the joint and the fibrous coating of the host surface curetted away, a new reparative process may begin. It has been reported that the defect becomes filled with fibrous connective tissue that restores the original shape of the talus and is of sufficient firmness and smoothness to act

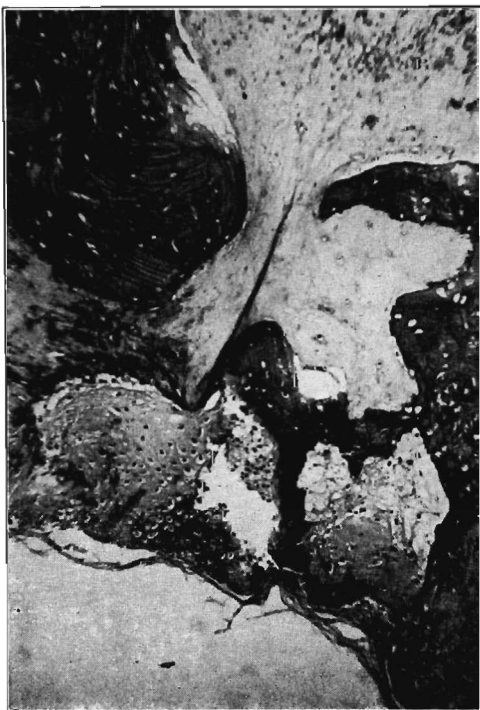

FIG. 13-D

Photomicrograph ($\times 100$) of fracture surface (See Fig. 13-C). Note fibrocartilage on fracture surface.

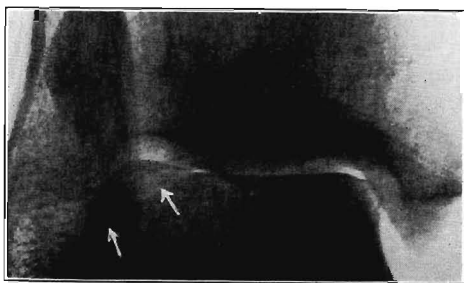

FIG. 14-A

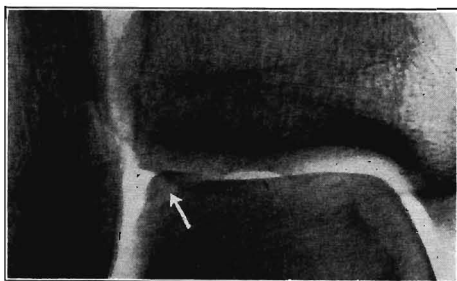


FIG. 14-B

Fig. 14-A: Anteroposterior roentgenogram of the right ankle (Case 5). Note that in this projection the medial margin of the talus is shown in profile, whereas the lateral margin is obscured by the superimposed fibula.

Fig. 14-B: Oblique projection (10 degrees of medial rotation) of same ankle as Fig. 14-A. Note how well the talofibular joint and the lateral margin of the lateral border of the talus are visualized.

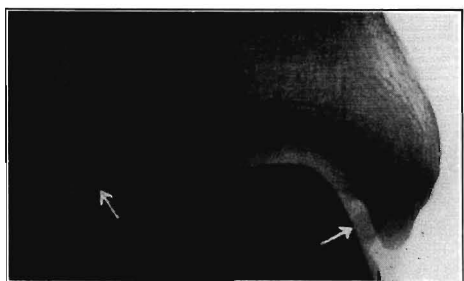


FIG. 14-C

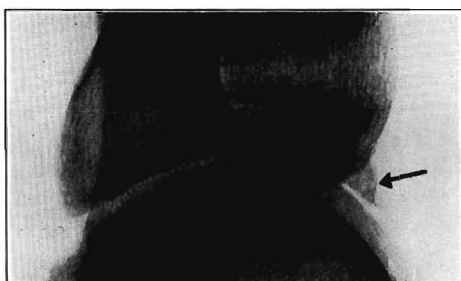

FIG. 14-D

Fig. 14-C: Oblique roentgenogram of the right ankle (Case 6) sixteen months after injury. The fragment on the lateral margin of the talus appears to be intact. A small spherical loose body seems to lie between the talus and the medial malleolus.

Fig. 14-D: Lateral roentgenogram of the same ankle as Fig. 14-C. There appears to be an osteophyte on the anterior lip of the tibia, but at operation both the loose body and the osteophyte were found to be small pieces of the fractured talus displaced and adherent to the synovial membrane.

as a satisfactory replacement for the missing bone⁵⁹. Burr¹³ reported a case in which the roentgenograms of the fracture, made seven years postoperatively, showed the defect to be filled with new bone. This statement was not confirmed by pathological examination.

In summary, the sequence of pathological events in the osteochondral fracture is: (1) occurrence of the fracture, (2) immediate development of avascular, aseptic necrosis of the osseous portion of the fragment while the cartilaginous portion lives, and (3) either union of the fracture by creeping substitution or sequestration and non-union of the fracture with the later complication of osteo-arthritis. The progress of creeping substitution is measured in months, not in weeks. Fractures involving even small fragments cannot reasonably be expected to heal with the rapidity displayed by other fragments of the same size having intact blood supply.

Symptomatology

There are no symptoms that are pathognomonic of transchondral fractures of the ankle. We could find no record of the diagnosis having been made on the basis of history and physical examination alone. New, or acute, fractures usually were diagnosed clinically as sprains. Chronic cases were diagnosed as arthritis.

Acute phase: The symptoms of new fractures are those of inversion sprain: pain in the torn collateral ligaments, swelling of the ankle, ecchymosis, and limitation of motion.

Duration of acute phase: The duration of symptoms of the acute phase varied

from several weeks to several months, governed by the severity of the accompanying sprain^{1,7,18}.

Atraumatic acute phase: The only new cases in which no diagnosis of sprain was made were those in which a Stage One lesion occurred without accompanying tear of the collateral ligaments. In these cases of the so-called atraumatic osteochondritis dissecans, the patients did not seek medical attention until the symptoms of the late, or chronic stage became manifest.

Chronic phase: The chronic phase begins with the subsidence of symptoms of sprain. The severity of symptoms depends on the degree of healing of the torn ligaments and on the extent of the fracture. The symptoms of the chronic phase in Stage One, Stage Two, and Stage Three fractures are those of osteo-arthritis (degenerative arthritis, traumatic arthritis, and arthrosis): freedom of pain when the joint is at rest, stiffness, crepitus, aching, swelling, and limitation of motion during and after exercise. In Stage Four fractures locking occurs occasionally in addition to the symptoms of osteo-arthritis and, at times, the symptoms of incomplete healing of the collateral ligaments: weak ankle, instability, pain on inversion of the ankle, and a tendency to recurrence of sprains.

The severity of symptoms of the chronic phase is subject to unexplained variations. Some patients report freedom from symptoms for long periods of time between recurrences (Cases 13, 17, and 18.)

Duration of chronic phase: The duration of symptoms of the chronic phase appears to be indefinite unless surgical intervention occurs. The longest duration of symptoms in a case reported heretofore was nineteen years⁶⁵. In the patient in Case 18 the duration, from childhood until the age of thirty-three, apparently was greater. The longest duration proved by roentgenograms was that of a case first reported by Hellström and Östling³⁵, with follow-up by Aronsson² of a physician, twenty-four years old, who sprained his left ankle. Roentgenograms were reported as showing no injury. One year later, while pursuing a bus, the patient felt a sharp pain in the left ankle. At that time roentgenograms showed an area of osteochondritis dissecans of the lateral border of the left talus. The roentgenographic appearance, when the patient was twenty-six years old, was unchanged and at thirty-eight, roentgenograms showed the lesion still not healed. In this case the duration, by history, was fourteen years and, by roentgenograms, thirteen years.

Physicians who treat sprains or arthritis of the ankle should keep in mind the possibility of the presence of a transcondylar fracture that has the potentiality, if it is not identified and treated properly, of causing prolonged disability. Roentgenographic examination is obligatory. A denial by the patient of injury or of previous symptoms should not be accepted as correct unless confirmed by thorough questioning (Cases 13 and 18).

Laboratory Findings

There were no significant variations from normal in the findings in blood and urine, and in cytology in cases of transcondylar fractures.

Synovial fluid from the affected ankle has been sanguineous in patients operated on within the first few days after injury (Case 1). We have not encountered any reports of analyses of synovial fluid from patients with chronic conditions.

Roentgenographic Diagnosis

Without exception, in the cases reviewed, the correct diagnosis was not made until the roentgenograms were examined. Clinical diagnoses made prior to that time were of either sprains or arthritis. Delay in having roentgenographic examination was responsible for failure of early recognition of the osteochondral lesions. In the present series the patient in Case 6 had symptoms for one year before roentgenograms were made; in Case 8, for thirty-two years; in Case 10, for eight years; in Case 17, for five years; in Case 18, for about twenty years; and in Case

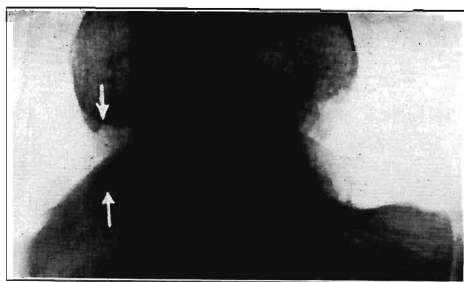


FIG. 15-A

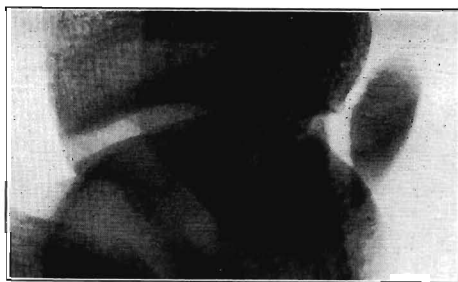

FIG. 15-B

Fig. 15-A: Lateral roentgenogram of the left ankle (Case 14). In this view of a Stage One fracture of the medial border of the talus the arrows indicate indentations of both the posterior lip of the tibial articular surface and of the apposing posterior medial border of the talar dome—evidence of impaction at these points.

Fig. 15-B: Lateral roentgenogram of the left ankle (Case 7). In this view the large displaced fragment of this Stage Four fracture of the medial border of the talus is clearly visualized in the anterior compartment of the ankle joint. Compare this with the antero-posterior view of the fracture shown in Fig. 3-H.

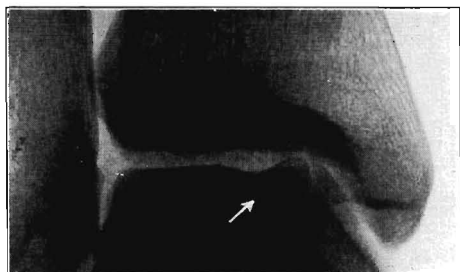


FIG. 15-C

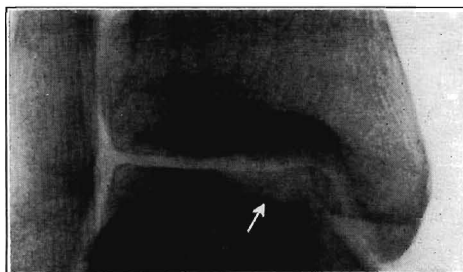


FIG. 15-D

Fig. 15-C: Preoperative roentgenogram of the left ankle (Case 18) showing a Stage Three fracture of the medial border of the talar dome. Note similarity of the appearance of this lesion to that shown in Fig. 3-H where the fragment was displaced into the anterior joint compartment.

Fig. 15-D: Roentgenogram of the same ankle as Fig. 15-C ten months after operation. There is no evidence of bone growth in the crater visible in the roentgenogram.

20, for ten years. The importance of early roentgenographic examination is obvious.

Roentgenologists should be aware of the possibility of the transchondral fracture occurring as a complication of a sprain, either recent or remote, and should be prepared to make an adequate number of exposures before returning a negative report, particularly if symptoms of a sprain are unduly persistent.

A minimum of three views, with the foot in neutral position, should be made: anteroposterior, oblique (10 degrees of medial rotation), and lateral, all centered over the joint line.

The anteroposterior view, the view most commonly made, usually shows the medial margin of the talus clearly, owing to the obliquity of the anteroposterior axis of the talus in relation to the mid-line of the foot, but it obscures the lateral border of the talar dome by superimposition of the lateral malleolus (Fig. 14-A).

The oblique view in 10 degrees of medial rotation opens up the talofibular joint and gives a clearer view of the lateral margin of the talus (Fig. 14-B). This is important in determining the presence of small detached fragments which might be overlooked in preoperative roentgenograms (Fig. 14-C). These fragments must be removed at operation.

The lateral view, although part of the dome is obscured by the overlying malleoli, shows the size of the lesion and indicates whether the lesion should be approached surgically from the anterior or posterior aspect of the ankle (Figs. 1-B and 15-B).

In some cases (Cases 8 and 19) the original roentgenograms were reported as showing no abnormality, but films made several days later showed the lesions clearly. Although it is possible that the roentgenograms made immediately after injury might not have shown the small lesion until more separation of the fragment occurred, it is more likely that the lesion was obscured by the position of the ankle during the first exposures. Additional roentgenograms made with the ankle in more dorsiflexion or more plantar flexion, both oblique and lateral views, should point out the lesion.

The appearance of a sclerotic line about the margin of the crater is suggestive of fibrosis of the fracture crater, implying that the lesion is at least several weeks old and that conservative treatment probably will not be successful.

The roentgenologist should be wary of judging the progress of healing. The fractures in Cases 1 and 17 were reported over a period of months to be healing well, yet later roentgenograms showed the lesions as unchanged from their appearance in earlier films; the errors were introduced by different positioning of the ankle with respect to dorsiflexion and plantar flexion in the anteroposterior views (Figs. 2-A and 2-B). For appraisal of union, the fragment must be shown in profile on top of the dome in all films. If such precautions are taken, union, if present, can be demonstrated by the progressive appearance of trabeculations crossing the fracture line.

Preoperative roentgenograms can give only an approximation of the size of the osteochondral fragment because of the relative radiolucency of the cartilaginous component. The fragment always appears larger at operation than in roentgenographic views.

The postoperative appearance of these lesions will be discussed after the clinical appraisal of postoperative results.

Concomitant Injuries

Transcondral fractures of the talus have been incurred in accidents of various degrees of severity. In some cases the trauma was not recognized as such. Many cases occurred from missteps, falls, and jumps, and some as the result of vehicular accidents.

As might be expected, in the majority of cases there were no concomitant injuries, unless the accompanying sprain is counted as such. Fractures of the lateral malleolus occurred in five patients, of the medial malleolus in four, of the body of the talus in four, and of the calcaneus in one; all within the affected foot. Other and more distant fractures were reported following more serious injuries (Case 6, present series).

Conservative Treatment

The various methods of conservative treatment employed were not described adequately in most of the reports reviewed. The number of weeks of treatment was rarely recorded. The failure to record that information has deprived the medical profession of one of the most valuable items of information that could be learned about these lesions: the length of time necessary for complete immobilization of the ankle to permit bone union of the fracture in children and in adults. Until such a standard—the minimal time necessary—has been proved it could be said that conservative treatment has not had a fair trial.

Without that information, it has been necessary to assume that conservative treatment, in some form, was continued throughout the period of the duration of symptoms and the follow-up period. This arbitrary extension of the period of conservative treatment may seem to be excessive until the type and intensity of different methods of conservative treatment are considered.

The types of conservative treatment mentioned were: rest, dressings, adhesive-plaster strapping, elastic bandages, braces, special shoes, casts, injections of procaine or hyaluronidase, and physical therapy of many types. Not mentioned,

but certainly a part of conservative management, were: avoidance of use of the part when possible, rest of the part after exercise was unavoidable, and the numerous home remedies which families and friends can suggest for the alleviation of joint pain.

Since these methods do not require constant medical attention, it is within reason to presume that some type of conservative treatment to some degree was followed by each patient throughout the period of his disability until (1) the lesion was cured, (2) the lesion was operated on, or (3) the period of observation ended.

Results of Conservative Treatment

In this paper it was necessary to grade results of treatment as simply as possible to permit comparison between methods of treatment. A result was rated *good* if the author reported freedom from symptoms or if only slightly annoying, but not disabling, symptoms persisted. A *fair* result was credited if the symptoms were somewhat improved, but some measure of disability persisted. The result was graded *poor* if the symptoms continued unchanged, even though periods of freedom from symptoms occurred at times. The requirement of later operation has been taken as *prima facie* evidence of a poor result of earlier treatment.

Conservative treatment was reported in 168 fractures, but the results of treatment were mentioned in only 154. The results were: good in twenty-six fractures (16.9 per cent), fair in thirteen (8.5 per cent) and poor in 115 (74.6 per cent).

Of the 154 fractures, fifty (32.5 per cent) required later operation.

The astonishingly low percentage of good results, particularly in view of the statements by some authors^{8,19,29} that these fractures are minor in character, not serious, and require only a few weeks of immobilization of the ankle, shows that the fractures have been underestimated and inadequately treated.

The popularity of conservative treatment has not been justified in view of the poor results obtained. It must be noted that conservative treatment with proper immobilization should give good results if employed promptly and long enough, but the results reported up to the present indicate that in most cases the degree and the duration of immobilization have not been adequate. One factor that has contributed to the poor results of conservative treatment has been the occurrence of so-called atraumatic osteochondritis dissecans in which the lack of symptoms during the acute phase precluded treatment until the development of late (arthritic) symptoms, when conservative treatment no longer could be expected to improve conditions.

Indications for Surgical Treatment

Seventy-three operations were performed on seventy patients. Of these, the indications for operation were apparent in fifty-seven. Five who were operated on had new or very recent injuries (8.8 per cent). Failure of previous conservative treatment led to fifty operations (87.7 per cent). Failure of previous surgical treatment, due to incomplete removal of fragments, necessitated reoperation in two cases (3.5 per cent).

Types of Surgical Treatment

Three types of operations were recorded in seventy-two fractures: arthrotomy for inspection only, removal of fragment, and replacement of fragment.

Arthrotomies without definitive surgery were reported to have been done when the lesions shown in roentgenograms could not be found at operation owing to the overlying cartilage's being intact. Four such arthrotomies were performed (5.5 per cent) in the seventy-two operations.

Removal of the fragment was the operation most often performed. It was used in sixty-five cases (90.3 per cent).

Replacement of the fragment was performed in three cases (4.2 per cent).

Results of Surgical Treatment

The results of operation, on a basis of clinical appraisal, were reported in sixty-two cases.

Arthrotomy, which should be regarded as having done nothing to improve the condition of the lesion and as having added the trauma of surgery, was judged as giving fair results in one case and poor in two. Results were not reported in one case.

Replacement of the fragment, employed in Stage Four lesions, produced good results in all three cases.

Removal of the chip, with results recorded in fifty-six operations, was reported as good in forty-seven cases (84 per cent), fair in six cases (10.7 per cent), and poor in three cases (5.3 per cent). Of the three cases with poor results, two were attributed to incomplete removal of fragments at operation. Both were reoperated with subsequent good results (included in the forty-seven good results just mentioned). The single remaining poor result of operation was not discussed by the authors.

Complications of Surgical Treatment

The following complications were reported: non-union in one case; incomplete removal in five cases, two of which required secondary operation; osteotomy of a malleolus, done to obtain adequate exposure, in four cases; osteo-arthritis in three cases; causalgia in two cases; and infection in one.

Results of Treatment in Children

The results of treatment previously given are those reported by the authors for all cases without respect to the age of the patients.

Some authors, writing on osteochondritis dissecans of joints other than the ankle, reported that the lesions heal spontaneously in children under seventeen years of age in a much higher percentage of cases than do similar lesions in adults. Van Demark⁷⁴ and Wiberg^{78,79} reported cases in which lesions in children's knees healed completely during prolonged conservative treatment, the duration stated to be at least six months, without weight-bearing. Van Demark recommended the following general rules for treatment of lesions of the knee: if the age of the patient is sixteen years or less, immobilize for six months or more; if the age is between sixteen and twenty years, the best method of treatment is uncertain; if the age is more than twenty years, operate to remove the fragment.

In order to compare the methods of treatment and their results in the cases of transcondral fractures of the talar dome reviewed herein with the opinions previously reported concerning lesions of the knee, a review of all the reported cases involving the talus in children was made.

There were no cases reported in children of sixteen years, but in fourteen children of fifteen years or less there were sixteen fractures (two were bilateral). The youngest patient was five years of age; one was nine; and the rest were eleven to fifteen.

Results of Conservative Treatment in Children

Conservative treatment was employed in fifteen of these fractures. The results were: good in three cases, fair in one, and poor in eleven. Of these fifteen conservatively treated cases, seven patients were operated on at a later date.

Results of Surgical Treatment in Children

Nine operations were performed on eight children. One had a new injury. Seven had had previous conservative treatment. One of the latter group had a second operation because of incomplete removal of fragments at the first operation. The results reported were: good in eight and poor in one (Table V).

TABLE IV
RESULTS OF TREATMENT AND DURATION OF FOLLOW-UP IN ALL REPORTED CASES OF TRANSCONDYLAR FRACTURES

Results of Treatment	Conservative Treatment Follow-up (Years)					Per Cent of Total	Surgical Treatment Follow-up (Years)					Per Cent of Total
	0 to 1	1 to 2	2 to 5	5 and Over	No. of Cases		0 to 1	1 to 2	2 to 5	5 and Over	No. of Cases	
Good	8	2	8	8	26	17.4	23	5	11	5	44	78.6
Fair	2	6	2	3	13	8.7	3	2	2	0	7	12.5
Poor	41	21	24	24	110	73.9	2	1	2	0	5	8.9
Totals	51	29	34	35	149	100.0	28	8	14	5	56*	100.0

* Fifty of the surgical cases had had failure of previous conservative treatment.

TABLE V
RESULTS OF TREATMENT AND DURATION OF FOLLOW-UP OF TRANSCONDYLAR FRACTURES IN CHILDREN

Results of Treatment	Conservative Treatment						Per Cent of Total	Surgical Treatment						Per Cent of Total
	Not Given	0 to 1	Follow-up (Years) 1 to 2	2 to 5	5 and Over	No. of Cases		Not Given	0 to 1	Follow-up (Years) 1 to 2	2 to 5	5 and Over	No. of Cases	
Good	0	1	0	1	1	3	20.0	1	2	1	2	2†	8*	88.0
Fair	0	0	1	0	0	1	6.7	0	0	0	0	0	0	0.0
Poor	1	2	2	1	5	11	73.3	0	1†	0	0	0	1	12.0
Totals	1	3	3	2	6	15	100.0	1	3	1	2	2	9	100.0

* Seven surgical cases had had failure of previous conservative treatment.

† One patient operated on twice: poor results after incomplete removal at first operation; good results after second.

Summary of Treatment in Children

On the basis of the results of treatment in children it would appear that the conservative treatment of ankle lesions was not so successful as that reported by Van Demark and Wiberg in knee lesions. Perhaps the duration of immobilization for those children in whom the talus was involved was not so long as that recommended by Van Demark; the duration was not recorded, although follow-up was listed in seven cases as varying from five months to twelve years. All of these patients had poor results.

In brief, the methods of treatment in children under sixteen years of age were productive of the same results as in adults; conservative treatment gave poor results, operative treatment gave good results.

Duration of Follow-up

The duration of the follow-up periods of treatment of these fractures was adequate to permit evaluation of the various methods of treatment employed. The periods of follow-up for the conservatively treated cases were approximately the same as for those treated surgically (Table IV).

The appraisal of results of treatment by clinical methods within a few months after treatment is open to challenge, no matter what method of treatment has been employed. All methods of treatment had in common some period of immobilization which would give at least temporary benefit; this in turn, if appraised too early, might be mistaken for a good final result. Furthermore, since some patients experienced long periods of complete freedom from symptoms only to have later recurrences, appraisal too early again might give false information. It is suggested that a period of two years of follow-up be designated as the minimal acceptable duration in future reports.

Roentgenographic Evaluation of Treatment

After all types of treatment, except that of removal of the fragment, the interpretation of follow-up roentgenograms does not present any problems not already encountered in the preliminary roentgenographic diagnosis of the lesion.

If the fragment has been removed, little information can be expected from postoperative roentgenograms as far as the progress of the crater is concerned (Table I). Filling of the crater by fibrous connective tissue could not be expected to show in the roentgenograms. Burr¹³ reported that the crater filled with bone in seven years.

The greatest value of the postoperative roentgenographic examination lies in the identification of residual small fragments as the cause of continuing symptoms.

LESIONS OF OTHER JOINTS

The lesions discussed in this paper, with the exception of the case described in Figure 13, pertained only to the talus. Although we have not performed anatomical experiments on joints other than the ankle, we believe that the conclusions reached in this study concerning the etiological mechanism and methods of treatment apply with equal accuracy to the lesions of osteochondritis dissecans that are found in other joints—particularly that of the medial condyle of the knee—and to fractures of the radial head.

SUMMARY

Detached osteochondral fragments from the dome of the talus have been described in orthopaedic publications by a variety of confusing terms. A clarification of this conflicting terminology is suggested.

We believe that the traumatic etiology of the lesion has been confirmed both clinically and experimentally. The problems of clinical and roentgenographic diag-

nosis are discussed and illustrated by case histories. Various forms of treatment are evaluated, and the prognosis appraised.

NOTE: We express our gratitude to the attending surgeons who permitted the incorporation in this report of the histories and roentgenograms of their cases: Dr. G. W. Bennett, Case 21; Dr. Robert R. Crawford, Case 7; Dr. William M. Davis, Case 3; Dr. Z. B. Friedenberg, Case 18; Dr. M. C. Goodman, Cases 14, 17, and 20; Dr. W. H. Hull, Case 12; Dr. A. W. Humphries, Cases 8 and 16; Dr. M. C. Kolczun, Case 5; Dr. J. T. Nicholson, Case 15; Dr. George S. Phalen, Cases 2, 6, 13, and 19; Dr. J. M. Strong and Dr. R. C. Novatny, Case 4; Dr. J. M. Strong and Dr. G. W. Bennett, Case 11; and Dr. J. F. Whitman, Case 10.

REFERENCES

1. ANDERSON, K. J., and LECOCQ, J. F.: Operative Treatment of Injury to the Fibular Collateral Ligament of the Ankle. *J. Bone and Joint Surg.*, **36-A**: 825-832, July 1954.
2. ARONSSON, HUGO: Über Osteochondritis dissecans im Fussgelenk. *Zentralbl. f. Chir.*, **69**: 312-323, 1942.
3. ASHHURST, A. P. C., and BROMER, R. S.: Classification and Mechanism of Fractures of the Leg Bones Involving the Ankle. Based on a Study of Three Hundred Cases from the Episcopal Hospital. *Arch. Surg.*, **4**: 51-129, 1922.
4. AXHAUSEN, G.: Zum Vorkommen des Abgrenzungsvorganges am Fussgelenk. *Zentralbl. f. Chir.*, **55**: 322-327, 1928.
5. BAILEY'S TEXTBOOK OF HISTOLOGY. Ed. 14. Edited by Wilfred M. Copenhaver and Dorothy M. Johnson. Baltimore, The Williams and Wilkins Co., 1958.
6. BARTH, ARTHUR: Die Entstehung und das Wachstum der freien Gelenkkörper. *Arch. f. Klin. Chir.*, **56**: 507-573, 1898.
7. BOSIEN, W. R.; STAPLES, O. S.; and RUSSELL, S. W.: Residual Disability following Acute Ankle Sprains. *J. Bone and Joint Surg.*, **37-A**: 1237-1243, Dec. 1955.
8. BOYD, H. B., and KNIGHT, R. A.: Fractures of the Astragalus. *Southern Med. J.*, **35**: 160-167, 1942.
9. BOYD, I. A.: The Histological Structure of the Receptors in the Knee-Joint of the Cat Correlated with Their Physiological Response. *J. Physiol.*, **124**: 476-488, 1954.
10. BREITLÄNDER, A.: Osteochondritis dissecans tali. *Arch. f. Klin. Chir.*, **148**: 149, 1927.
11. BREWER, B. J.: Flake Fracture of the Astragalus. Unpublished paper presented at the Annual Meeting of the American Medical Association, Section on Orthopaedic Surgery, New York, N. Y., June 3, 1953 [Abstract: *J. Bone and Joint Surg.*, **35-A**: 1038, Oct. 1953].
12. BRICKEY, P. A., and GROW, J. B.: Osteochondritis Dissecans. Report of Cases Involving Elbow, Ankle and Metatarsophalangeal Joints. *Am. J. Surg.*, **48**: 463-466, 1940.
13. BURR, R. C.: Osteochondritis Dissecans. *Canadian Med. Assn. J.*, **41**: 232-235, 1939.
14. CAMERON, B. M.: Osteochondritis Dissecans of the Ankle Joint. Report of a Case Simulating a Fracture of the Talus. *J. Bone and Joint Surg.*, **38-A**: 857-861, July 1956.
15. CLARK, W. E. LE G.: The Tissues of the Body: An Introduction to the Study of Anatomy. Ed. 3, p. 164. New York, Oxford Univ. Press, 1952.
16. COBEY, M. C.: Osteochondritis Dissecans of the Astragalus. *Mil. Surgeon*, **93**: 184-186, 1943.
17. COHEN, H. H.: Osteochondritis Dissecans of the Astragalus. *Bull. Hosp. Joint Dis.*, **4**: 86-91, 1943.
18. COLTART, W. D.: "Sprained Ankle". *British Med. J.*, **2**: 957-961, 1951.
19. COLTART, W. D.: "Aviator's Astragalus". *J. Bone and Joint Surg.*, **34-B**: 545-566, Nov. 1952.
20. CONWAY, F. M.: Osteochondritis Dissecans. Intra-articular Osseocartilaginous Loose Bodies. A Clinical Study Based Upon Ten Personally Observed Cases. *Ann. Surg.*, **99**: 410-431, 1934.
21. CONWAY, F. M.: Osteochondritis Dissecans. Description of the Stages of the Condition and Its Probable Traumatic Etiology. *Am. J. Surg.*, **38**: 691-699, 1937.
22. CORDES: Osteochondritis dissecans im Sprunggelenk. *Zentralbl. f. Chir.*, **54**: 1252, 1927.
23. DAWSON, C. W.: Osteochondritis Dissecans. A Discussion of Two Similar Lesions. *Arch. Surg.*, **46**: 635-638, 1943.
24. DEGINDER, W. L.: Osteochondritis Dissecans of the Talus. *Radiology*, **65**: 590-598, 1955.
25. DEUTSCHLÄNDER, CARL: Zur Kenntnis der gelenknahen Nekrosenherde im subchondralen Knochenmarkraum. *Zentralbl. f. Chir.*, **55**: 469-472, 1928.
26. DIAZ GARCIA, FRANCISCO: Un cas d'ostéochondrite juvénile de l'astragale. *Bull. et Mém. Soc. Nat. Chir.*, **54**: 986-988, 1928.
27. EBERHARD, THEODORE: Cited by Ray and Coughlin⁶⁶.
28. ESKESEN, BODIL: Rare Intra-articular Fracture of Talus. *Nordisk Med. (Hospitalstid)*, **16**: 3436-3438, 1942.
29. EVE, DUNCAN, JR., and SHARBER, TRIMBLE: Handbook on Fractures. St. Louis, The C. V. Mosby Co., 1947.
30. FAIRBANK, H. A. T.: Osteo-chondritis Dissecans. *British J. Surg.*, **21**: 67-82, 1933.
31. GARDINER, T. B.: Osteochondritis Dissecans in Three Members of One Family. *J. Bone and Joint Surg.*, **37-B**: 139-141, Feb. 1955.
32. GARDNER, ERNEST: The Innervation of the Knee Joint. *Anat. Rec.*, **101**: 109-130, 1948.
33. GREEN, W. T., and BANKS, H. H.: Osteochondritis Dissecans in Children. *J. Bone and Joint Surg.*, **35-A**: 26-47, Jan. 1953.
34. HARMS: Osteochondritis dissecans an der Talusrolle? *Zentralbl. f. Chir.*, **54**: 1017, 1927.
35. HELLSTRÖM, JOHN, and ÖSTLING, KARL: Ein klinischer Beitrag zur Kenntnis der Osteochondritis dissecans. *Acta Chir. Scandinavica*, **75**: 273-318, 1934.
36. HOFFMANN: Cited by Myhre⁶⁸.
37. HOLLANDER, J. L.: In Comroe's Arthritis and Allied Conditions. Ed. 5. Philadelphia, Lea and Febiger, 1953.

38. HOWORTH, M. B.: A Textbook of Orthopedics. With a Section on Neurology in Orthopedics. Philadelphia, W. B. Saunders Co., 1952.
39. HUTCHISON, R. G.: Osteochondritis Dissecans. Records of Some Unusual Cases. *British J. Radiol.*, **16**: 147-149, 1943.
40. JAMES, E. C.: Cited by Vaughan and Stapleton⁷⁵.
41. KAPIS, MAX: Weitere Beiträge zur traumatisch-mechanischen Entstehung der "spontanen" Knorpelablösungen (sogen. Osteochondritis dissecans). *Deutsche Zeitschr. f. Chir.* **171**: 13-29, 1922.
42. KLEIGER, BARNARD: Fractures of the Talus. *J. Bone and Joint Surg.*, **30-A**: 735-744, July, 1948.
43. KÖNIG, FRANZ: Ueber freie Körper in den Gelenken. *Deutsche Zeitschr. f. Chir.*, **27**: 90-109, 1888.
44. LAGOMARSINO, E. H.: Osteochondritis dissecans del astrágalo. *Rev. Ortop. y Traumatol.*, **13**: 221-226, 1944.
45. LAUGE-HANSEN, N.: Fractures of the Ankle. II. Combined Experimental-Surgical and Experimental-Röntgenologic Investigations. *Arch. Surg.*, **60**: 957-985, 1950.
46. LAVNER, GERALD: Osteochondritis Dissecans. An Analysis of Forty-two Cases and a Review of the Literature. *Am. J. Roentgenol.*, **57**: 56-70, 1947.
47. LÄWEN, A.: Über Osteochondritis dissecans am Talocruralgelenk und ihre operative Behandlung. *Zentralbl. f. Chir.*, **56**: 2498-2503, 1929.
48. LEWIS, R. W.: Less Common Lesions of the Astragalus. *Ann. Surg.*, **116**: 891-897, 1942.
49. LIPSCOMB, P. R., and GHORMLEY, R. K.: Old and New Fractures and Fracture-Dislocations of the Astragalus. *Surg. Clin. North America*, **23**: 995-1011, 1943.
50. MARKS, K. L.: Flake Fracture of the Talus Progressing to Osteochondritis Dissecans. *J. Bone and Joint Surg.*, **34-B**: 90-92, Feb. 1952.
51. MENSOR, M. C., and MELODY, G. F.: Osteochondritis Dissecans of Ankle Joint. The Use of Tomography as a Diagnostic Aid. *J. Bone and Joint Surg.*, **23**: 903-909, Oct. 1941.
52. MONRO, ALEXANDER: *Microgeologie*, p. 236. Berlin, Th. Billroth, 1856 [Cited by Barth⁴ and Phemister⁷⁶].
53. MYHRE, HELGE: On Osteochondritis Dissecans Trochleae Tali. *Acta Radiol.*, **20**: 272-275, 1939.
54. NISBET, N. W.: Dome Fracture of the Talus. *J. Bone and Joint Surg.*, **36-B**: 244-246, May 1954.
55. PÉREZ DUÑO, F.: Dos casos de osteocondritis de astrágalo. *Arch. Med. Cir. y Especialidad*, **36**: 639-642, 1933.
56. PHEMISTER, D. B.: The Causes of and Changes in Loose Bodies Arising from the Articular Surfaces of the Joint. *J. Bone and Joint Surg.*, **6**: 278-315, Apr. 1924.
57. PICK, M. P.: Familial Osteochondritis Dissecans. *J. Bone and Joint Surg.*, **37-B**: 142-145, Feb. 1955.
58. RADICKE, KURT: Operationsergebnisse bei Osteochondritis dissecans. *Beitr. z. Klin. Chir.*, **150**: 121-129, 1930.
59. RAY, R. B., and COUGHLIN, E. J.: Osteochondritis Dissecans of the Talus. *J. Bone and Joint Surg.*, **29**: 697-706, July 1947.
60. RENDU, ANDRÉ: Fracture intra-articulaire parcellaire de la poulie astragaliennne. *Lyon Méd.*, **150**: 220-222, 1932.
61. RIBBING, S.: Studien über hereditäre, multiple Epiphysenstörungen. *Acta Radiol., Supplementum* **34**: 1-107, 1937.
62. RÖDÉN, STURE; TILLEGÅRD, PAUL; and UNANDER-SCHARIN, LARS: Osteochondritis Dissecans Tali. *Nordisk Med.*, **45**: 324-325, 1951.
63. RÖDÉN, STURE; TILLEGÅRD, PAUL; and UNANDER-SCHARIN, LARS: Osteochondritis Dissecans and Similar Lesions of the Talus. Report of Fifty-five Cases with Special Reference to Etiology and Treatment. *Acta Orthop. Scandinavica*, **23**: 51-66, 1953.
64. ROESNER, E.: Die Entstehungsmechanik der sog. Osteochondritis dissecans am Kniegelenk. *Beitr. z. Klin. Chir.*, **127**: 537-561, 1922.
65. SCHNABERTH, KARL: Osteochondritis dissecans im unteren Sprunggelenk. *Zeitschr. f. Orthop. Chir.*, **69**: 186-191, 1939.
66. SCHOSSENER, WOLFGANG: Freier Gelenkkörper im oberen Sprunggelenk. *Zentralbl. f. Chir.*, **55**: 2256-2257, 1928.
67. SCHULTE-TENCKHOFF: Über einen freien Gelenkkörper des oberen Sprunggelenks. *Med. Klin.*, **25**: 871-872, 1929.
68. SIDLER, A.: Über Gelenkknorpellösung und Gelenkmausbildung im oberen Sprunggelenk. *Zeitschr. f. Orthop. Chir.*, **52**: 302-314, 1929.
69. SIMPSON, T. R.: A Case of Osteochondritis Dissecans of the Ankle. *British J. Surg.*, **37**: 359-360, 1950.
70. SOEUR, ROBERT: Ostéochondrite disséquante de la cheville. *Acta Orthop. Belgica*, **16**: 493-502, 1950.
71. SOEUR, ROBERT: L'ostéochondrite disséquante. Réactions de la membrane synoviale. *Rev. d'Orthop.*, **37**: 5-21, 1951.
72. VON STAA, H.: Zur Frage der Operation bei der Osteochondritis dissecans. *Arch. f. Klin. Chir.*, **161**: 281-308, 1930.
73. STEVENSON, G. H.: Loose Bodies in the Ankle-Joint. *British J. Surg.*, **12**: 611-612, Jan. 1925.
74. VAN DEMARK, R. E.: Osteochondritis Dissecans with Spontaneous Healing. *J. Bone and Joint Surg.*, **34-A**: 143-148, Jan. 1952.
75. VAUGHAN, C. E., and STAPLETON, J. G.: Osteochondritis Dissecans of the Ankle. With Reports of Four Proved Cases. *Radiology*, **49**: 72-79, 1947.
76. VOGEL, K.: Ein Fall von Knochenerweichung (Köhler, Kienböck u. a.) im Sprunggelenk. *Zentralbl. f. Chir.*, **54**: 2510-2512, 1927.

77. WAGONER, GEORGE, and COHN, B. N. E.: Osteochondritis Dissecans. A Résumé of the Theories of Etiology and the Consideration of Heredity as an Etiologic Factor. *Arch. Surg.*, **23**: 1-24, 1931.
78. WIBERG, GUNNAR: Spontanheilung von Osteochondritis dissecans im Kniegelenk. *Acta Chir. Scandinavica*, **85**: 421-431, 1941.
79. WIBERG, GUNNAR: Spontaneous Healing of Osteochondritis Dissecans in the Knee-Joint. *Acta Orthop. Scandinavica*, **14**: 270-277, 1943.
80. WILNER, DANIEL: Diagnostic Problems in Fractures of the Foot and Ankle. *Am. J. Roentgenol.*, **55**: 594-616, 1946.
81. WILSON, P. D.: Fractures and Dislocations of the Tarsal Bones. *Southern Med. J.*, **26**: 833-845, 1933.
82. WOLFF, A. O.: Osteochondritis dissecans i talocruralledgett. (*Dansk Radiol. Selskabs Forhandlingar 1925.*) *Hospitals Tidende*, 1926. [Cited by Rödén, Tillegård, and Unander-Scharin⁶³.]