

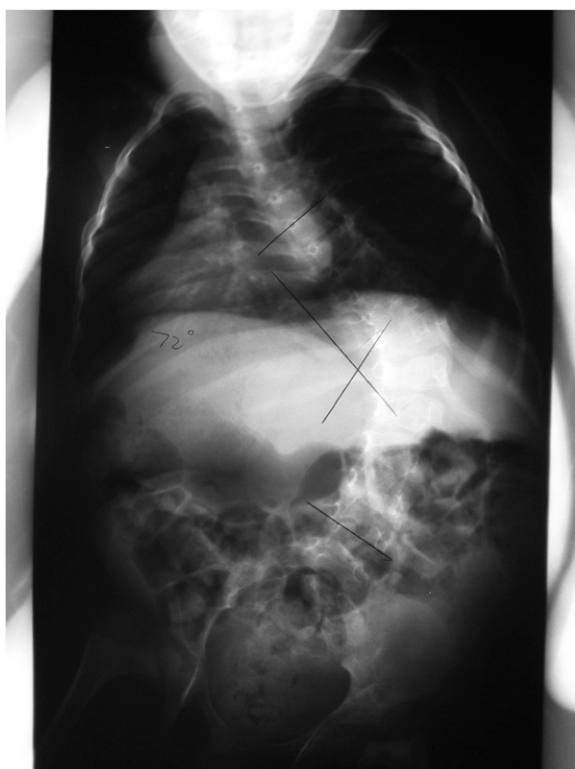

Fig. E1-A

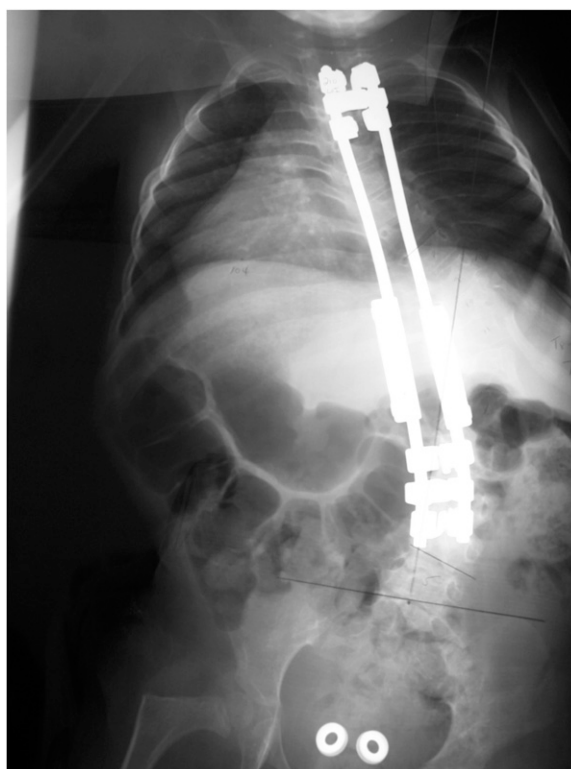


Fig. E1-B

Fig. E1-A Preoperative posteroanterior radiograph demonstrating an 82° scoliosis (T8-L4) in a three-year and eleven-month-old boy diagnosed with arthrogryposis. **Fig. E1-B** Posteroanterior radiograph after the initial implantation of growing-rod instrumentation, demonstrating a residual 60° scoliosis at the age of four years.

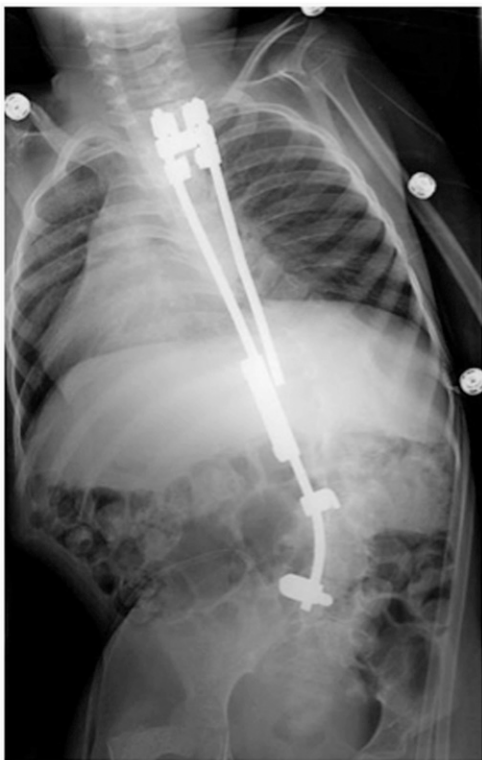


Fig. E1-C

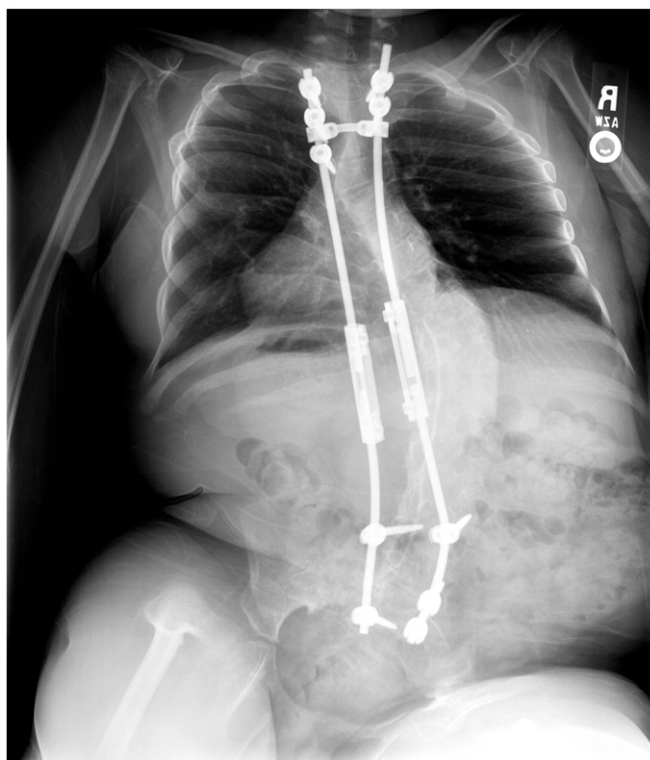


Fig. E1-D

Fig. E1-C Posteroanterior radiograph after partial removal of instrumentation to control a deep surgical site infection at the age of five years and nine months. **Fig. E1-D** Posteroanterior radiograph after eradication of the infection and reimplantation of instrumentation, to continue dual-growing-rod treatment, at the age of six and four months years.