

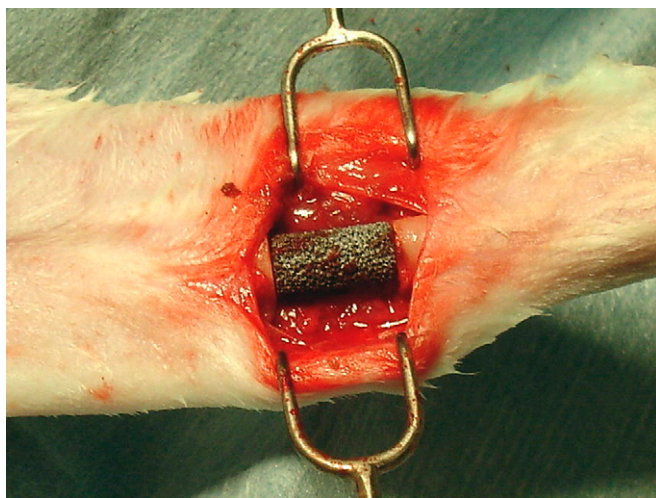Fig. E-1A

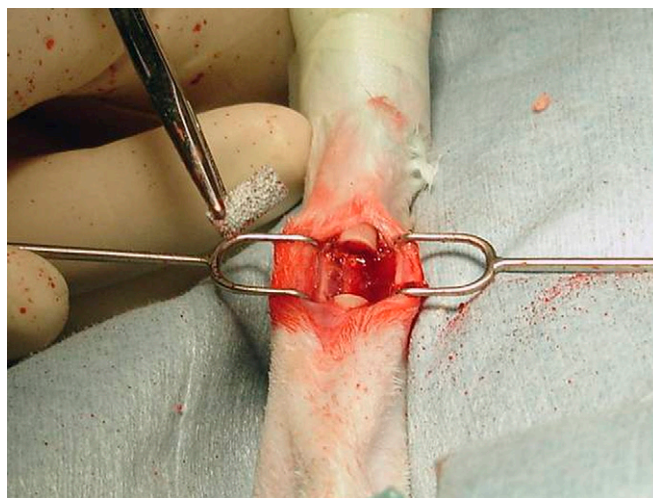


Fig. E-1B

Figs. E-1A and E-1B Photographs of the surgical sites prior to inoculation of the porous metal implants. **Fig. E-1A** The right radius with a control implant (no antibiotic microspheres attached) placed in the radial defect. **Fig. E-1B** A porous metal implant coated with antibiotic microspheres prior to placement in the contralateral osseous defect.