

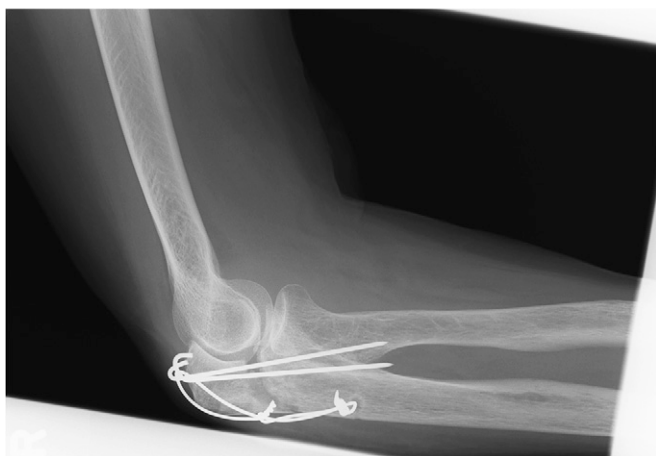Fig. E-1
Six-week postinjury lateral radiograph of the right elbow in an eighty-eight-year-old woman, demonstrating loss of reduction.

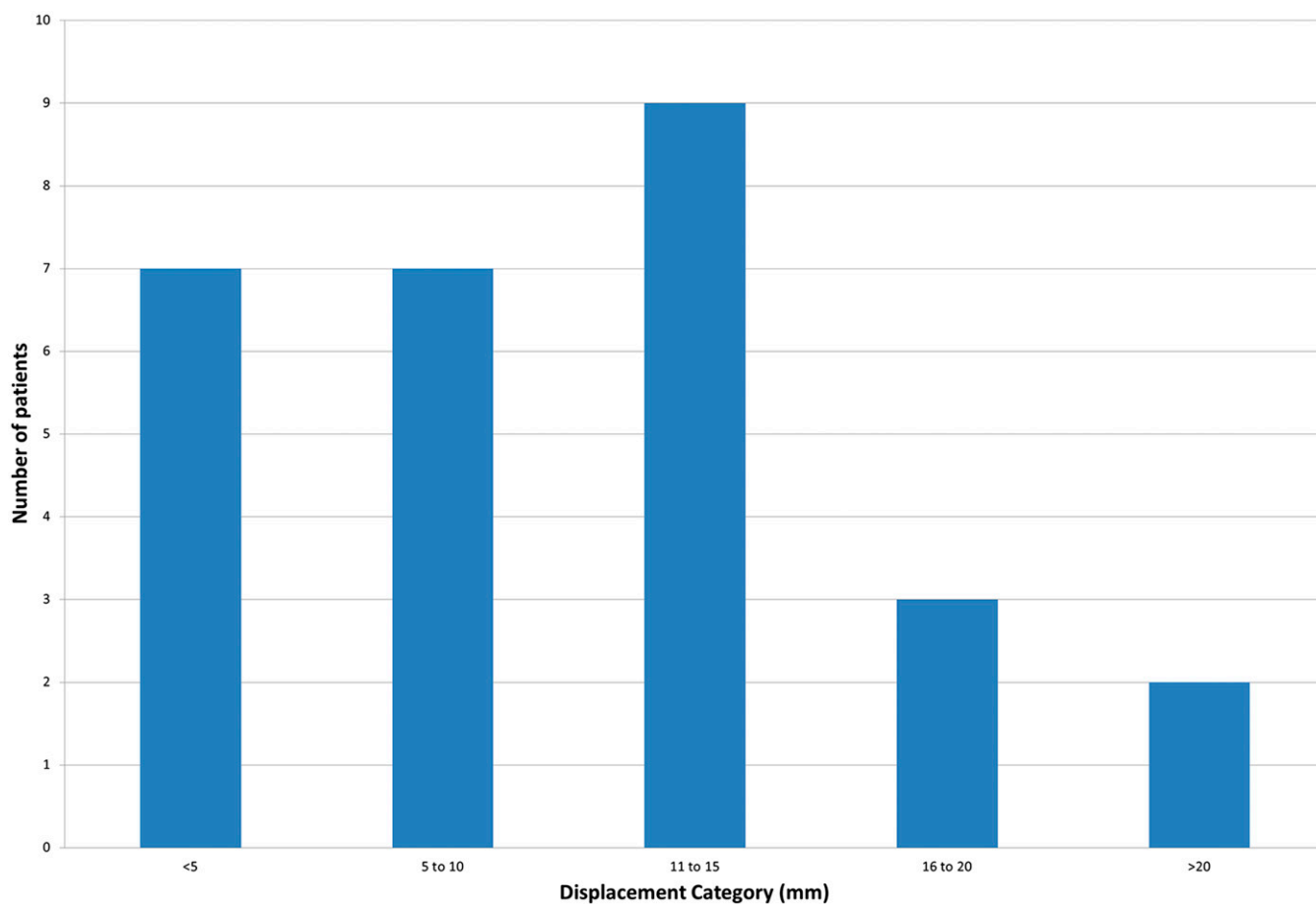


Fig. E-2
Categories of olecranon fracture displacement.