

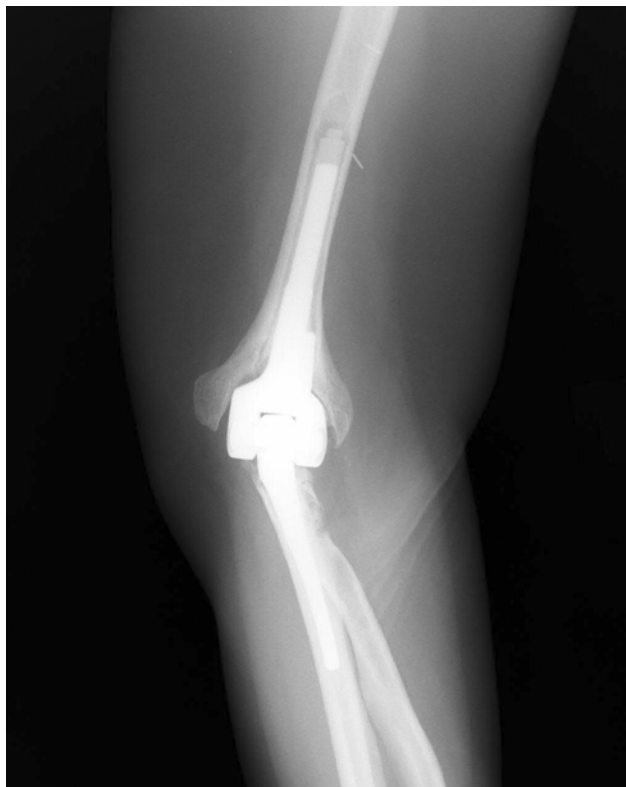

Fig. E1-A

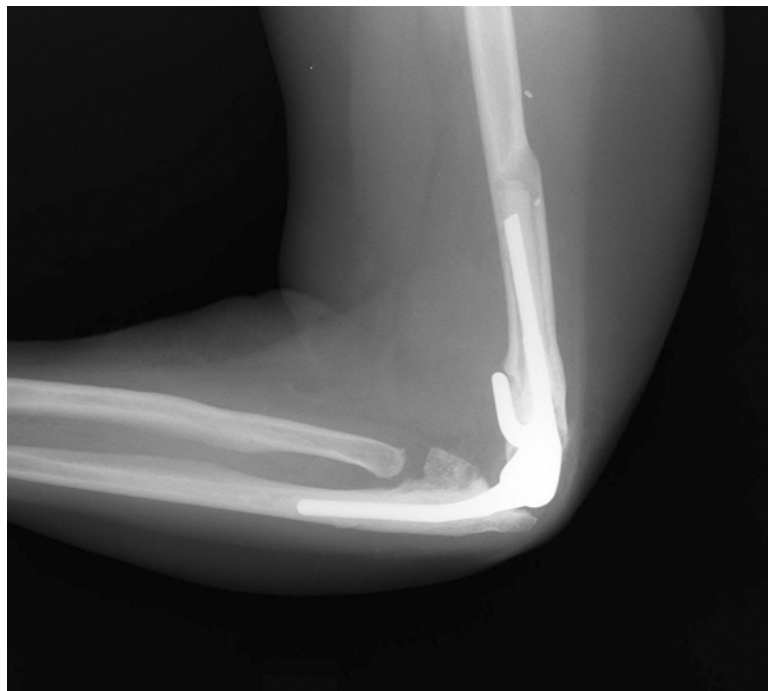


Fig. E1-B

Figs. E1-A through E1-F Case 16. Anteroposterior (**Fig. E1-A**) and lateral (**Fig. E1-B**) elbow radiographs showing suspicious early loosening of the humeral component two years after primary total elbow arthroplasty.

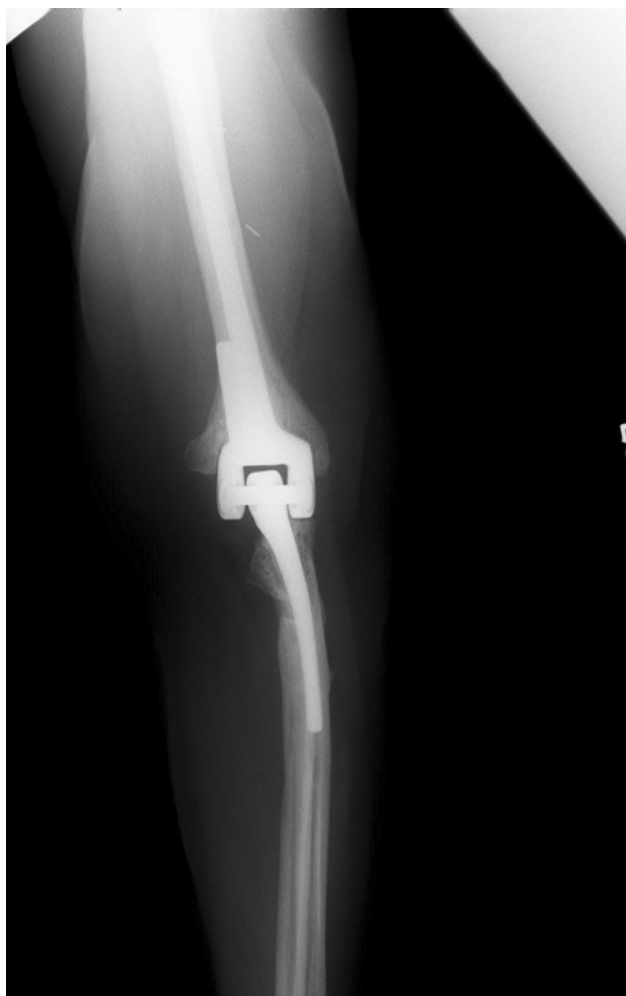

Fig. E1-C

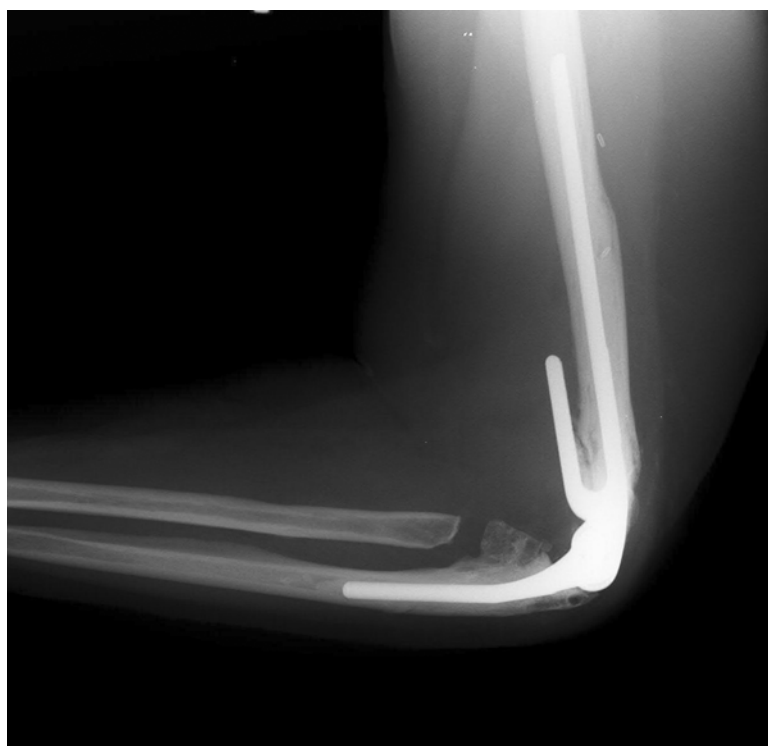


Fig. E1-D

Anteroposterior (**Fig. E1-C**) and lateral (**Fig. E1-D**) postoperative elbow radiographs made after index revision of the humeral component. Intraoperative culture yielded an unexpected growth of *Staphylococcus epidermidis*.

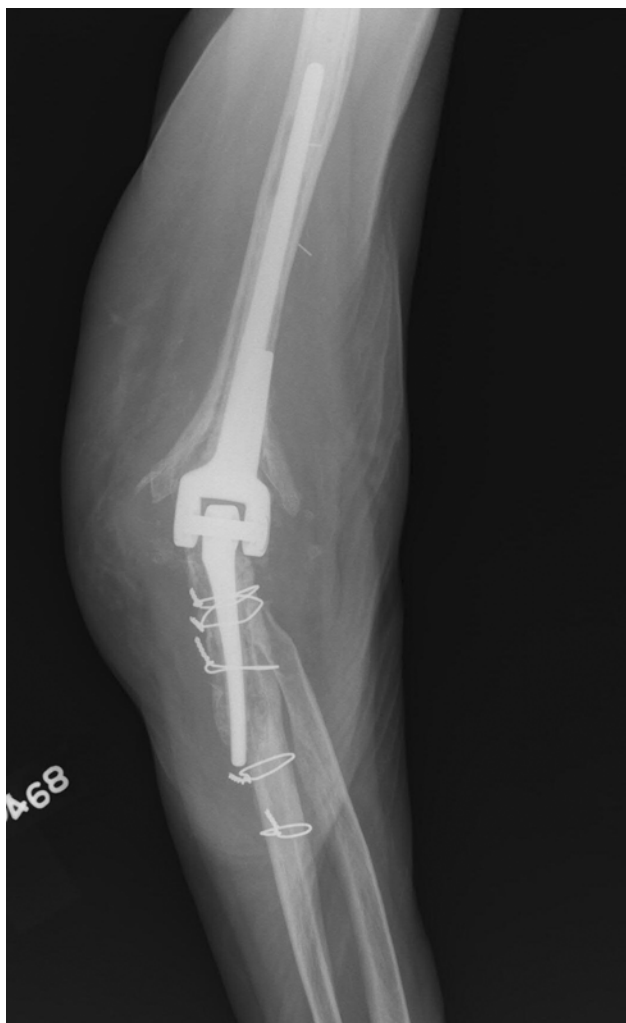

Fig. E1-E

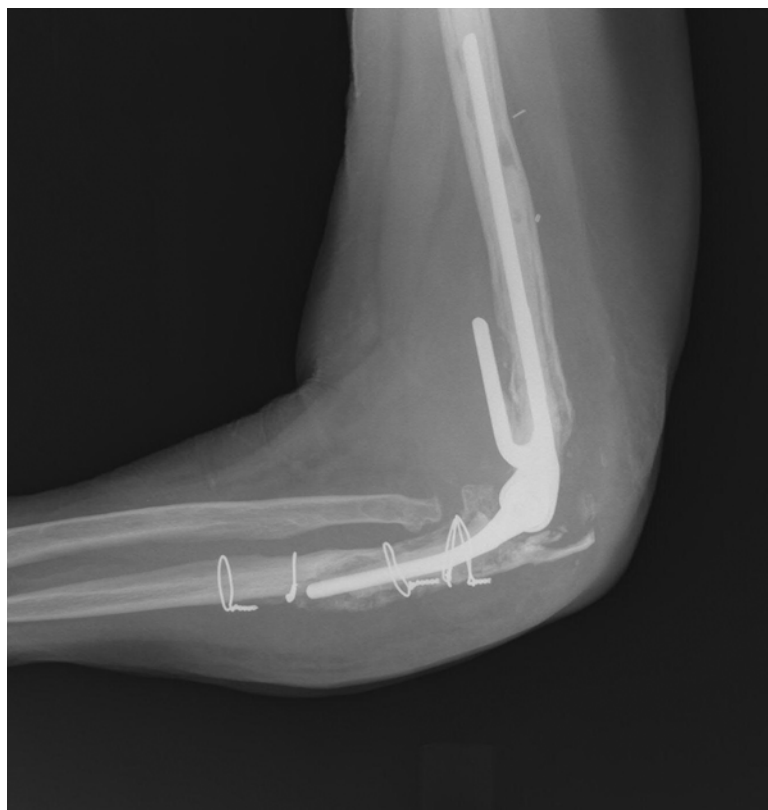

Fig. E1-F

Anteroposterior (**Fig. E1-E**) and lateral (**Fig. E1-F**) elbow radiographs made eight years after the index revision, showing repeat loosening of the pre-coated ulnar component. (The patient had a strut allograft fixation of the ulna to treat a periprosthetic fracture during the eight-year interim period.)