

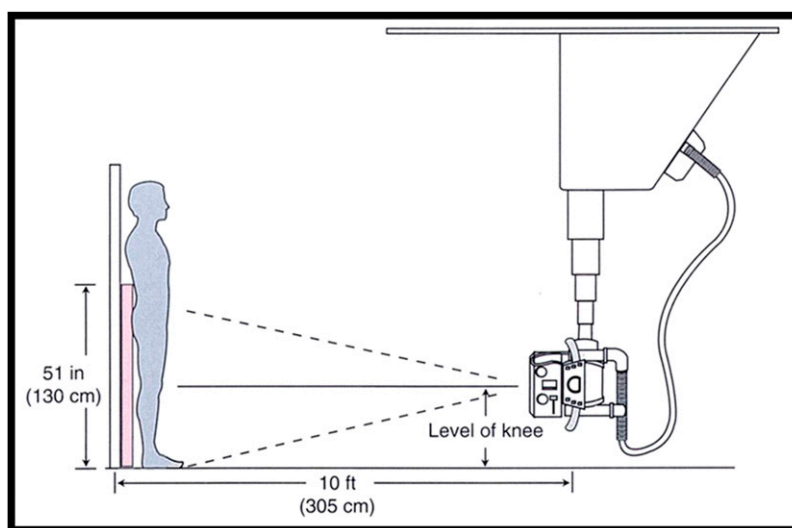Fig. E-1

Illustration of the conventional teleoroentgenogram setup. (Reproduced, with modification, from Paley D. Principles of deformity correction. Berlin: Springer-Verlag; 2012. Radiographic assessment of lower limb deformities; p 35. Reprinted with permission of Springer Science+Business Media.)



Fig. E-2

Photograph of the EOS scanner.

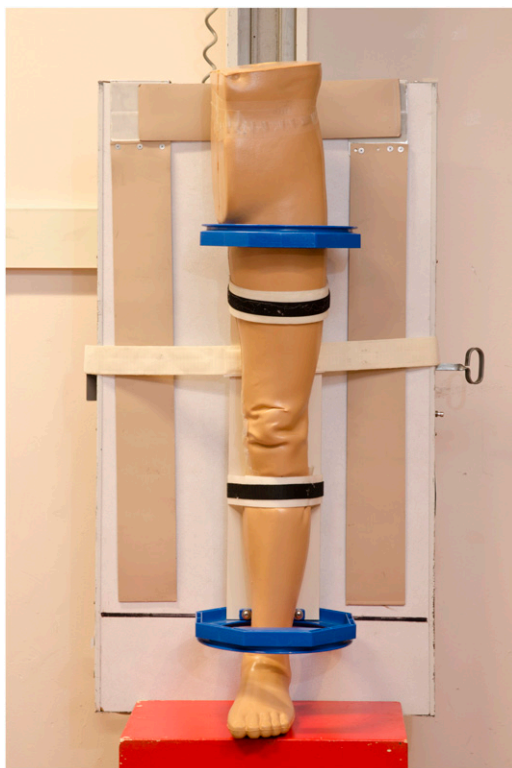


Fig. E-3A

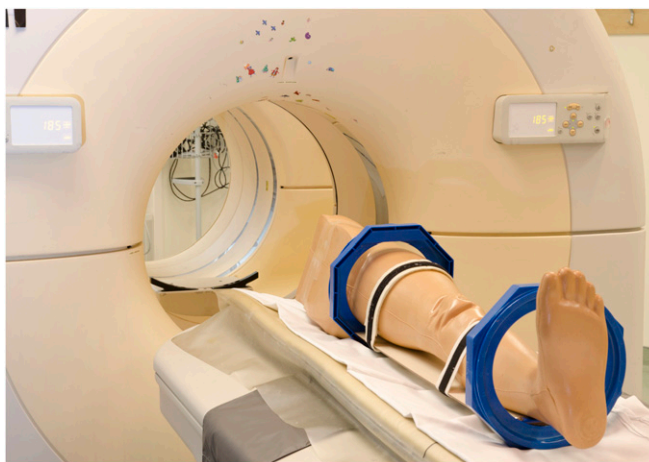

Fig. E-3B




Fig. E-3C

Fig. E-3A Photograph of a phantom limb setup for a teleoroentgenogram (conventional radiography). **Fig. E-3B** Photograph of a phantom limb setup for a CT scanogram. **Fig. E-3C** Photograph of a phantom limb setup for the EOS scanner.