

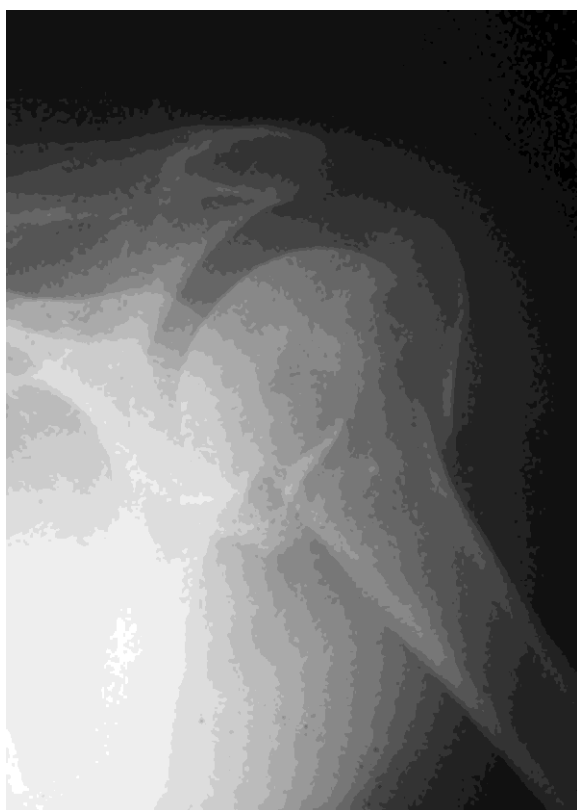

Fig. E-1A
Anteroposterior radiograph of the shoulder, showing the proximal humeral fracture.

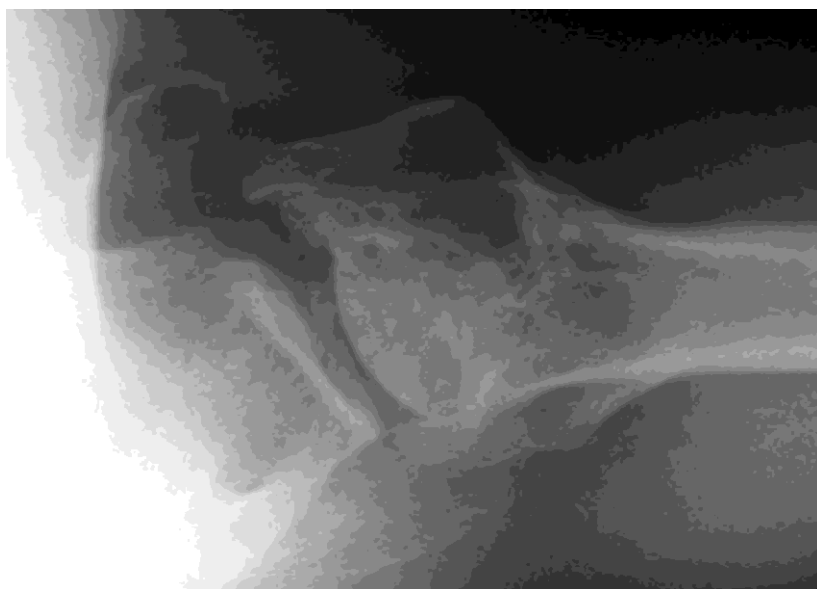


Fig. E-1B
Axillary radiograph showing the development of osteonecrosis in the healed shoulder after percutaneous fixation.

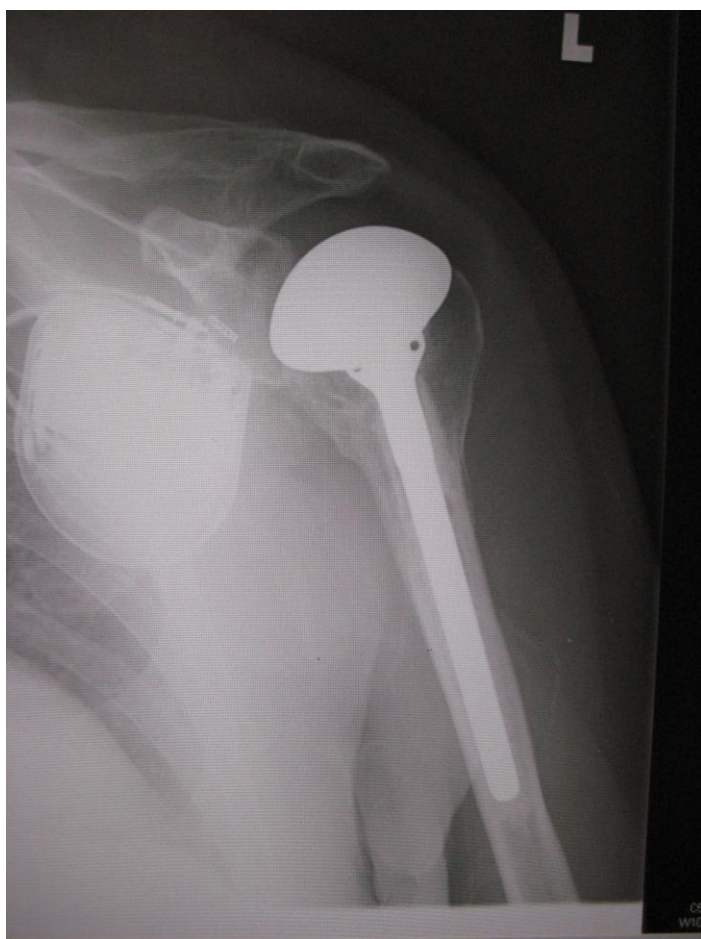


Fig. E-1C
Anteroposterior radiograph of the shoulder after hemiarthroplasty was performed to treat the osteonecrosis.

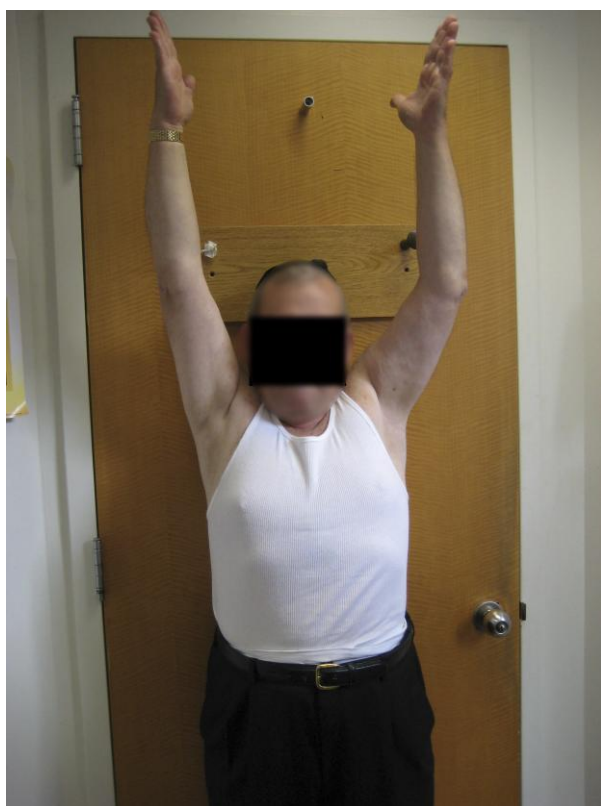

Fig. E-1D

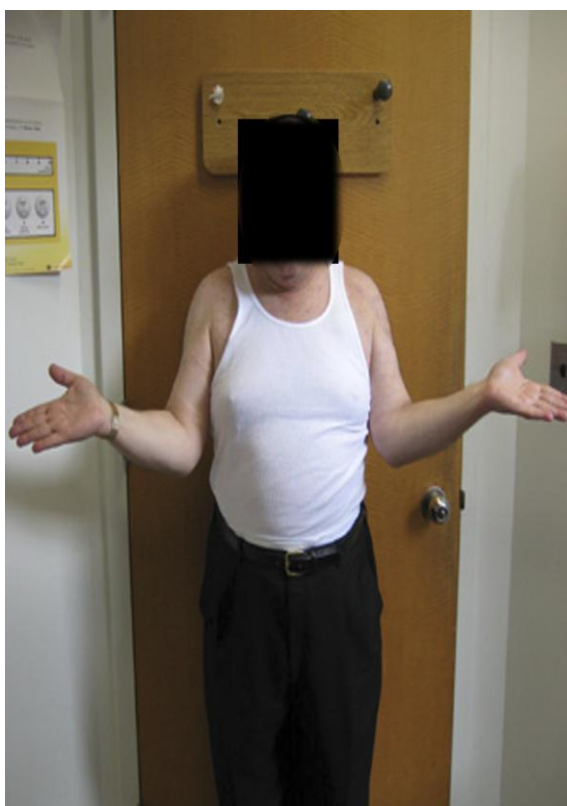

Fig. E-1E

Fig. E-1D and E-1E Clinical photographs showing recovery of shoulder motion after hemiarthroplasty of the left shoulder.