

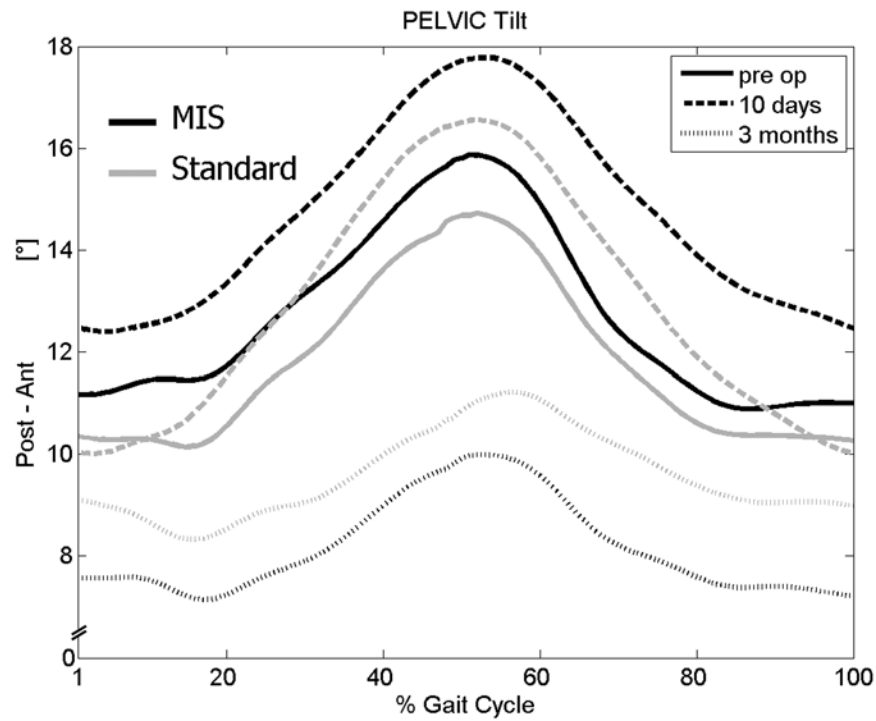Fig. E-1

Graph illustrating the mean pelvic motion in the sagittal plane during the gait cycle, with the typical anterior tilting at the end of the stance phase on the operatively treated side in both groups at any time point tested. MIS = minimally invasive surgery.

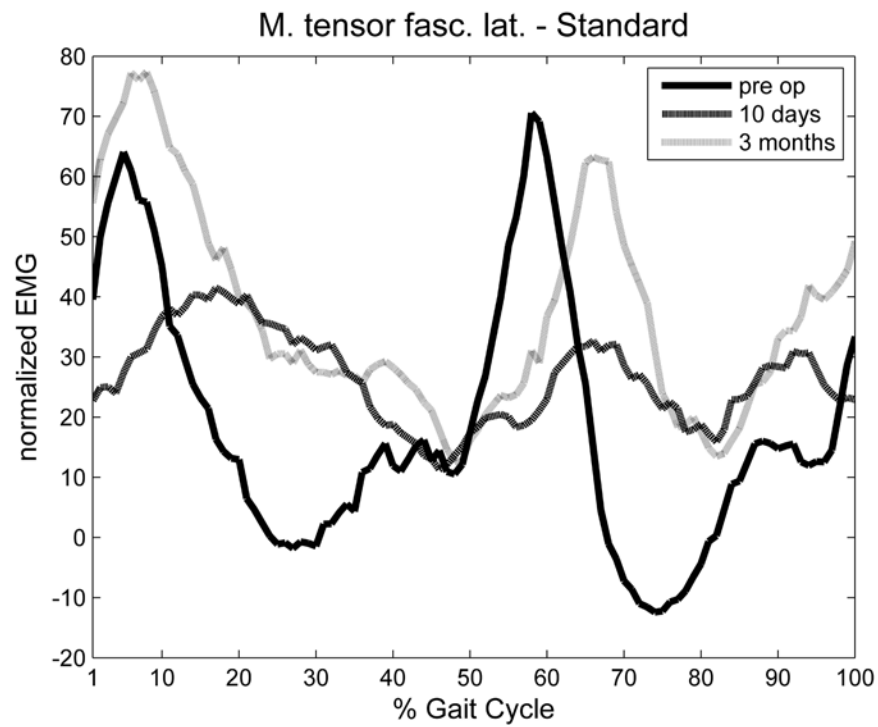


Fig. E-2
Graph illustrating abnormal prolongation of the activity of the tensor fasciae latae on the operatively treated side in a patient in the standard group. EMG = electromyography. M. tensor fasc. lat. = tensor fasciae latae.