

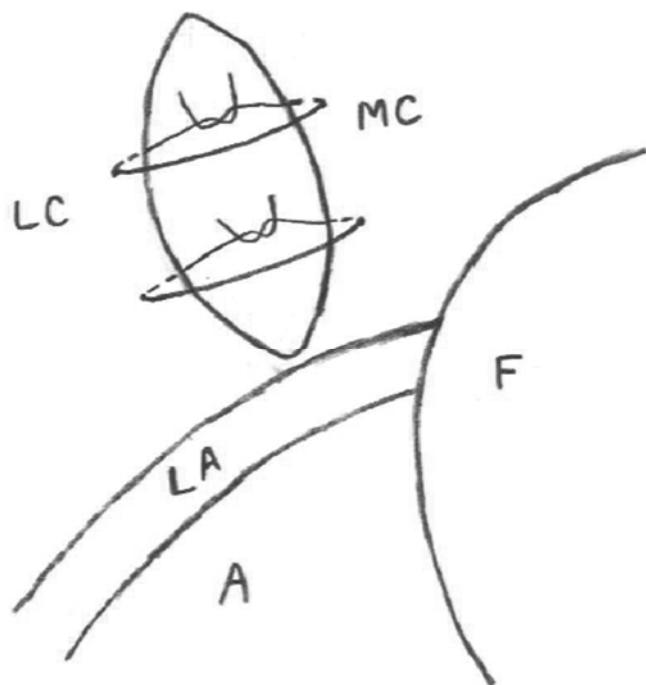Fig. E1-A

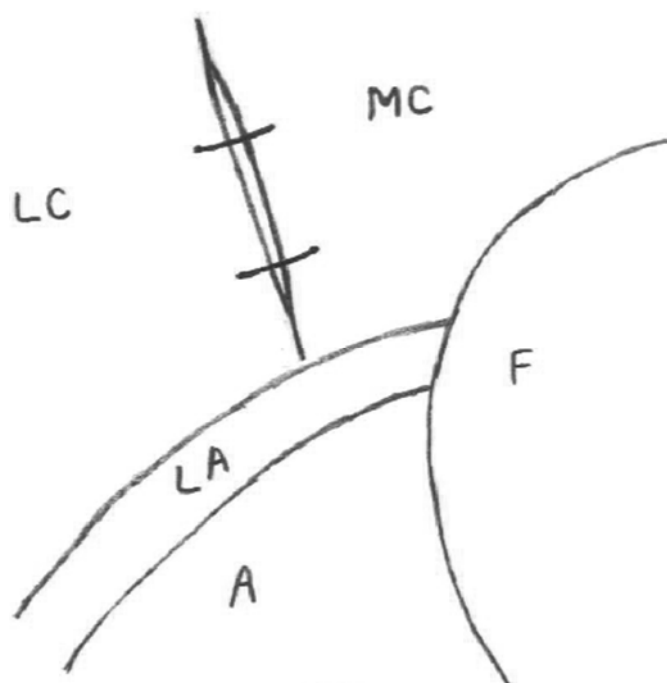


Fig. E1-B

**Figs. E1-A and E1-B** Schematic depicting the anterior capsular plication of the iliofemoral ligament after closure of the capsulectomy. **Fig. E1-A** Two sutures are passed from outside-in through the medial aspect of the iliofemoral ligament (in the medial capsule [MC]) and pulled back through the lateral aspect of the iliofemoral ligament (in the lateral capsule [LC]). **Fig. E1-B** The sutures are then tied, with the arthroscopic locking sliding knots in an extra-capsular position. LC = lateral capsule (iliofemoral ligament), MC = medial capsule (iliofemoral ligament), LA = labrum, F = femoral head, and A = acetabulum.

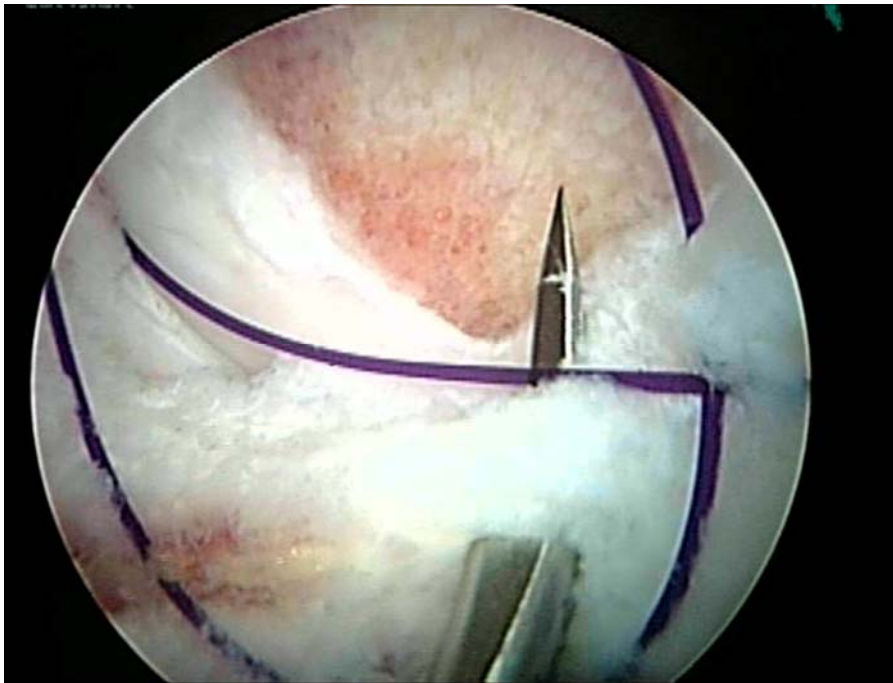


Fig. E2-A

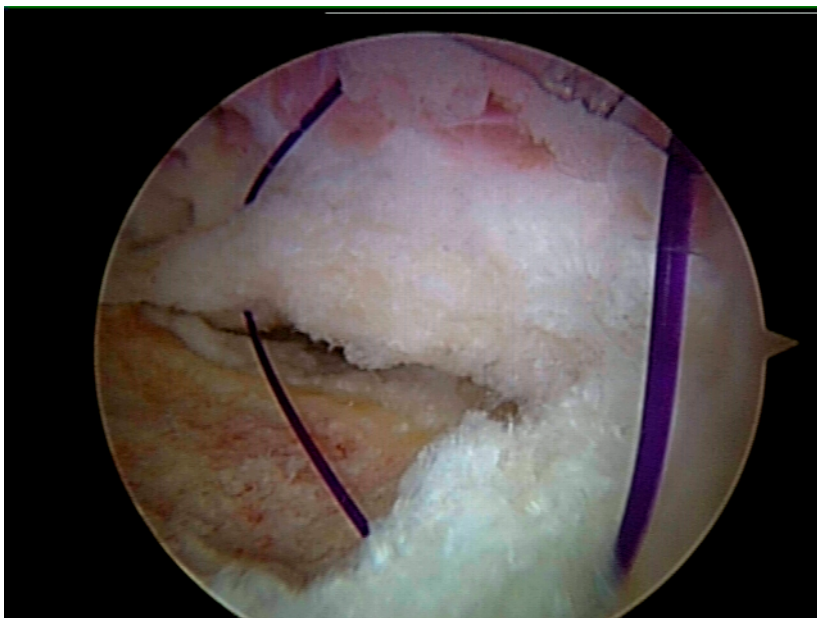

Fig. E2-B

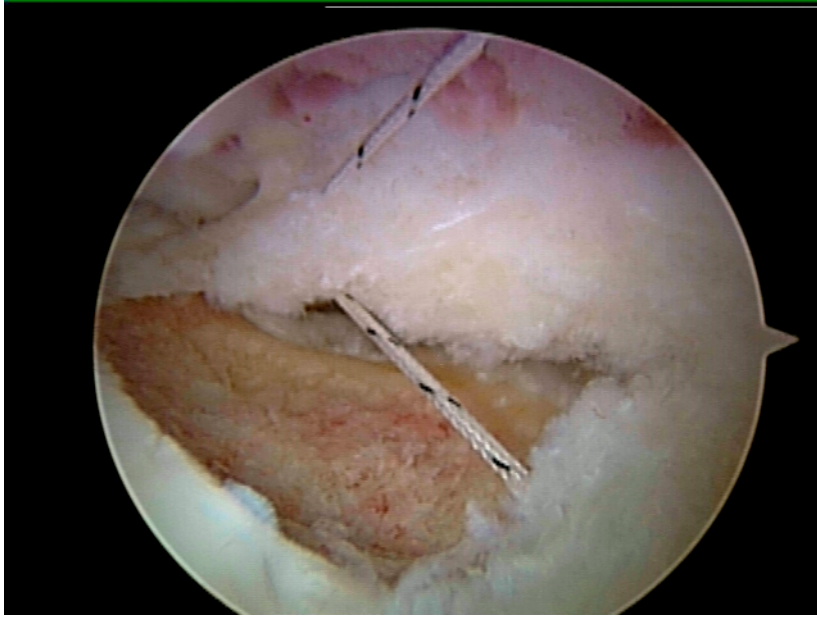


Fig. E2-C

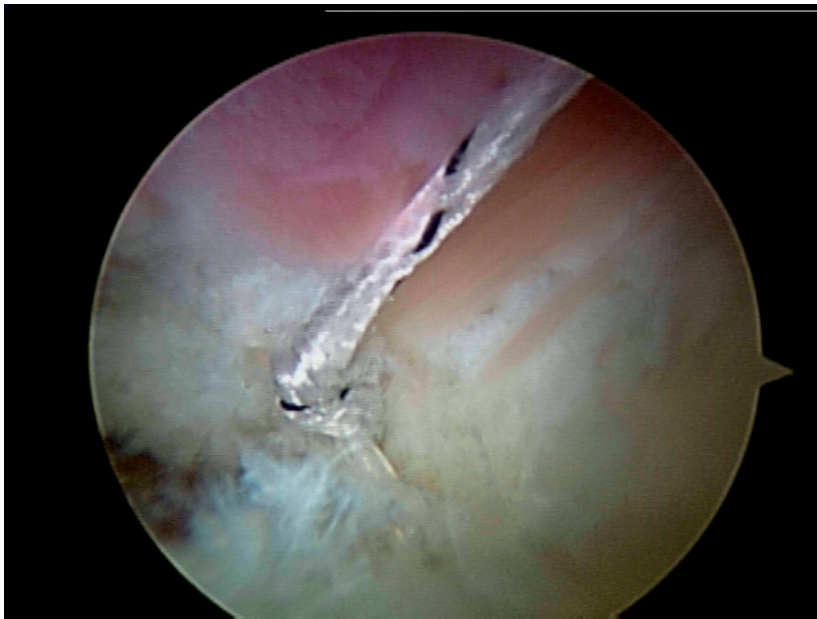

Fig. E2-D

**Figs. E2-A through E2-D** Peripheral compartment capsular plication performed without traction and with the hip in 30° of flexion. **Fig. E2-A** First, an 8.25-mm × 9-cm cannula (Arthrex) is placed through the anterior portal. The arthroscope is then placed in the anterolateral portal and the camera is directed proximally and anteriorly as the soft-tissue penetrator (Spectrum Suture Hook; Linvatec, Largo, Florida) is passed through the cannula and is used to shuttle a number-1 PDS (polydioxanone) suture (Ethicon, Somerville, New Jersey) through the medial limb of the iliofemoral ligament. Next, a soft-tissue penetrator-grasper (BirdBeak; Arthrex) is inserted through the cannula to penetrate the lateral aspect of the iliofemoral ligament tear and grasp the free end of the PDS suture. **Fig. E2-B** The PDS suture is then pulled through the lateral limbs of the iliofemoral ligament capsule and withdrawn through the cannula. The PDS suture is then incorporated into both limbs of the plication. **Fig. E2-C** The PDS suture is then used to shuttle a FiberWire suture (Arthrex) through the medial and lateral limbs of the iliofemoral ligament. **Fig. E2-D** The medial and lateral limbs of the plication are brought together with an arthroscopic knot, closing and tightening the iliofemoral ligament in a medial-to-lateral direction.