

## Appendix 1

### *Tanner-Whitehouse-III Descriptions*<sup>3</sup>

#### **First Metacarpal**

**Stage F:** The differentiation of the proximal surface into palmar and dorsal portions is now distinct, and the full extent of the dorsal surface can be made out; because of the rotation of the thumb in its position on the radiograph, these surfaces appear as laterodorsal and mediopalmar. The saddle formed by these surfaces conforms to the adjacent border of the trapezium bone. (Toward the end of this stage, the medial border of the epiphysis changes from a rounded shape to a flat, distinct border.)

**Stage G:** The epiphysis caps the metaphysis on one or both sides; the capping is usually seen better on the medial than on the lateral side because of the rotation of the thumb in positioning the hand.

**Stage H:** Fusion of the epiphysis and metaphysis has begun. A line is still visible, composed partly of black areas where the epiphyseal cartilage remains and partly of dense white areas where fusion has occurred.

**Stage I:** Fusion of the epiphysis and metaphysis is completed. (Over the majority of its length, the line of fusion has entirely disappeared, but some thickened remnant of it may still be visible.)

#### **Third and Fifth Metacarpals**

**Stage F:** It is now possible, on a good radiograph, to distinguish the palmar from the dorsal surface of the epiphysis. Since the last stage, the medial and/or lateral edges of the dorsal surface have grown outward to overlap the palmar surface of the epiphysis. The outlines of the palmar edges now appear as longitudinal thickened white lines.

**Stage G:** The epiphysis is as wide as, or wider than, the metaphysis. (This stage seems to be the equivalent of the stage of capping in the epiphysis of the phalanges.)

**Stage H:** Fusion of the epiphysis and metaphysis has begun. The dark line of cartilage extends over less than three-quarters of the bone's breadth but is not entirely obliterated.

**Stage I:** Fusion of the epiphysis and metaphysis is completed. (Over the majority of its length, the line of fusion has entirely disappeared, but some thickened remnant of it may still be visible.)

#### **Proximal Phalanx of the Thumb**

**Stage F:** The epiphysis is wider than the metaphysis, particularly at the medial side, and closely follows its shape.

**Stage G:** The epiphysis caps the metaphysis. (The capping is seen better on the medial than on the lateral side.)

**Stage H:** Fusion of the epiphysis and metaphysis has begun.

**Stage I:** Fusion of the epiphysis and metaphysis is completed. (Over the majority of its length, the line of fusion has entirely disappeared, but some thickened remnant of it may still be visible.)

#### **Proximal Phalanges of the Third and Fifth Digits**

**Stage F:** The epiphysis is as wide as the metaphysis and closely follows its shape, although it does not yet cap it at the edges.

**Stage G:** The epiphysis caps the metaphysis.

**Stage H:** Fusion of the epiphysis and metaphysis has now begun. A line is still visible, composed partly of black areas where the epiphyseal cartilage remains and partly of dense white areas where fusion is proceeding.

**Stage I:** Fusion of the epiphysis and metaphysis is completed. (Over the majority of its length, the line of fusion has entirely disappeared, but some thickened remnant of it may still be visible.)

#### **Middle Phalanges of the Third and Fifth Digits**

**Stage F:** The epiphysis is as wide as the metaphysis.

**Stage G:** The epiphysis caps the metaphysis.

**Stage H:** Fusion of the epiphysis and metaphysis has now begun. A line is still visible, composed partly of black areas where the epiphyseal cartilage remains and partly of dense white areas where fusion is proceeding.

**Stage I:** Fusion of the epiphysis and metaphysis is completed. (Over the majority of its length, the line of fusion has entirely disappeared, but some thickened remnant of it may still be visible.)

#### **Distal Phalanx of the Thumb**

**Stage F:** (i) The proximolateral border of the epiphysis is now concave and shapes to the head of the proximal phalanx. (In some positions of the thumb, this border is not visible as such. Instead, the articular surface may be seen as a white concave line inside the proximolateral border.) (ii) On the distal border, the medial and lateral surfaces can both be seen, with the base of the terminal phalanx conforming to the saddle shape between them. (iii) The epiphysis is now wider than the metaphysis.

**Stage G:** The epiphysis caps the metaphysis. (Because of the position of the thumb, this is better seen on the medial side.)

**Stage H:** Fusion of the epiphysis and metaphysis has now begun. A line is still visible, composed partly of black areas where the epiphyseal cartilage remains and partly of dense white areas where fusion is proceeding.

**Stage I:** Fusion of the epiphysis and metaphysis is completed. (Over the majority of its length, the line of fusion has entirely disappeared, but some thickened remnant of it may still be visible.)

### Distal Phalanges of the Third and Fifth Digits

**Stage F:** Palmar and dorsal proximal surfaces are distinct, and each has shaped to the trochlear articulation of the middle phalanx. The palmar surface appears as a projection proximal to the thickened white line representing the dorsal surface.

**Stage G:** The epiphysis caps the metaphysis.

**Stage H:** Fusion of the epiphysis and metaphysis has now begun. A line is still visible, composed partly of black areas where the epiphyseal cartilage remains and partly of dense white areas where fusion is proceeding.

**Stage I:** Fusion of the epiphysis and metaphysis is completed. (Over the majority of its length, the line of fusion has entirely disappeared, but some thickened remnant of it may still be visible.)

#### *Tanner-Whitehouse-III Schematic Figures*

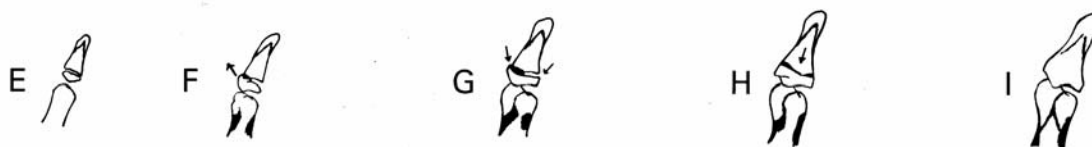

Fig. E1-1

Distal phalangeal stages of the thumb. The arrows show the epiphysis wider than the metaphysis on F, the capping on G, and the early central fusion on H. (Reprinted, with permission, from: Tanner JM, Healy MJR, Goldstein H, Cameron N. Assessment of skeletal maturity and prediction of adult height (TW3 method). 3rd ed. London: Saunders; 2001.)

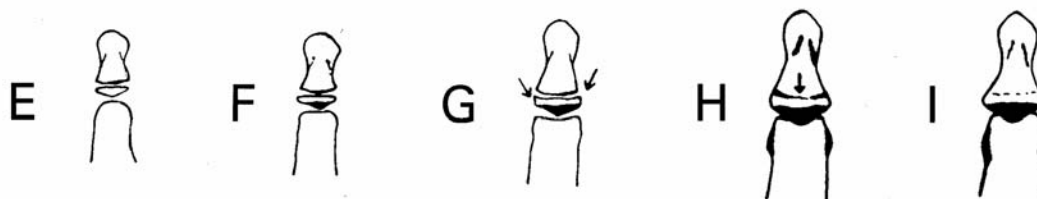


Fig. E1-2

Distal phalangeal stages of the fingers. The arrows show the capping on G and the early central fusion on H. (Reprinted, with permission, from: Tanner JM, Healy MJR, Goldstein H, Cameron N. Assessment of skeletal maturity and prediction of adult height (TW3 method). 3rd ed. London: Saunders; 2001.)

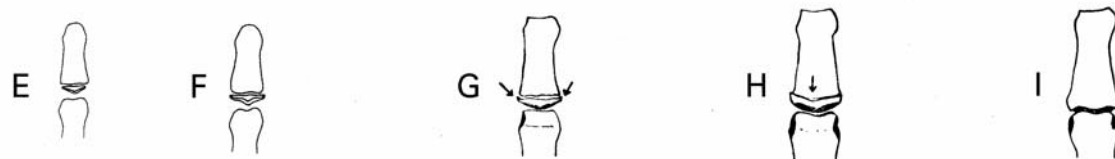


Fig. E1-3

Middle phalangeal stages of the fingers. The arrows show the capping on G and the early central fusion on H. (Reprinted, with permission, from: Tanner JM, Healy MJR, Goldstein H,

Cameron N. Assessment of skeletal maturity and prediction of adult height (TW3 method). 3rd ed. London: Saunders; 2001.)

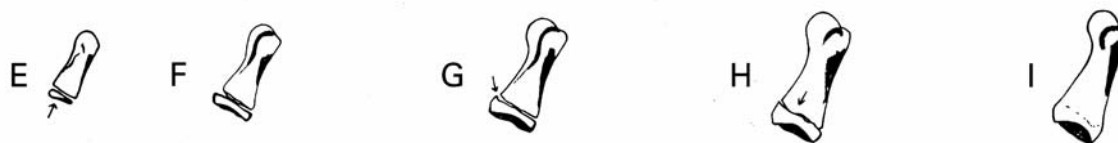

Fig. E1-4

Proximal phalangeal stages of the thumb. The arrows show the concave proximal border on E, the capping on G, and the early central fusion on H. (Reprinted, with permission, from: Tanner JM, Healy MJR, Goldstein H, Cameron N. Assessment of skeletal maturity and prediction of adult height (TW3 method). 3rd ed. London: Saunders; 2001.)



Fig. E1-5

Proximal phalangeal stages of the fingers. The arrows show the concave proximal borders on E and F, the capping on G, and the early central fusion on H. (Reprinted, with permission, from: Tanner JM, Healy MJR, Goldstein H, Cameron N. Assessment of skeletal maturity and prediction of adult height (TW3 method). 3rd ed. London: Saunders; 2001.)

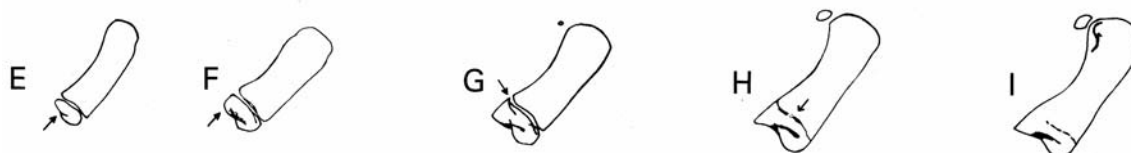

Fig. E1-6

Proximal metacarpal stages of the thumb. The arrows show the concave proximal border on E, the distinct two proximal surfaces on F, the capping on G, and the early central fusion on H. (Reprinted, with permission, from: Tanner JM, Healy MJR, Goldstein H, Cameron N. Assessment of skeletal maturity and prediction of adult height (TW3 method). 3rd ed. London: Saunders; 2001.)

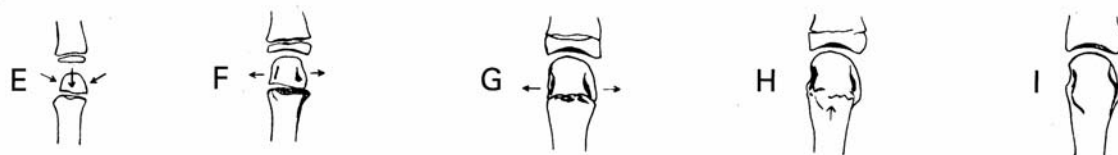


Fig. E1-7

Metacarpal stages of the fingers. The arrows show the distinct spade shape of the epiphysis compared with earlier stages for E, the outward growth of the epiphysis on F, the epiphysis as wide or wider than the metaphysis on G, and the early central fusion on H. (Reprinted, with permission, from: Tanner JM, Healy MJR, Goldstein H, Cameron N. Assessment of skeletal maturity and prediction of adult height (TW3 method). 3rd ed. London: Saunders; 2001.)

## Appendix 2

### *Self-Assessment Answers and Comments*

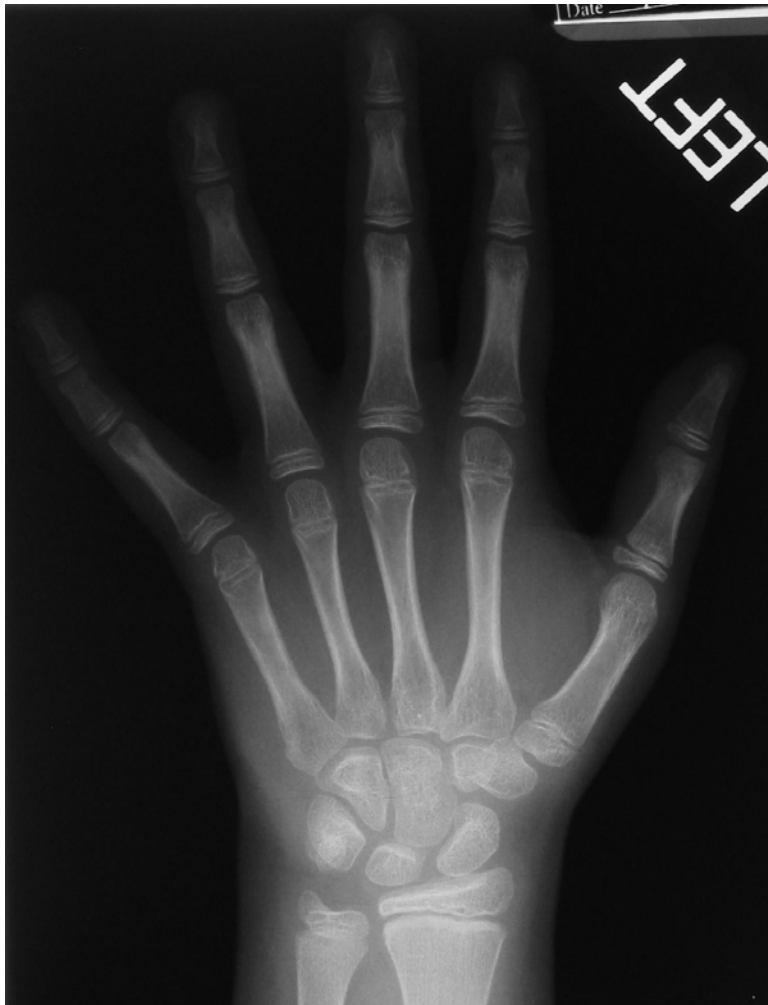

Fig. E2-1  
Preadolescent slow (stage 2). All of the epiphyses are as wide as the metaphyses.

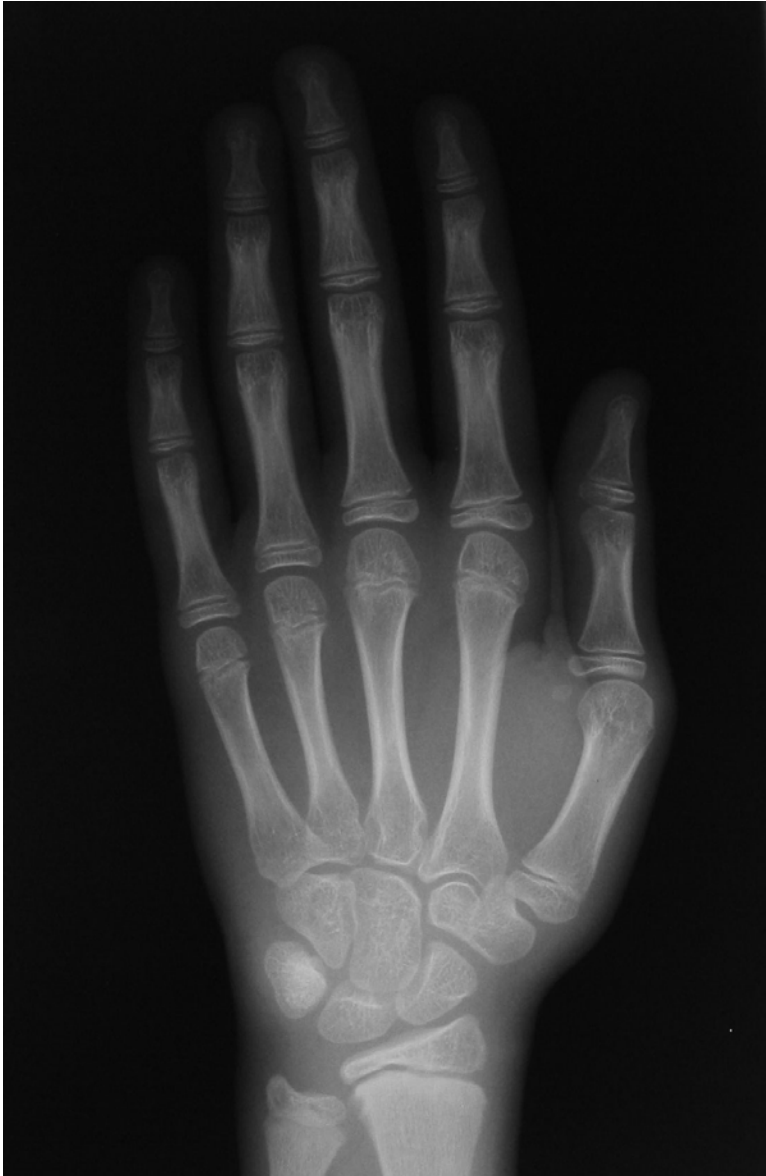

Fig. E2-2

Preadolescent slow (stage 2). While all of the epiphyses are as wide as the metaphyses, there is very little capping. The metacarpal heads are not wider than the metaphyses and the dorsal and palmar articular surfaces are not clear.

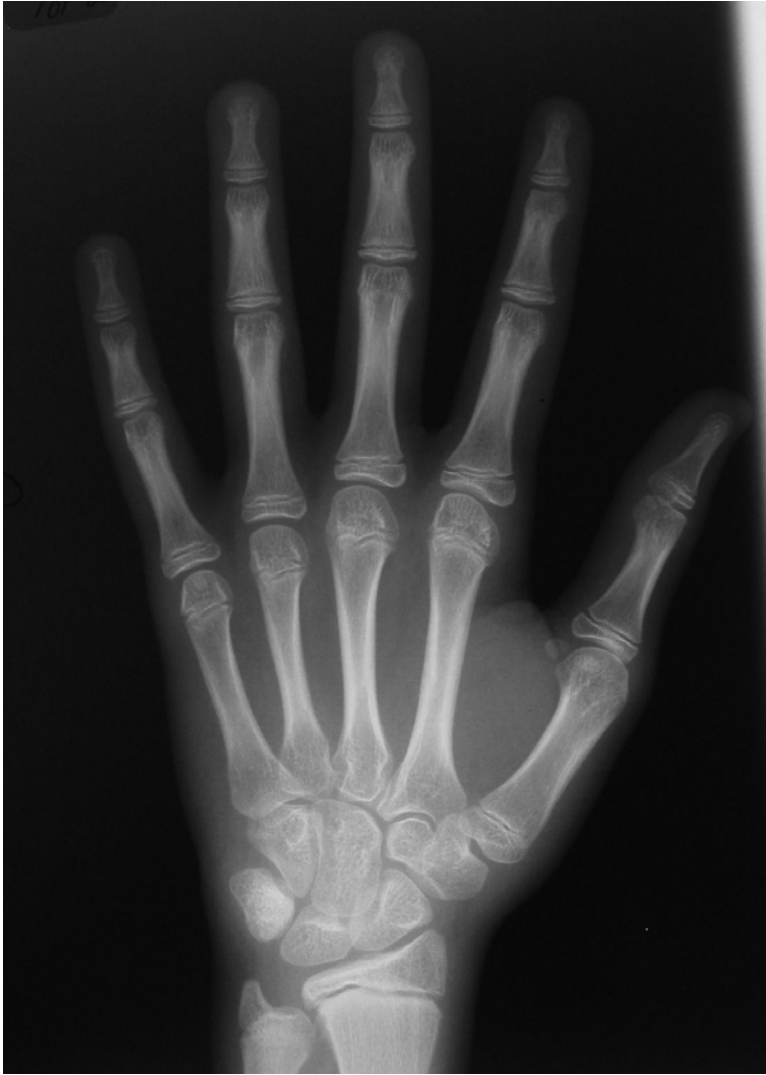

Fig. E2-3

Adolescent rapid—early (stage 3). All of the epiphyses appear capped. The proximal phalanges all curl to match the metaphyses. The metacarpal heads are now wider than the metaphyses with clear dorsal and palmar surfaces. The middle phalanges are curling up at the ends.

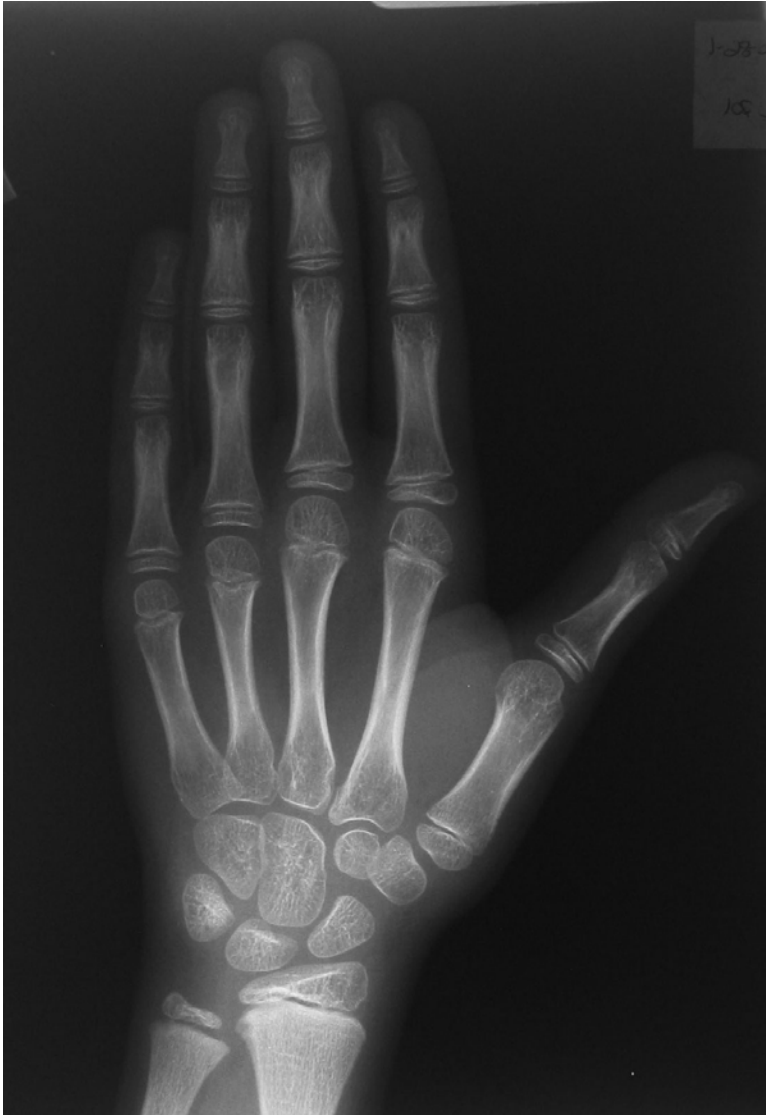

Fig. E2-4

Juvenile slow (stage 1). The metacarpal heads are not as wide as the metaphyses, and neither are the proximal phalangeal epiphyses. This is clearly the case on the ulnar side of the hand. In these early stages, the ulnar side is often delayed compared with the radial side.



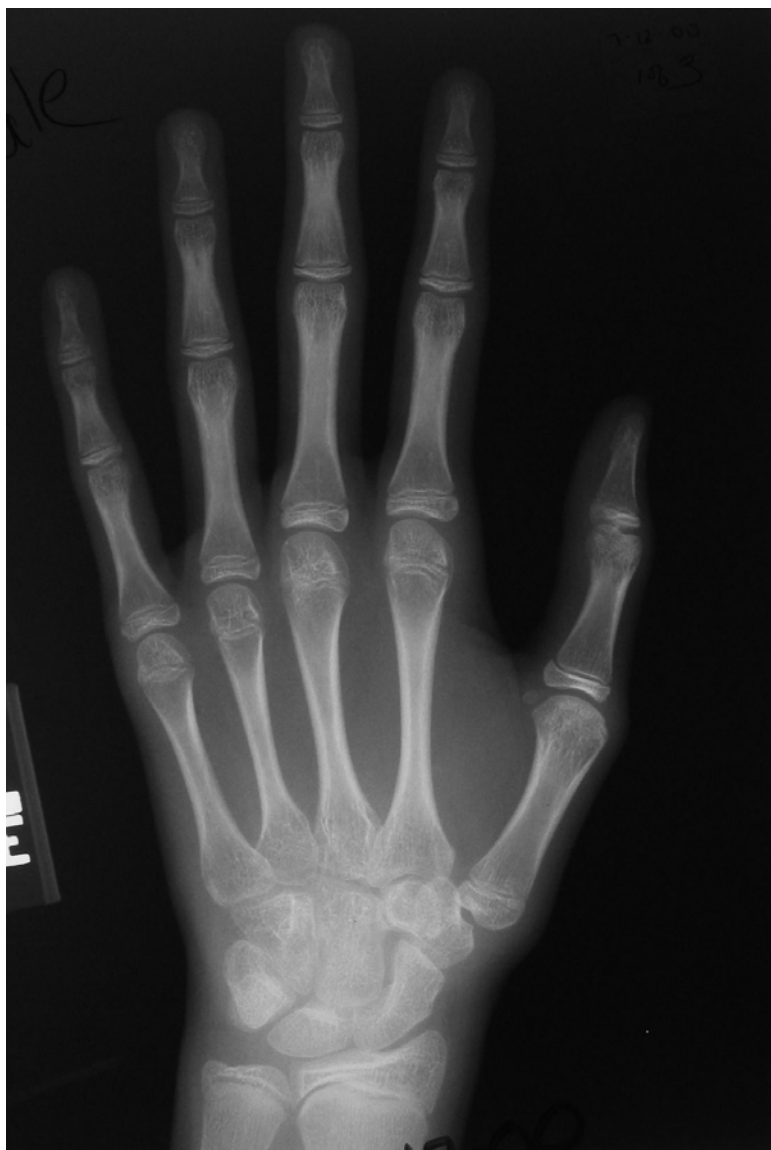

Fig. E2-5

Adolescent rapid—early (stage 3). Even the distal phalanges are clearly capping. There is no clear early fusion of the distal phalanges.

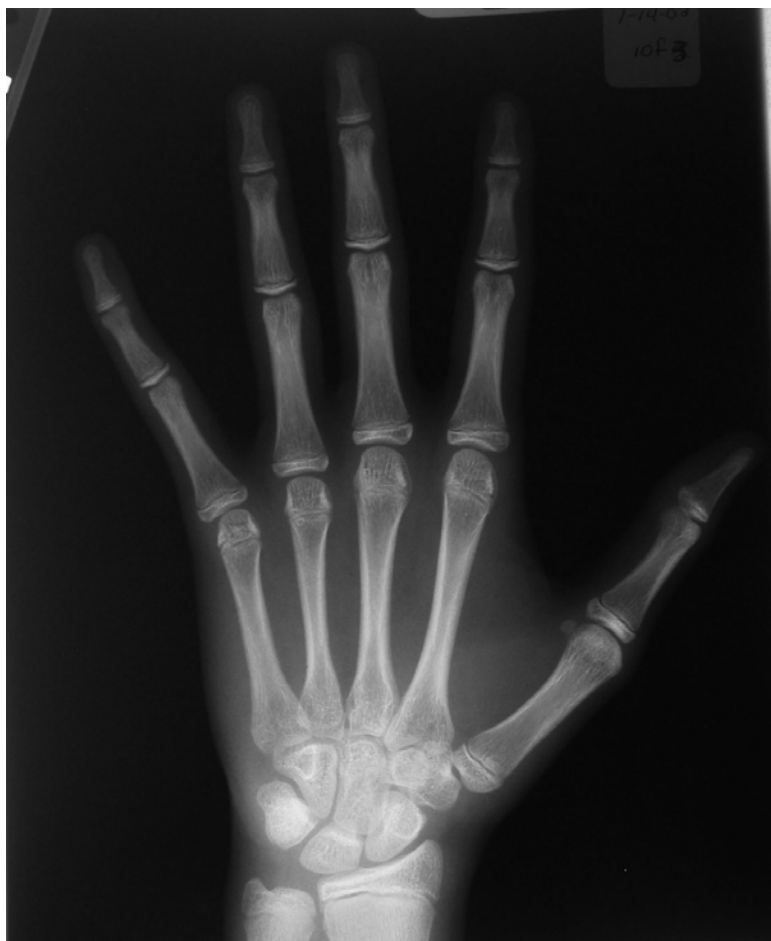

Fig. E2-6  
Adolescent rapid—late (stage 4). Now the distal phalanges definitely are beginning to close.

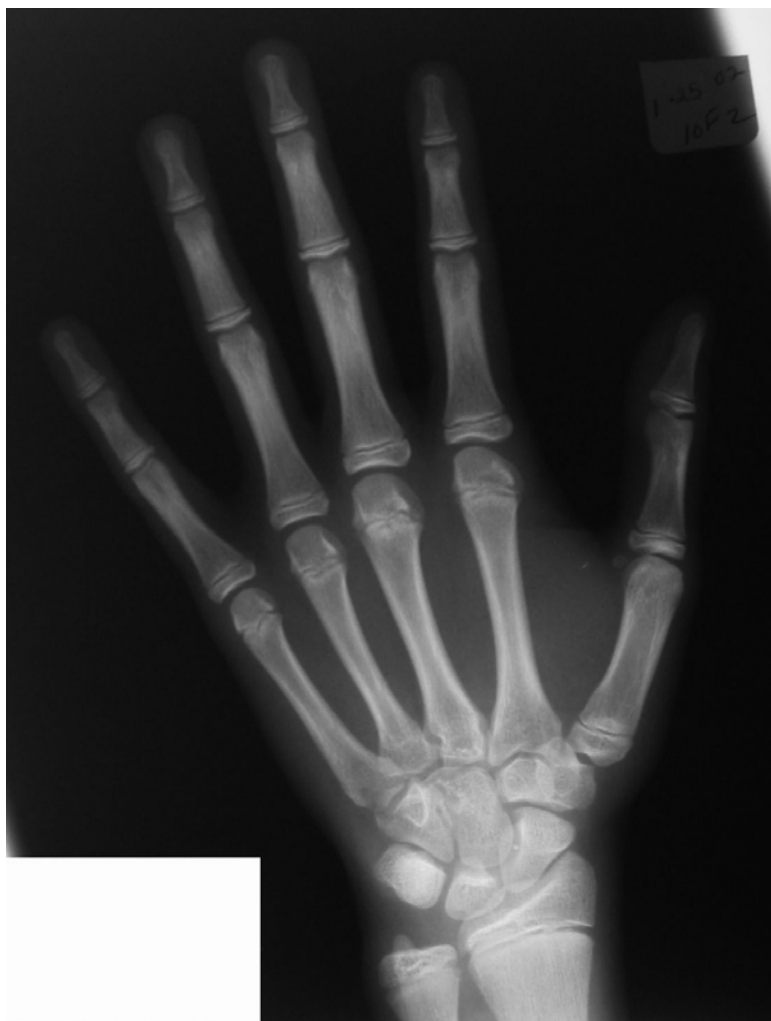

Fig. E2-7  
Adolescent rapid—early (stage 3). This radiograph is a little harder to distinguish on the thumb distal phalanx and the fifth proximal and middle phalanges. This is the advantage of using all of the digits.

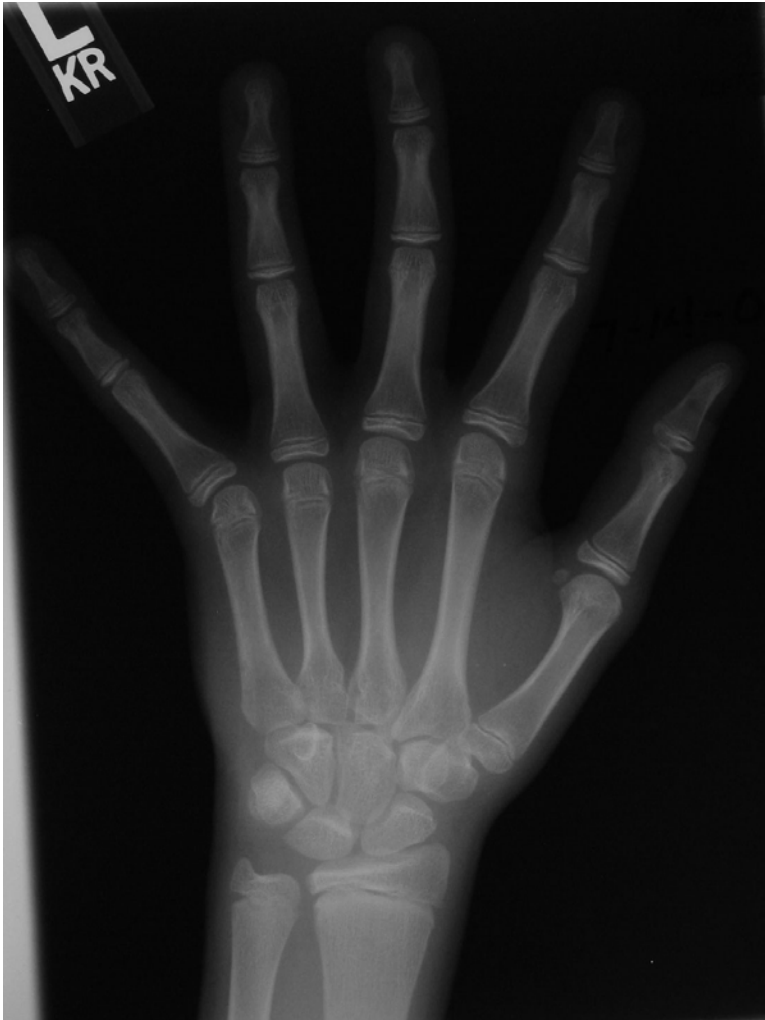

Fig. E2-8

Adolescent rapid—early (stage 3). The difficulty on this radiograph is whether they are all capping or not. There is no capping on the second and fifth middle phalanges, and the second and third metacarpal heads are not wider than the metaphyses. Overall, however, there is a preponderance of capping (three or four are not capped), which matches the description for stage 3.

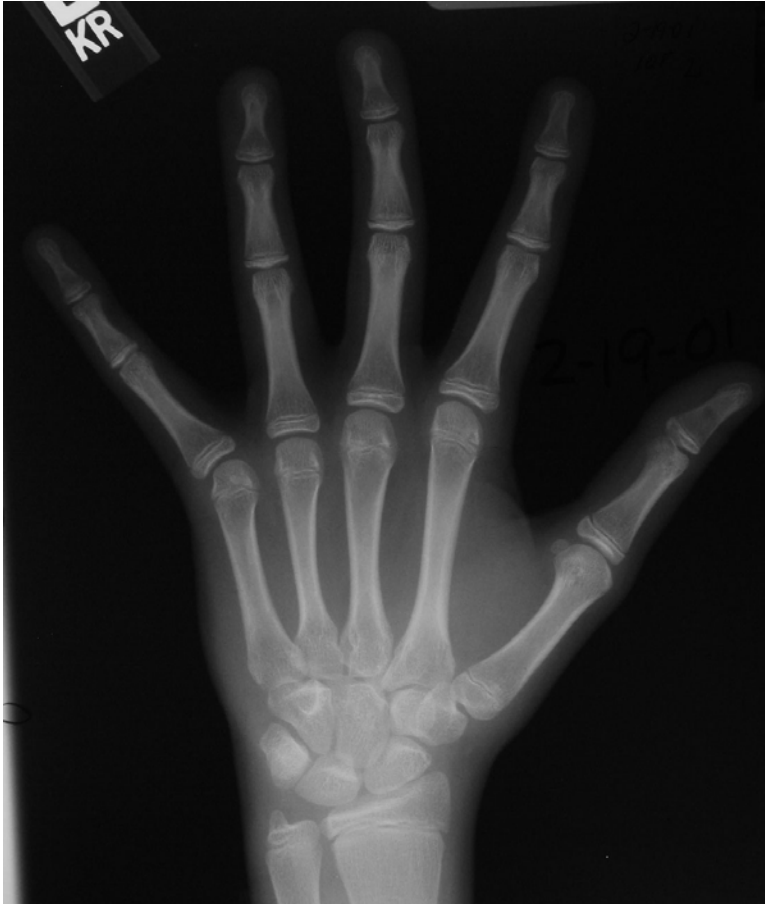

Fig. E2-9

Adolescent rapid—late (stage 4). The distal phalanges are all closed on the third, fourth, and fifth digits. The difficulty on this radiograph is that the second and first distal phalanges are still at stage “H.” To provide consistency in the classification, it is best to classify this patient in the lower stage (stage 4) rather than in stage 5. In stage 4 any of the distal phalanges are beginning to close, whereas in stage 5 all of the distal phalanges are closed. This radiograph demonstrates a good example of capping in the other phalanges and metacarpals.

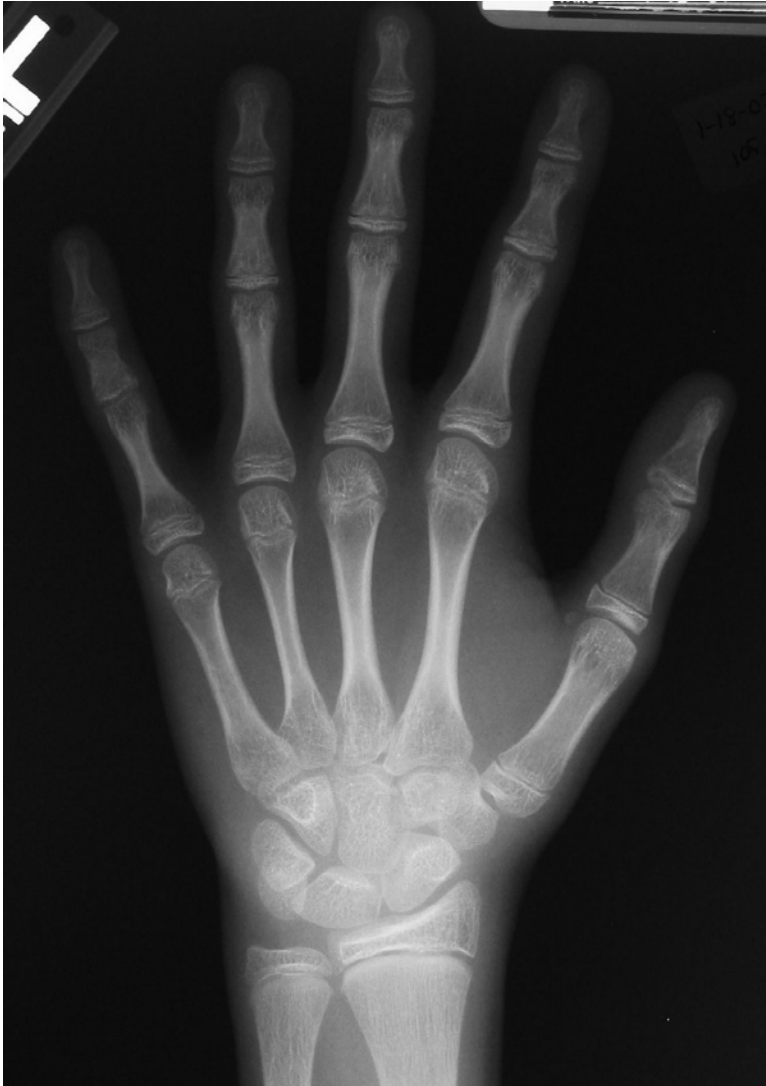

Fig. E2-10

Adolescent rapid—late (stage 4). The distal phalanges are closed, and the middle and proximal phalanges remain open. The problem in this case is the closed fifth middle phalanx. Note that this bone is short compared with the others. This patient had early closure of this phalanx even before covering or capping of the other digits. The distal phalanges still have some “black.”

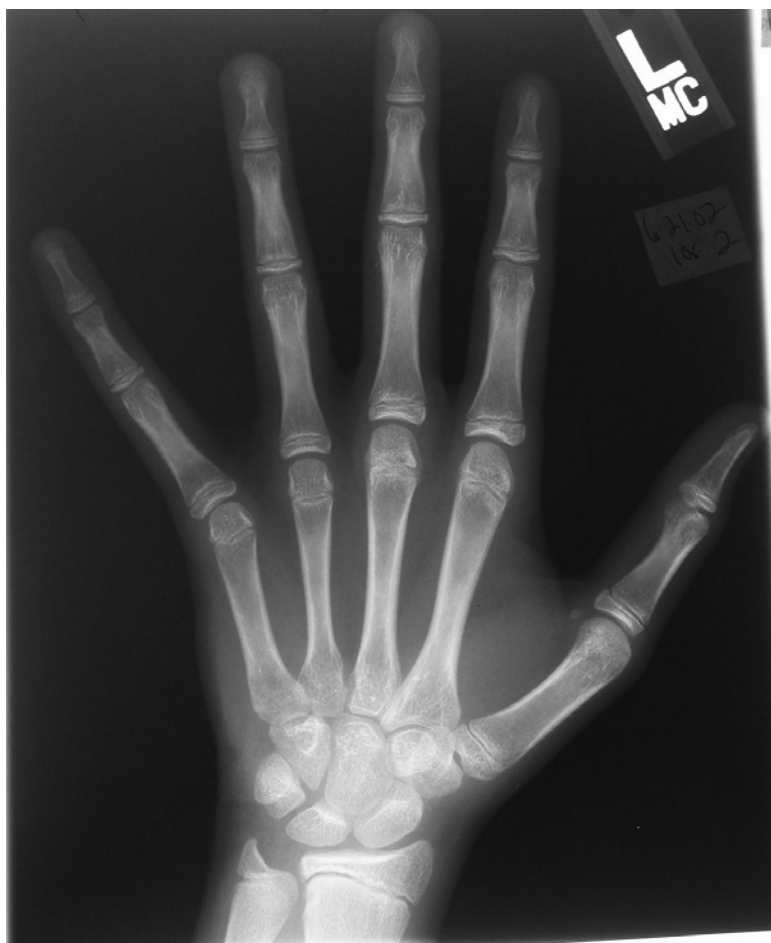

Fig. E2-11

Adolescent rapid—early (stage 3). All of these appear capped, including the distal phalanges. If the distal phalanges are capped, then everything else usually is capped too.

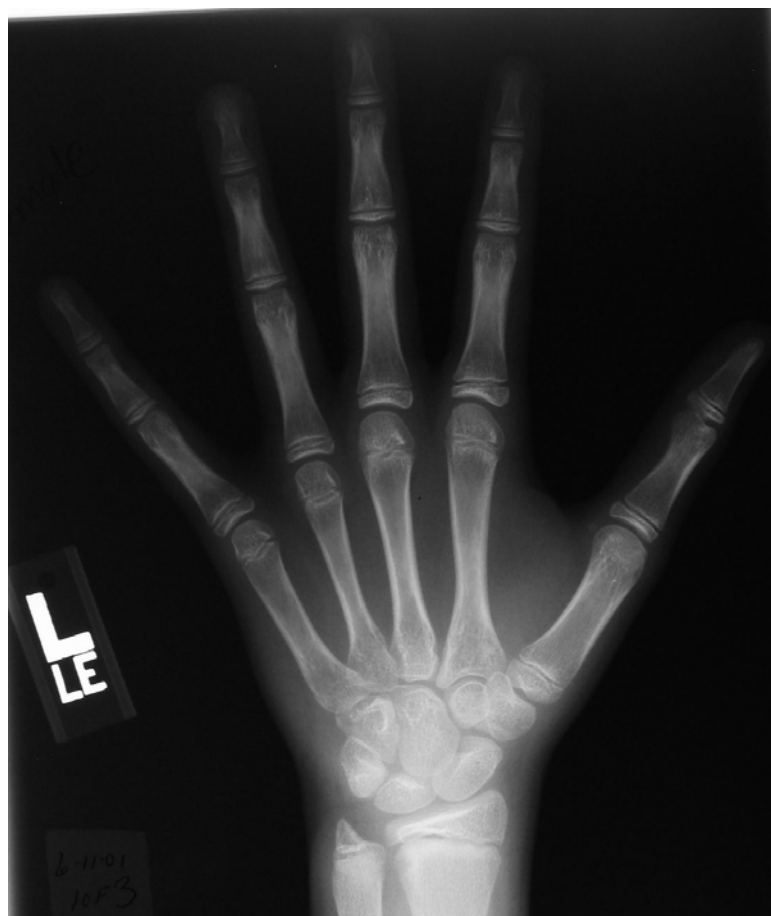

Fig. E2-12

Preadolescent slow (stage 2). There is a moderate amount of capping in the thumb, proximal phalanges, and metacarpals, but none of the middle phalanges are capped.



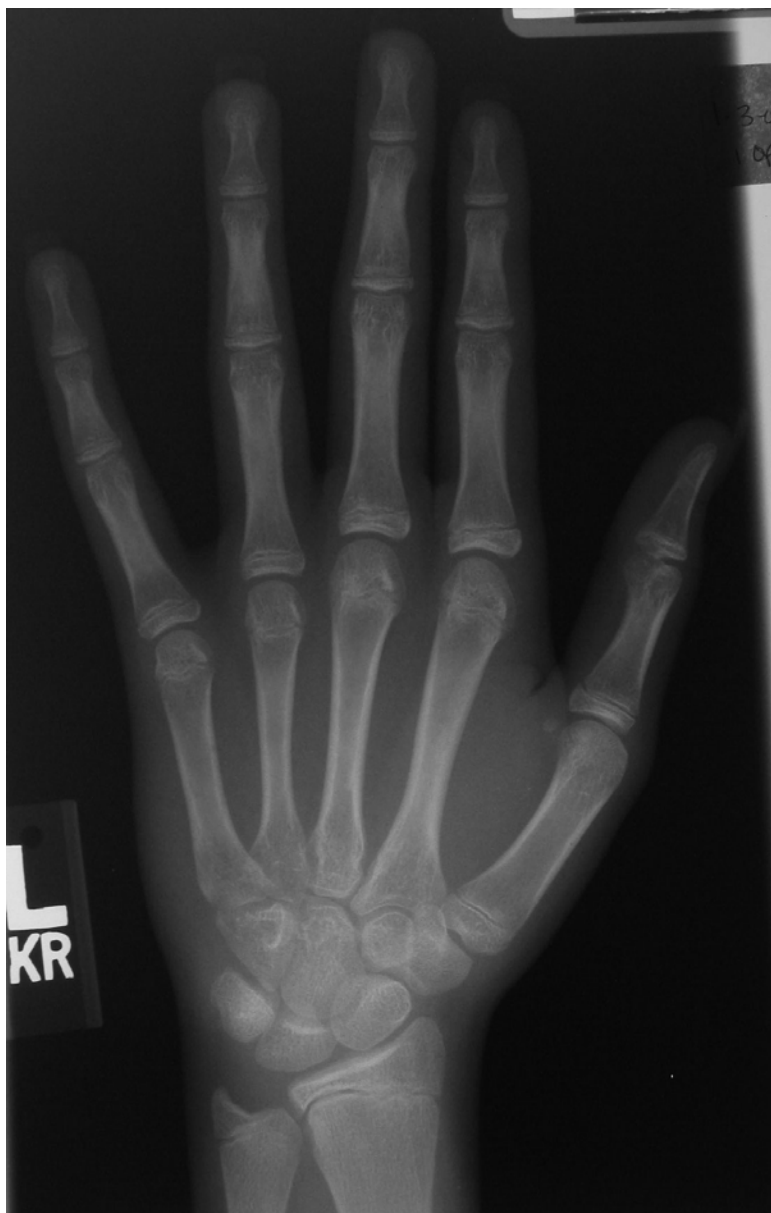

Fig. E2-13

Adolescent rapid—late (stage 4). The distal phalanges are clearly beginning to close (Tanner-Whitehouse-III stage H) but the closure is not complete (Tanner-Whitehouse-III stage I).

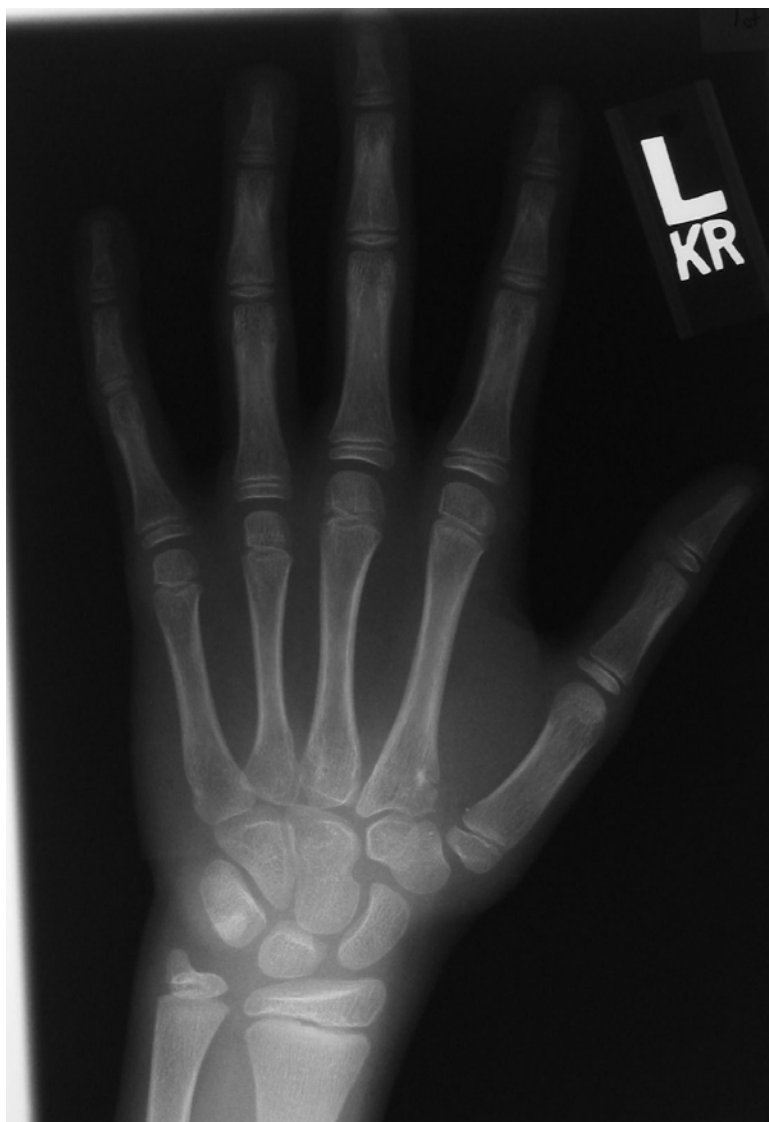

Fig. E2-14

Juvenile slow (stage 1). The epiphyses do not yet cover the metaphyses. This is particularly visible on the middle phalanges and metacarpal heads.

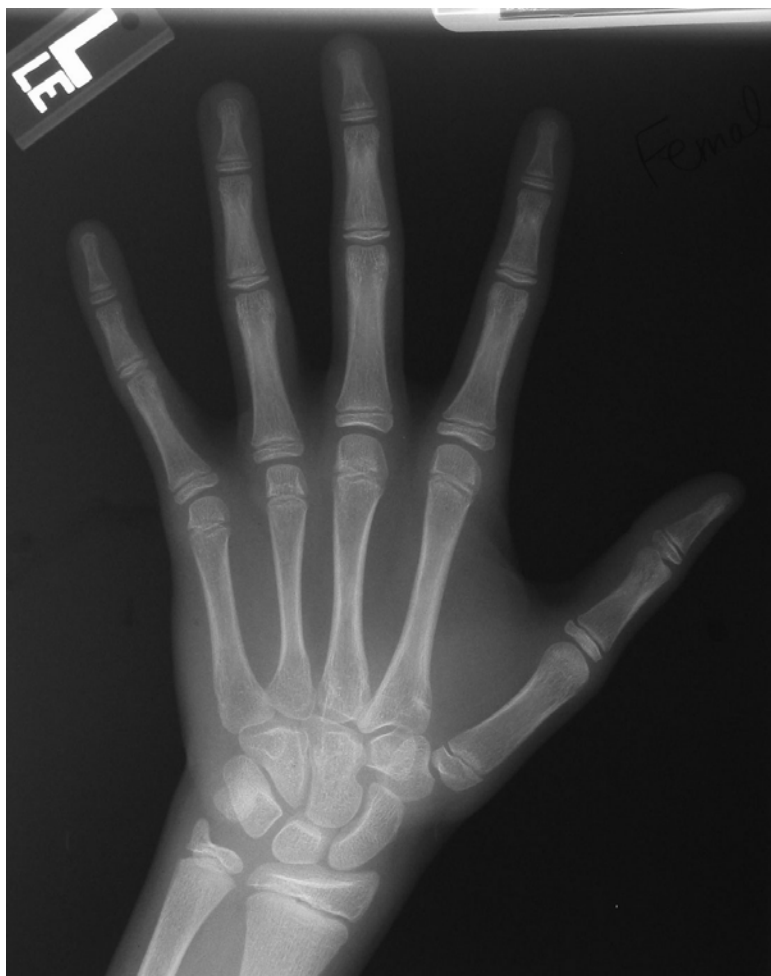

Fig. E2-15  
Preadolescent slow (stage 2). All of the epiphyses are clearly as wide as the metaphyses, but little to no capping is present.

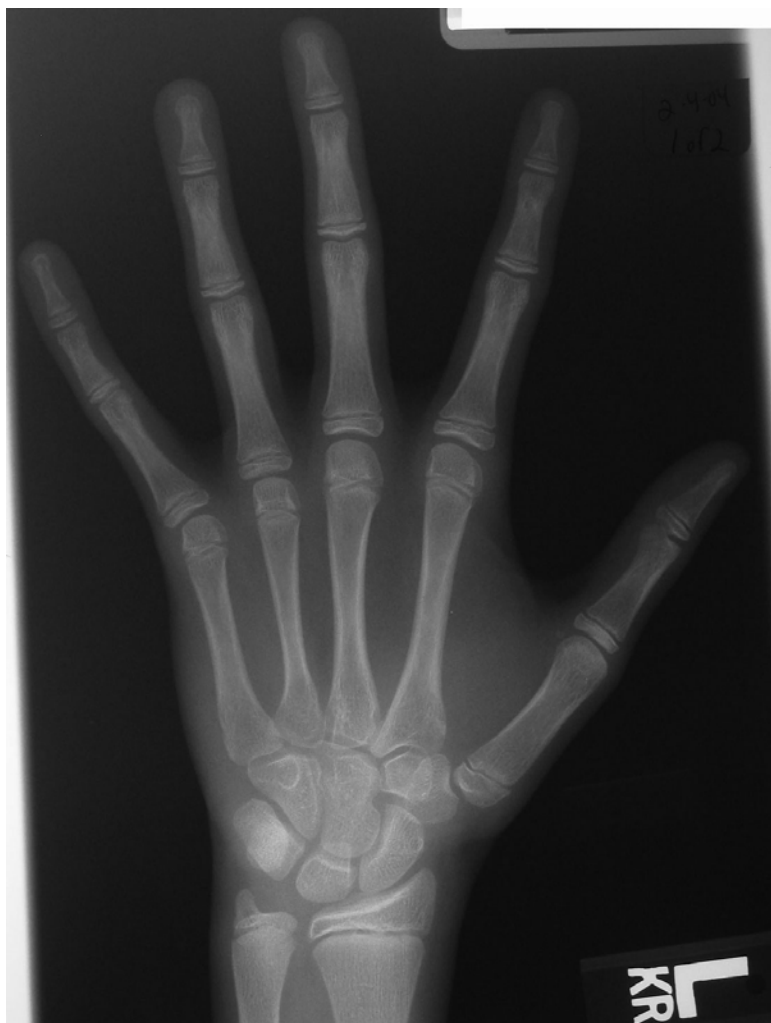

Fig. E2-16  
Adolescent rapid—early (stage 3). This radiograph demonstrates definite capping of all but the distal phalanges.

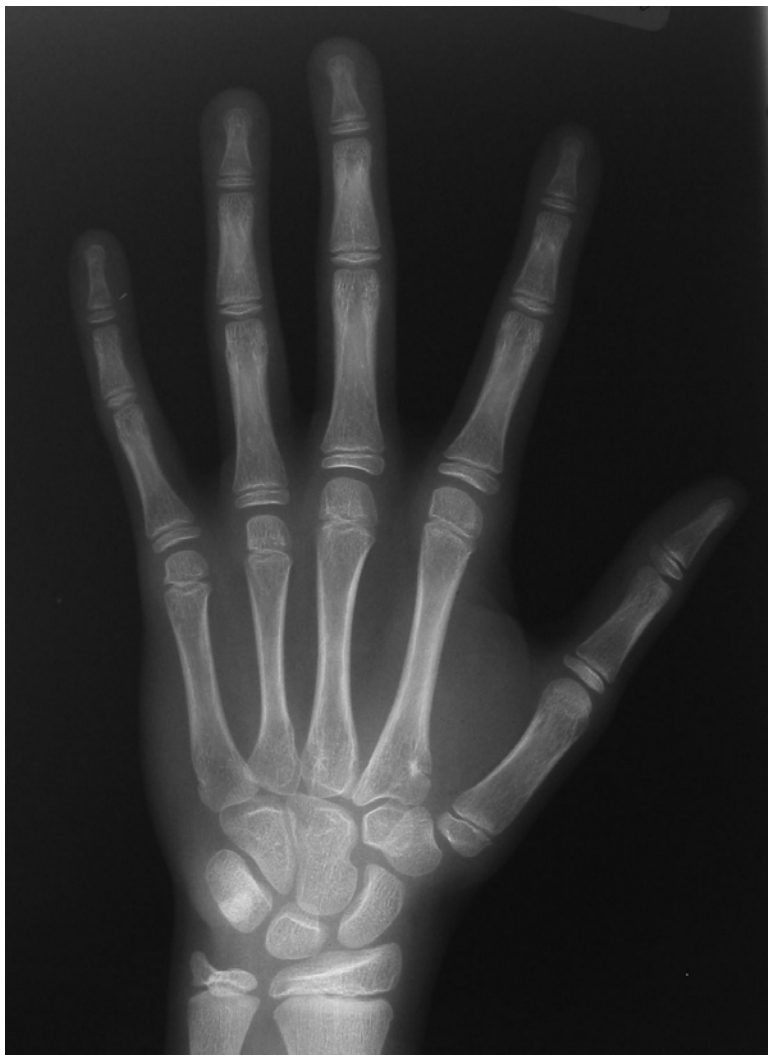

Fig. E2-17

Juvenile slow (stage 1). On the radial side of the hand, many of the metaphyses are covered, but not on the ulnar side. Particular attention should be paid to the fifth middle phalanx and metacarpal head.

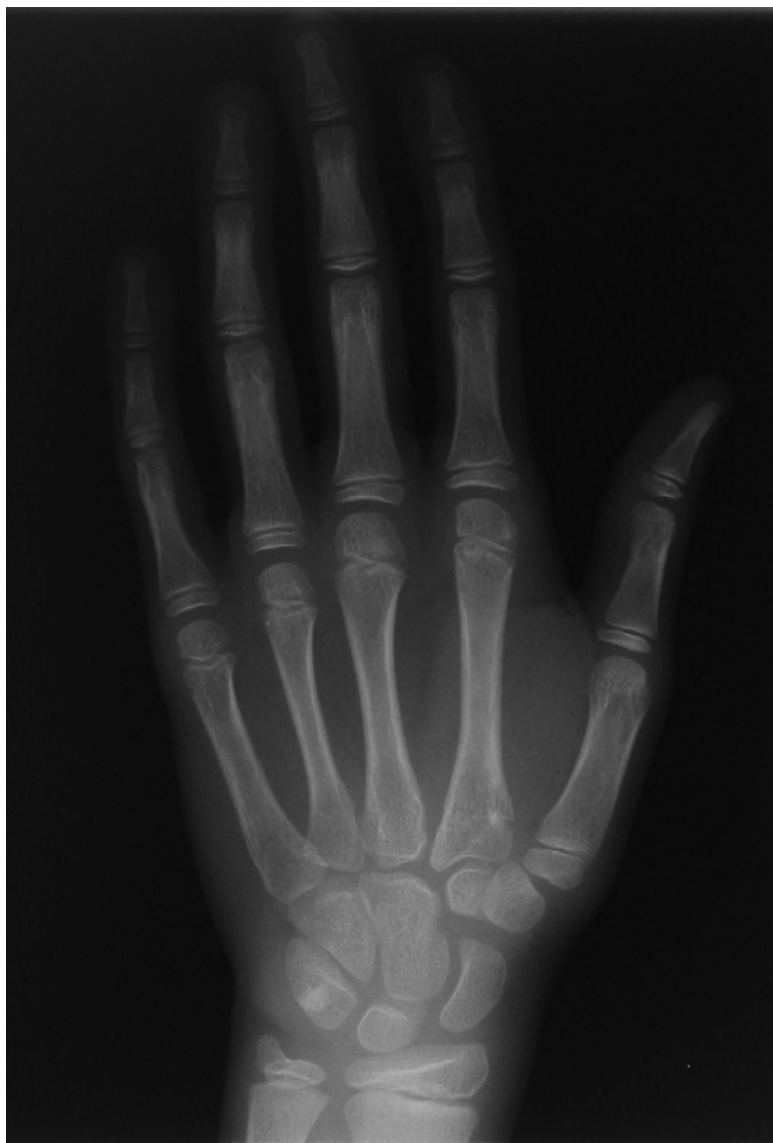

Fig. E2-18  
Juvenile slow (stage 1). This example is very clear.

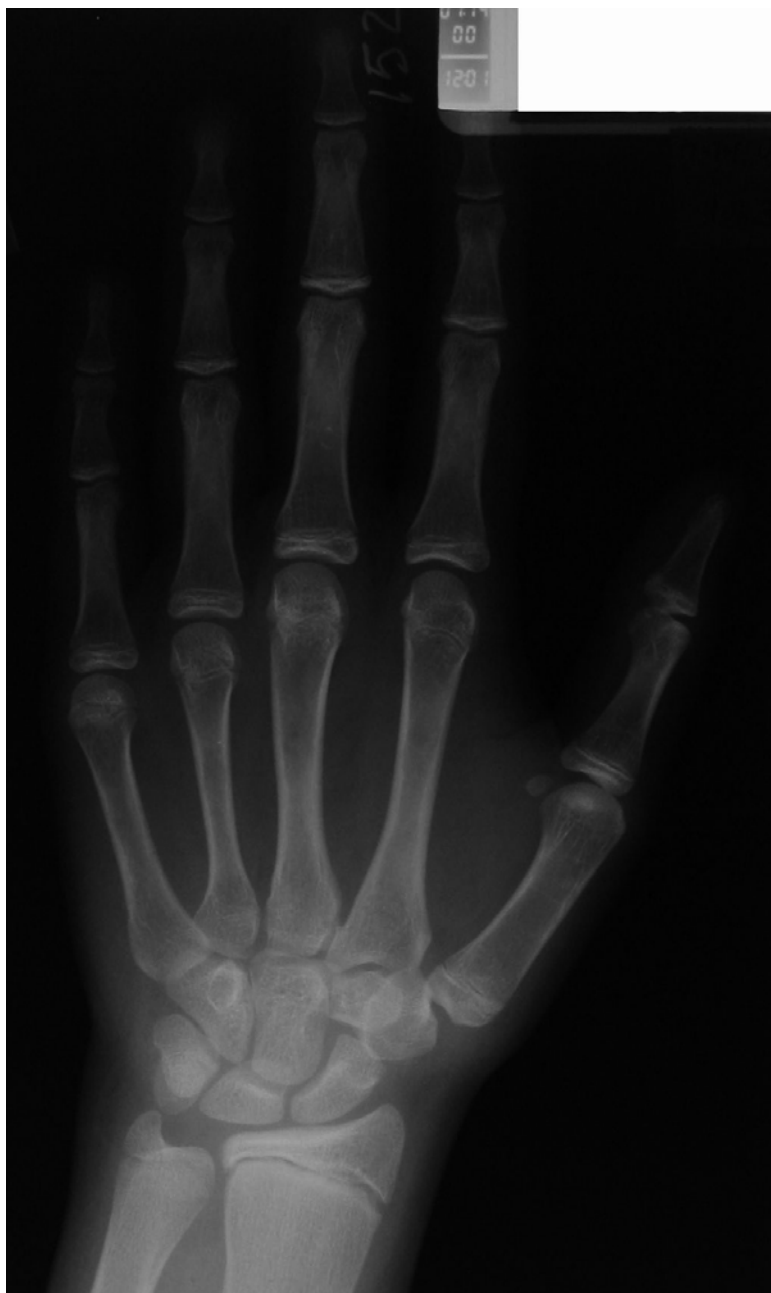

Fig. E2-19

Adolescent steady—late (stage 6). The distal phalanges are closed and the middle phalanges are nearly closed (stages H and I). However, the proximal phalanges have not closed yet.

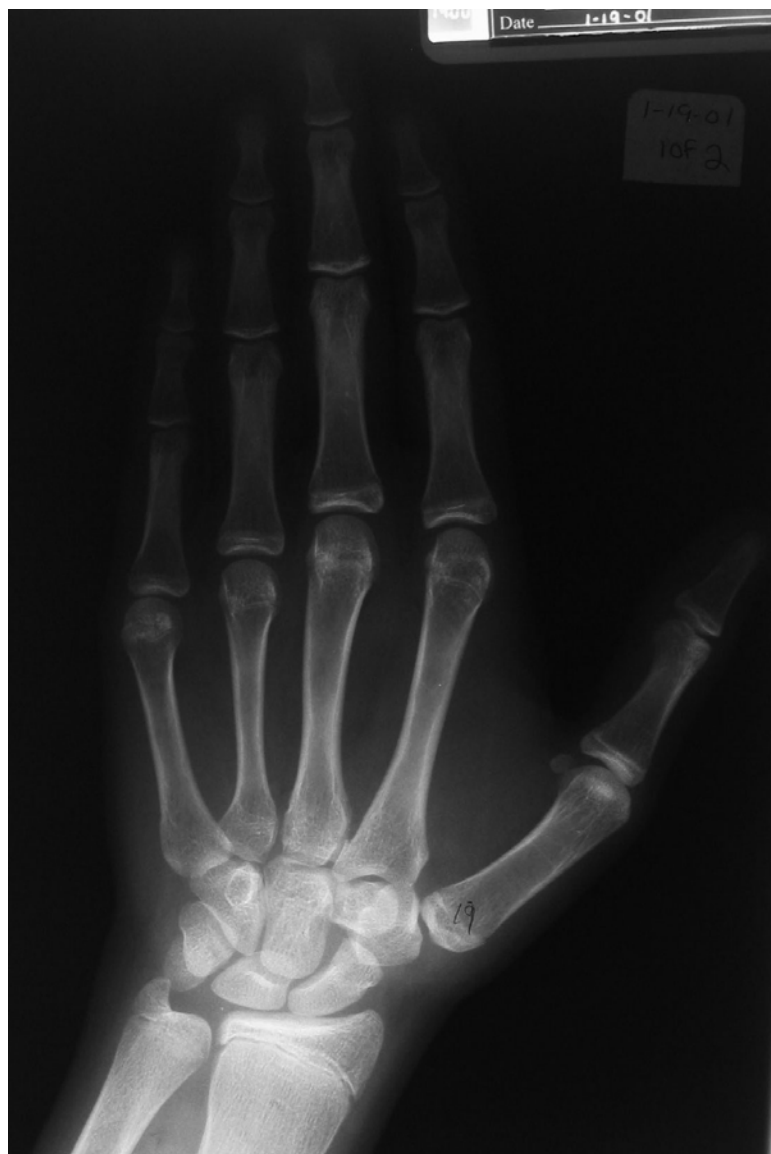

Fig. E2-20

Early mature (stage 7). All of the phalanges are closed. There is a physeal scar present along the proximal phalanges and the metacarpal heads. With regard to the Tanner-Whitehouse-III descriptions, this is compatible with stage I.