

E-Appendix

General Principles

The acetabular index and center-edge angles following reorientation should correspond as closely as possible to the normal anatomy (acetabular index angle, 0° to 10°; center-edge angle, 30° to 40°). It is of equal importance that the surgeon obtain appropriate anteversion of the acetabulum. Assessment of the range of motion and joint stability at the end of the procedure will help the surgeon to evaluate the change in hip joint mechanics. This description of the minimally invasive approach will give the reader an understanding of soft-tissue mobilization, instrument handling, and the performance of the osteotomies. Understanding of the anatomy and utilization of fluoroscopy during surgery are the keys to a safe, minimally invasive periacetabular osteotomy.

Pubic Osteotomy

Subperiosteal access to the superior ramus of the pubic bone is gained with use of a periosteal elevator. It is important that the pubic osteotomy be performed medially on the superior ramus since the bone otherwise is too thick, making the osteotomy and mobilization difficult or impossible. A curved blunt retractor is placed in the obturator fossa behind the superior ramus of the pubic bone. It is important that this retractor be placed subperiosteally to protect the obturator artery and nerve. A splined retractor is then placed anterior and medial to the site of the osteotomy in order to retract the iliopsoas muscle medially and protect the iliac artery and vein and the femoral nerve (Fig. E1). The superior ramus is then osteotomized under direct visualization with use of a slightly curved osteotome. It is important to advance the osteotome until the osteotomy is complete; otherwise, the repositioning of the splined retractor becomes difficult as it will tend to slide into the osteotomy site. The surgeon often is able to hear and feel (loss of resistance) when the bone is

fully osteotomized. This sensory input should be utilized during surgery to avoid both creation of an insufficient osteotomy and advancement of the osteotome into the soft tissues.

Ischial Osteotomy

When advancing to the ischial osteotomy, the surgeon keeps the splined retractor in its position to retract the iliopsoas muscle medially. A large pair of scissors is used to penetrate the interval immediately lateral and distal to the pubic osteotomy, and the scissors are advanced to the ischium below the acetabulum. With the scissors kept in place, a 30° angled osteotome can be placed on the ischium. The correct placement of the osteotome is verified with use of fluoroscopy (an anteroposterior view). The osteotomy begins approximately 5 mm distal to the radiographic teardrop. A 1.5-cm osteotomy is performed in two steps, beginning at the medial edge and then moving the osteotome laterally before the next step (Fig. E2). A 30° angled osteotome is advanced along the inner aspect of the pelvis until it can be placed at the medial aspect of the ischium with one leg of the osteotome in the existing 1.5-cm osteotomy. The placement of the osteotome and the osteotomy itself are performed under strict fluoroscopy control, with utilization of the so-called false-profile view, which is angled 60° to the anteroposterior view (Fig. E3-A). The ischium is then osteotomized from the medial to the lateral aspect for a length equal to two to three widths of the osteotome (Fig. E3-B). This osteotomy tends to be slightly curved with the concavity toward the acetabulum. In order to advance in the same plane as the initial 1.5 cm of the osteotomy and to obtain an almost horizontal osteotomy, the handle of the 30° angled osteotome must be pushed medially. When the posterior aspect of the ischium is osteotomized, the sciatic nerve can be damaged if the osteotome is advanced too far past the bone in the lateral direction.

Iliac Osteotomy

Initially, a Kirschner wire is inserted along the inner aspect of the pelvis, approximately 3 cm cranial to the acetabulum. This is done to secure an appropriate distance from the joint. From experience, we have learned that it is easier to mobilize and control the acetabular fragment if this distance from the joint is achieved. The first step of the iliac osteotomy begins between the anterior superior iliac spine and the anterior inferior iliac spine at the level of the Kirschner wire. It is performed with use of an oscillating saw, stopping approximately 1 cm before the linea terminalis is reached. In some patients, the distance from the anterior superior iliac spine to the cranial limit of the joint is relatively short. In these cases, a small oblique osteotomy under the anterior superior iliac spine is recommended. To protect the structures lateral to the ilium, a blunt retractor is tunneled close to the bone along the outer aspect of the ilium in the area between the anterior superior and anterior inferior iliac spines. The blunt retractor must be advanced close to the bone as otherwise the blood supply from the superior gluteal artery can be damaged. A retractor protects the structures medial to the ilium. The first step of the osteotomy is then continued with use of a wide, straight osteotome. With an anterior open angle of approximately 120°, this osteotome is advanced behind the hip joint until it reaches the ischial osteotomy site while the posterior column is maintained intact. Fluoroscopy (a 60°-angle false-profile view) must be used during this last step of the iliac osteotomy (Fig. E4).

Reorientation

A bone spreader is placed in the iliac osteotomy site. With the osteotomy sites open, the iliac and ischial osteotomies can be retraced in succession with use of a 30° angled osteotome to ensure that there are no remaining osseous bridges or spikes interfering with mobilization of the acetabular fragment. A bone clamp is then applied at the ilium with one leg of the clamp on the inner aspect and one leg on the outer aspect. On the inner aspect, the ilium is oblique, and a small hole is predrilled to allow secure fixation of the clamp. This

gives the surgeon control of the fragment during the reorientation. The first step of the acetabular reorientation is to achieve sufficient lateral coverage. This is done by adducting the fragment. In our experience, this maneuver has been sufficient to medialize the hip joint center, which often is lateralized in dysplastic hips. As a rule of thumb, the acetabular index angle following reorientation should approximate 0° (horizontal positioning of the sclerotic acetabular roof) and should never be less, as this will result in overcoverage and impingement. The second step of the acetabular reorientation is to achieve sufficient anterior coverage. This is done by extension of the fragment. In our experience, very little movement has been needed to create sufficient anterior coverage. The risk of too much anterior coverage and retroversion is great at this point in the reorientation procedure. Version of the acetabulum is evaluated by assessing the relationship between the anterior and posterior acetabular rims with use of fluoroscopy (an anteroposterior view). Sufficient anteversion is achieved when the posterior rim is lateral to the anterior rim and the center of the femoral head, the anterior rim is medial to the center of the femoral head, and there is no crossover sign. If the acetabular fragment has been properly mobilized and reoriented, cranial displacement of the superior ramus and cranial and medial displacement of the teardrop can be observed on the anteroposterior fluoroscopic view. If these are not observed, the fragment is hinging, probably as a result of an unfinished osteotomy of the ischium (Fig. E5). A large threaded Kirschner wire is then placed from the ilium into the acetabular fragment in order to temporarily secure the new position. A measuring device makes it possible to perform perioperative measurements of the acetabular index and center-edge angles on the anteroposterior fluoroscopy view. With use of small spikes, the measuring device is mounted bilaterally at the anterior superior iliac spines in order to secure alignment of the pelvis when the measurements are performed. Excessive tilt and rotation of the pelvis are avoided through the initial positioning of the patient. On the alignment rod connecting the spikes, two different adjustable angle measuring discs can be mounted. The disc for measuring the

acetabular index angle has to be positioned by recognizing the medial and lateral limits of the sclerotic acetabular roof as landmarks. The disc for measuring the center-edge angle has to be positioned by recognizing the center of the femoral head and the lateral limit of the sclerotic acetabular roof as landmarks (Fig. E6). The measuring device is easy to use, and it helps the surgeon to assess the achieved acetabular reorientation and thereby avoid undercorrection or overcorrection. Acetabular version cannot be measured and still has to be addressed as described previously. Fine adjustments of the reorientation might be necessary. When no further adjustment is needed, two stainless-steel screws are placed from the ilium at the anterior superior iliac spine into the acetabular fragment to secure its position. The positions of the screws are visualized with use of fluoroscopy, and the stability of the fixation is tested by applying force on the fragment. The range of motion of the hip is assessed, and no impingement should be encountered during internal rotation of the flexed hip. Posterior stability of the joint is tested by flexing the hip and pushing the knee toward the operating room table. After irrigation with saline solution, the inguinal ligament is reattached and the soft tissues are closed in layers. A suction drain is not used.

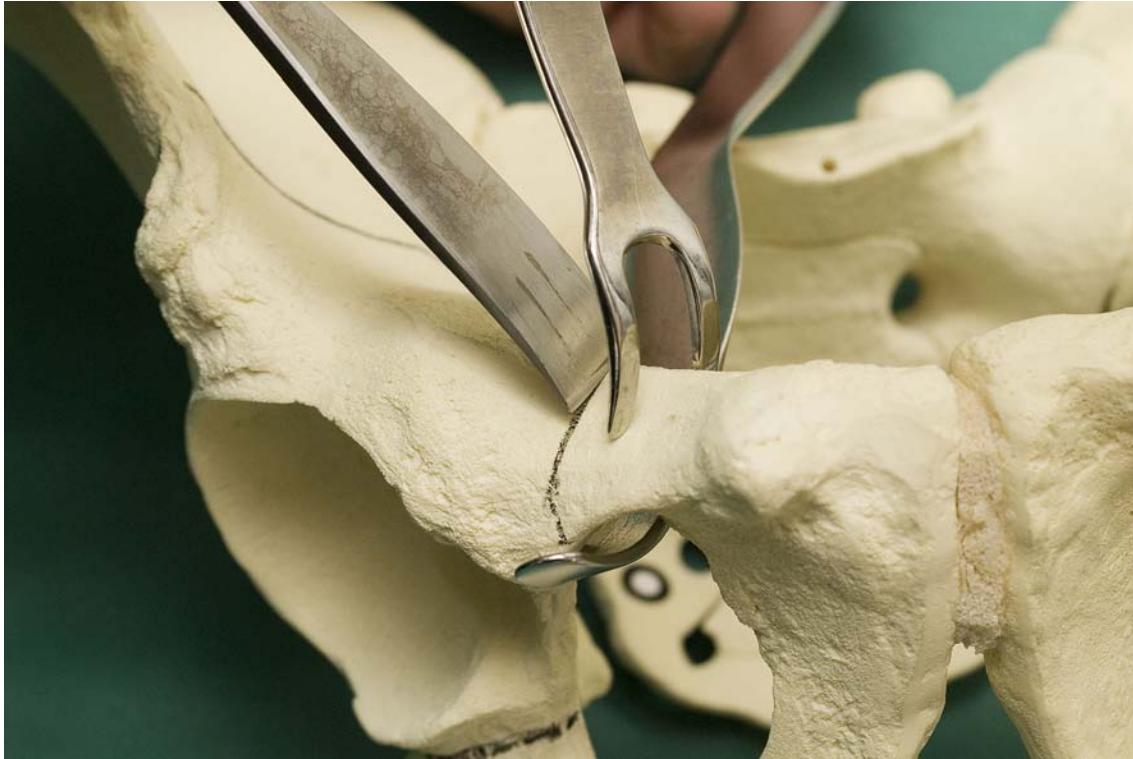

Fig. E1

The site of the osteotomy on the pubic bone and the placement of the instruments. A curved blunt retractor is placed behind the pubic bone to protect the obturator nerve and artery. A splined retractor is used for medial retraction of the soft tissues, and a slightly curved osteotome is used to create the osteotomy.

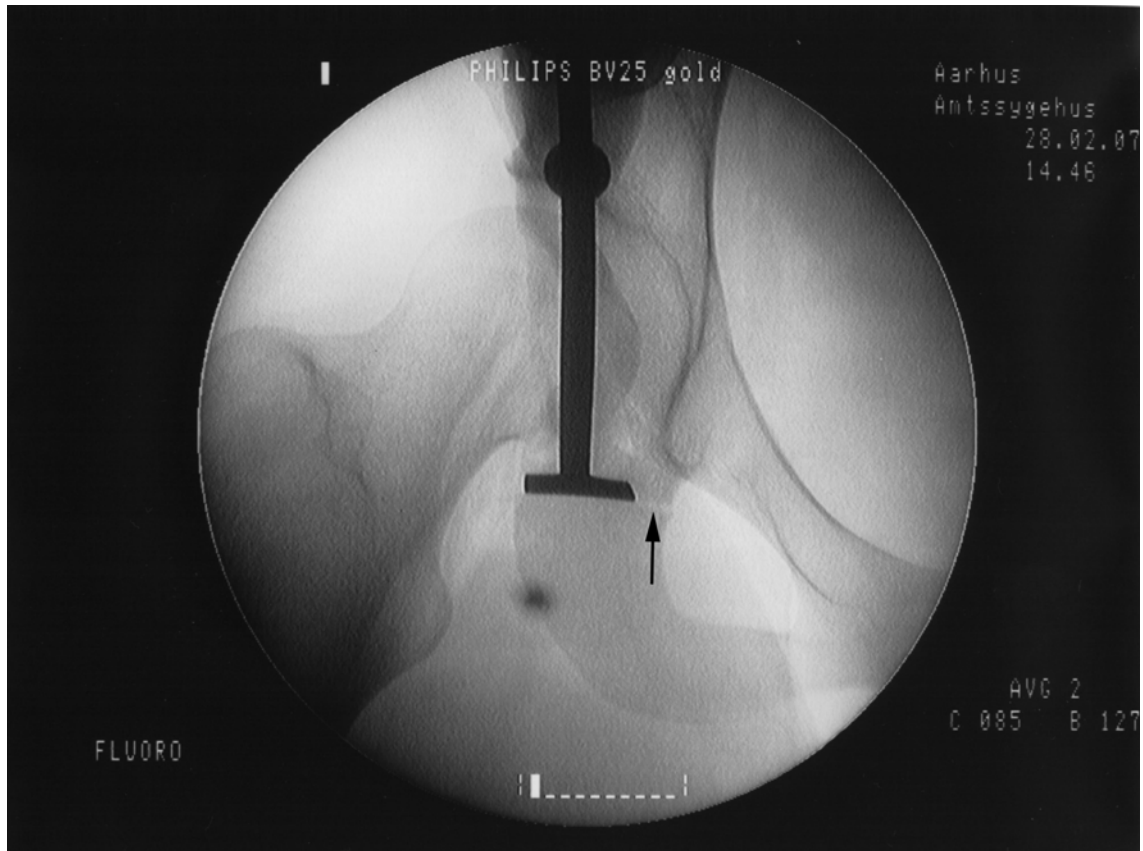


Fig. E2

Fluoroscopic anteroposterior view showing the lateral placement of the osteotome at the ischial bone below the teardrop. The osteotomy performed at the medial edge of the ischium is seen (arrow).

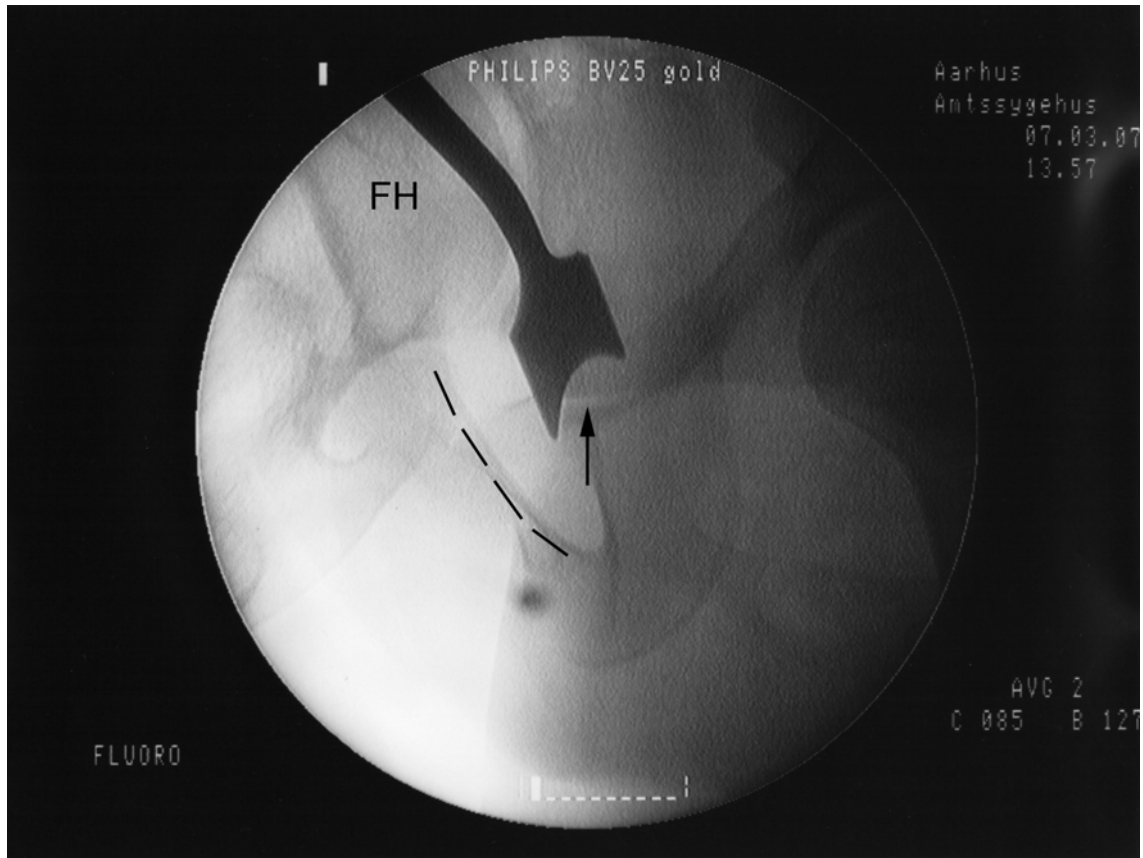


Fig. E3-A

Figs. E3-A and E3-B Fluoroscopic false-profile views angled 60° to the anteroposterior view. **Fig. E3-A** Correct placement of the osteotome with one leg in the existing osteotomy (arrow). The dashed line marks the border of the pubic bone toward the obturator foramen. FH = femoral head.

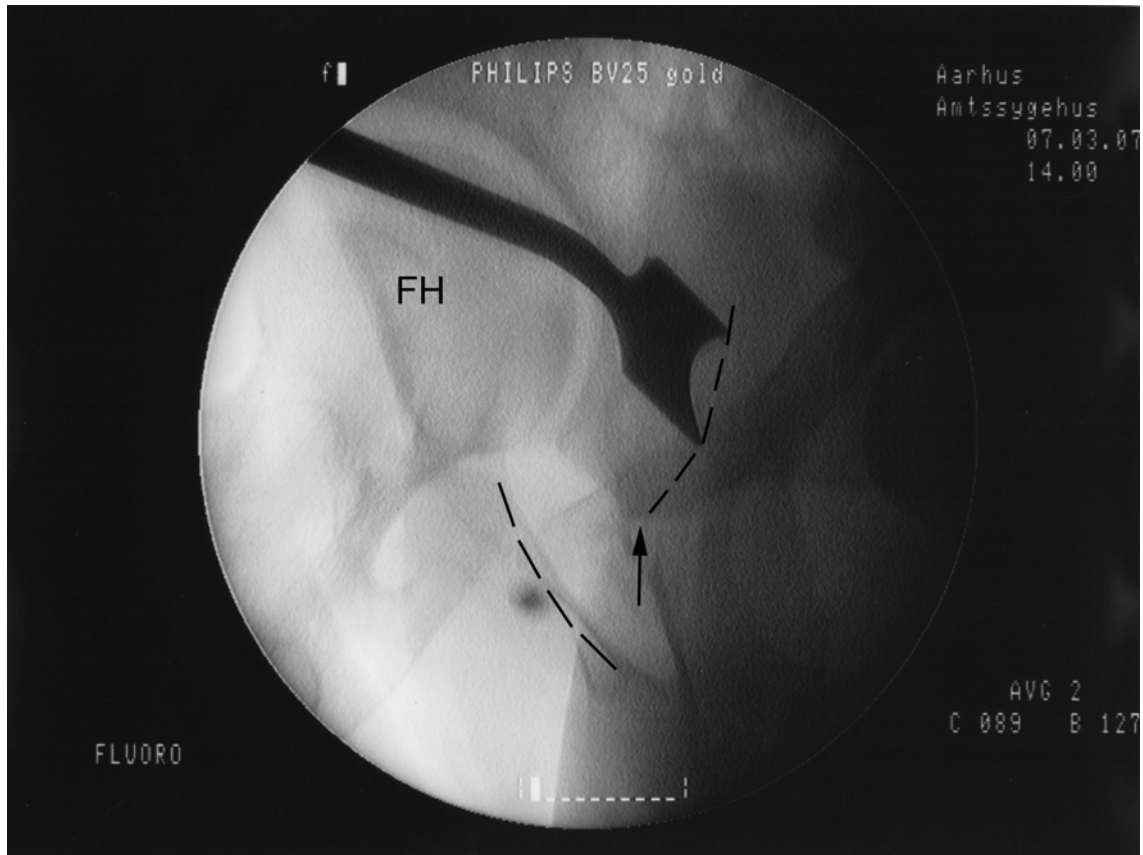


Fig. E3-B

Correct placement of the osteotome for the last step of the ischial osteotomy. As illustrated by the dashed line where the osteotome is placed, the osteotomy is slightly curved. The arrow marks the level of the already performed osteotomy. As in Fig. E3-A, a dashed line marks the border of the pubic bone toward the obturator foramen. FH = femoral head.

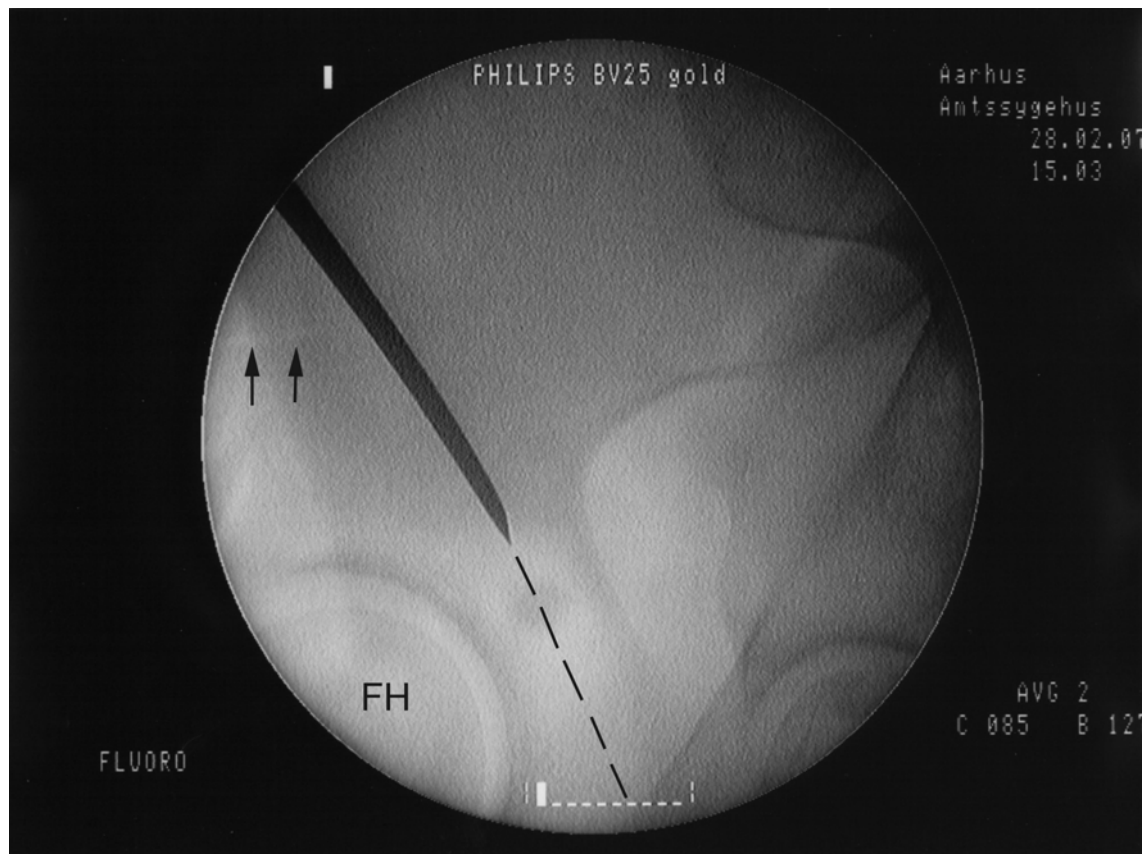


Fig. E4

Fluoroscopic false-profile view angled 60° to the anteroposterior view, showing the advancement of a straight osteotome in continuation with the first step of the iliac osteotomy (arrows). It is advanced (dashed line) at an anterior open angle of around 120° between the joint and the posterior column until it reaches the ischial osteotomy site. FH = femoral head.

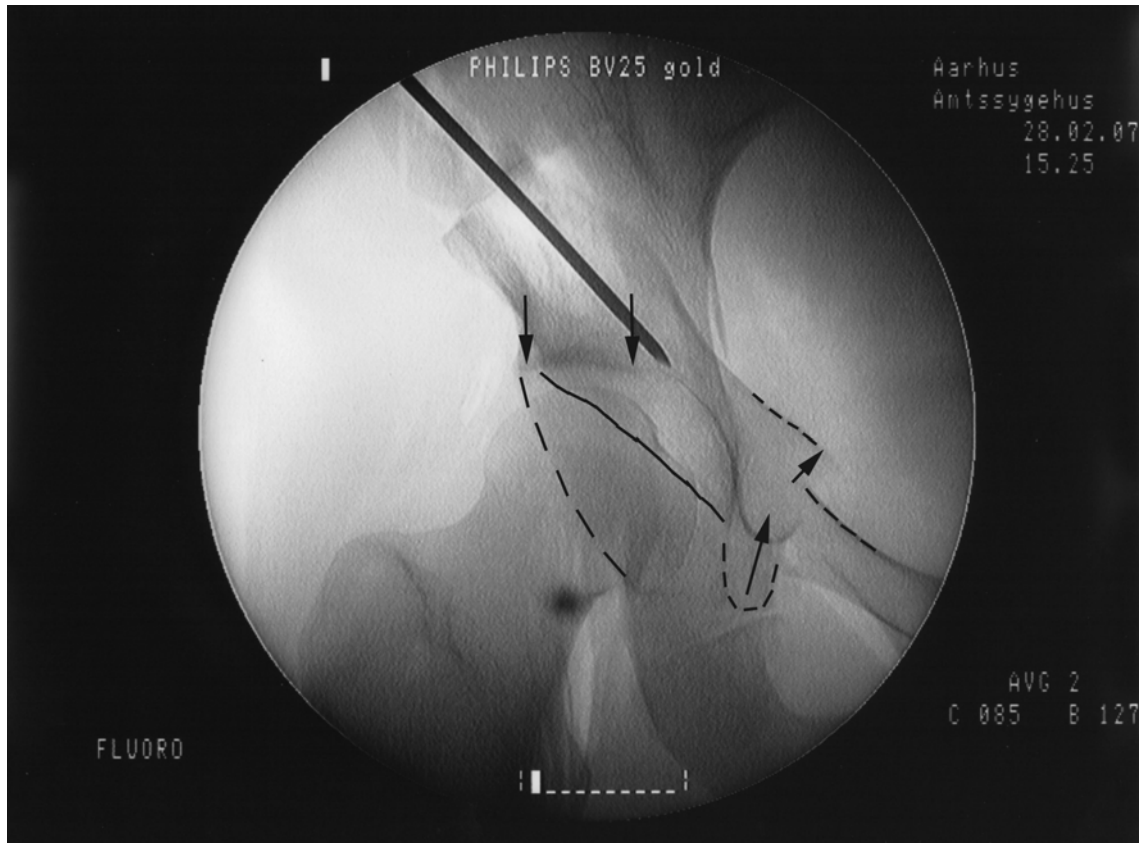


Fig. E5

A large threaded Kirschner wire is temporarily securing the position. Note the horizontal positioning of the medial and lateral extents (arrows) of the sclerotic acetabular roof, the anteverted configuration of the acetabulum (dashed line = posterior rim and solid line = anterior rim), the cranial displacement of the superior ramus, and the cranial and medial displacement of the teardrop figure.

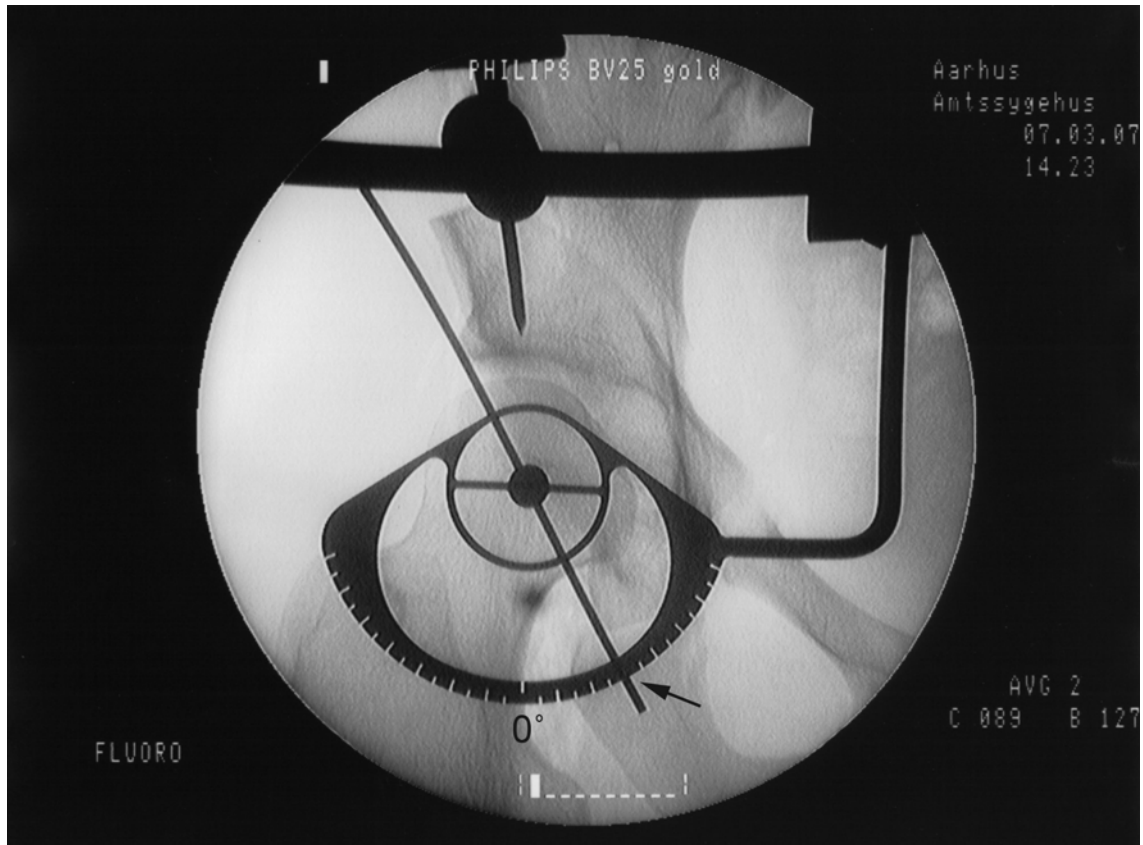


Fig. E6

The angle-measuring disc for the measurement of the center-edge angle. It is positioned by recognizing the center of the femoral head and the lateral limit of the sclerotic acetabular roof as landmarks. The measured angle in this case is 30° (arrow). The 0° mark is labeled.

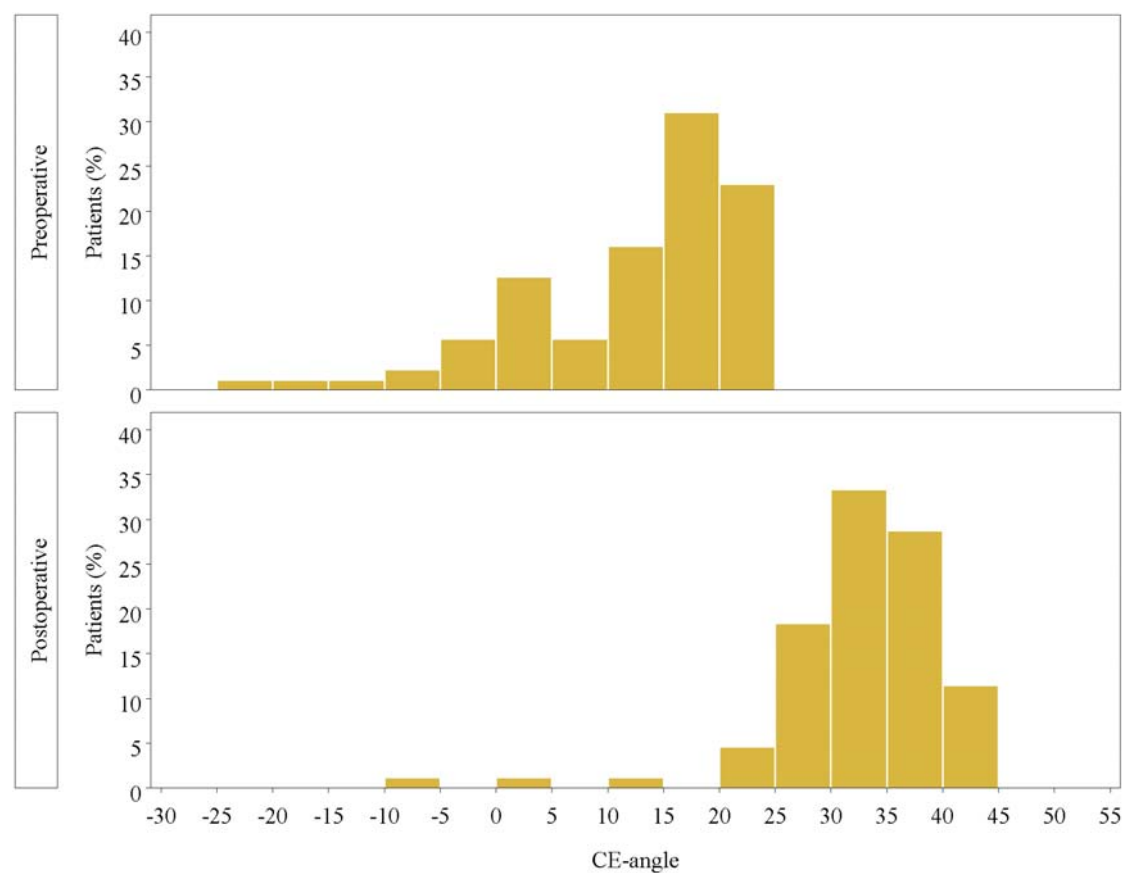


Fig. E7-A
Figs. E7-A and E7-B Distribution of measured preoperative and postoperative angles. **Fig. E7-A** Center-edge (CE) angles.

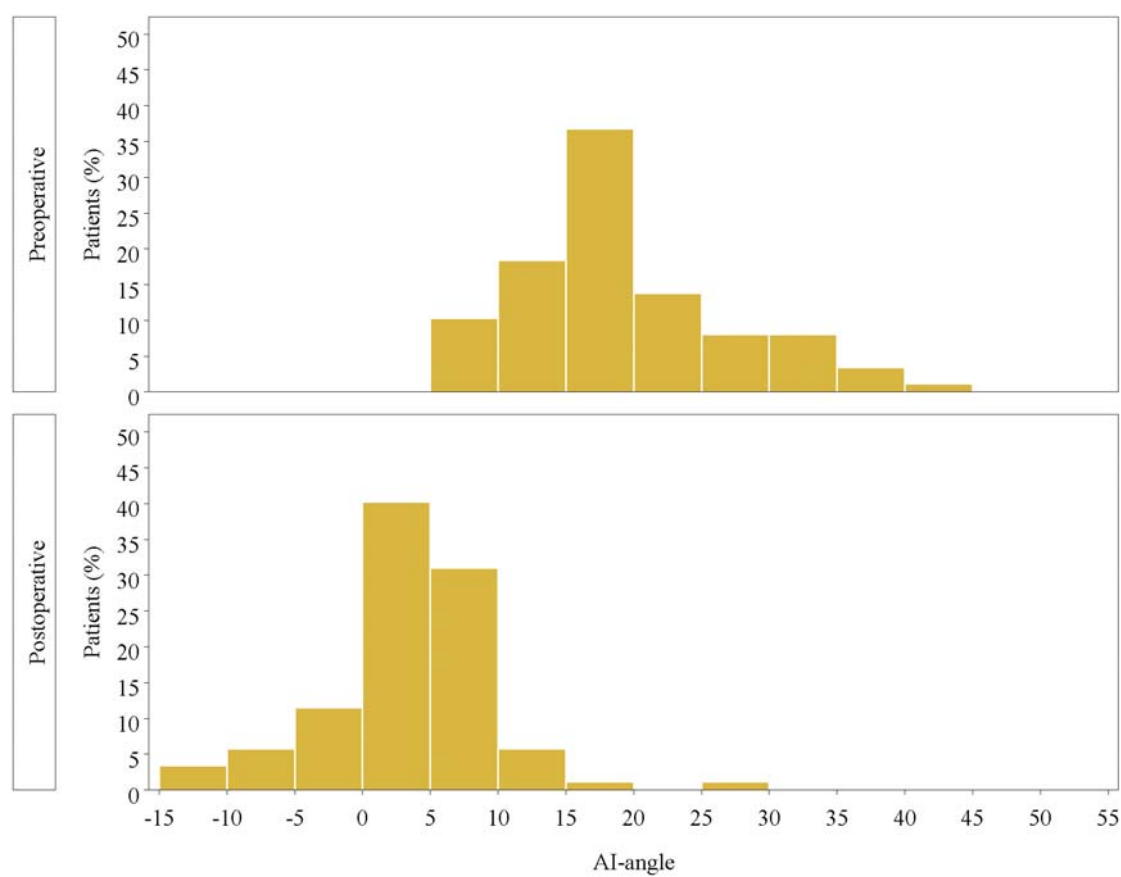


Fig. E7-B
Acetabular index (AI) angles.