

Fig. E-1

Close-up view of a deep subgluteus maximus bursa (A) interposed between the fascia lata and the gluteus medius. The tensor fasciae latae muscle has been reflected posteriorly with the fascia lata.

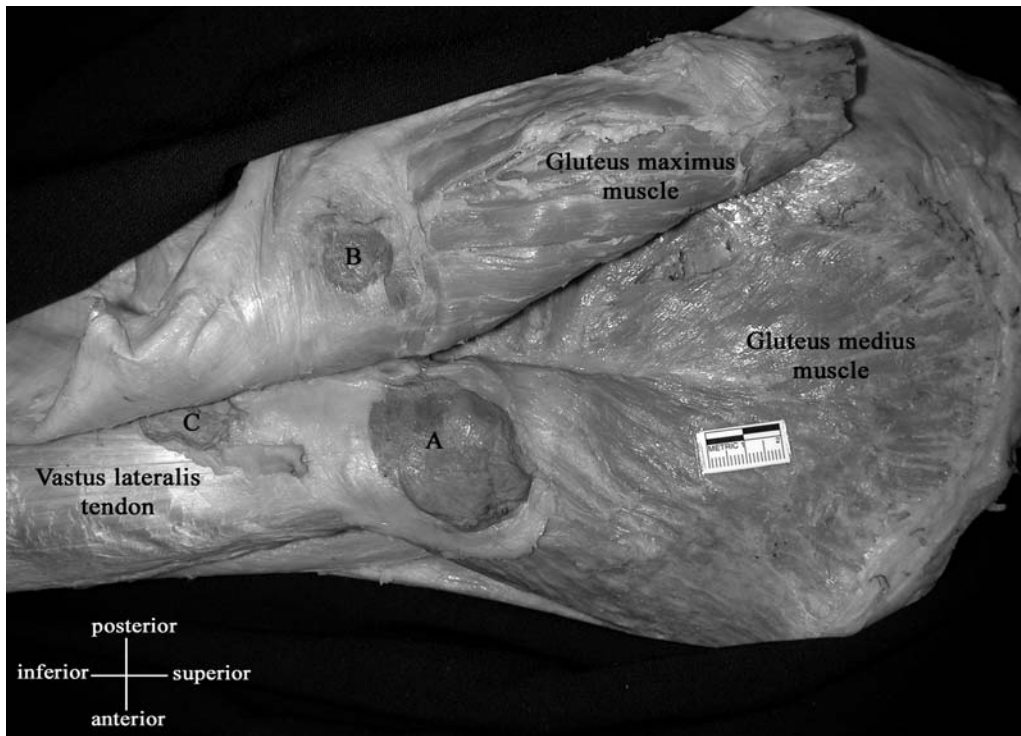


Fig. E-2

Three of the subgluteus maximus bursae have been injected with blue-colored latex: the deep subgluteus maximus bursa (A), the superficial subgluteus maximus bursa (B), and the gluteofemoral bursa not associated with the greater trochanter (C).

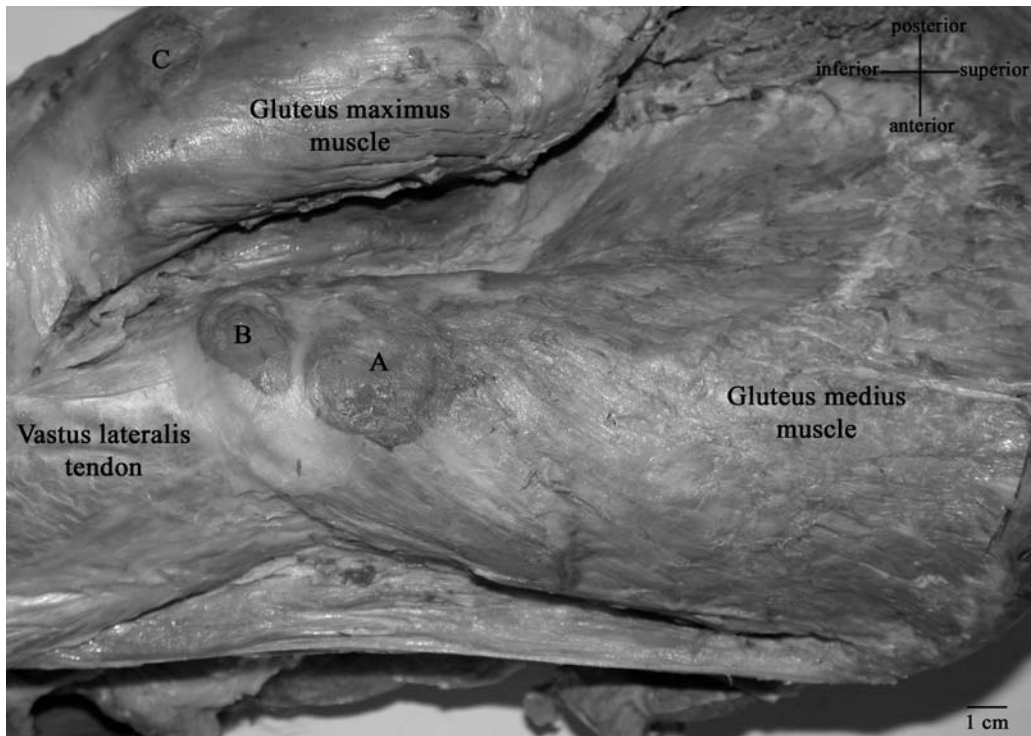


Fig. E-3

The gluteus maximus muscle and the fascia lata have been reflected posteriorly to reveal three underlying bursae that have been injected with blue-colored latex: the deep subgluteus maximus bursa (A), the secondary deep subgluteus maximus bursa (B), and the superficial subgluteus maximus bursa (C).