

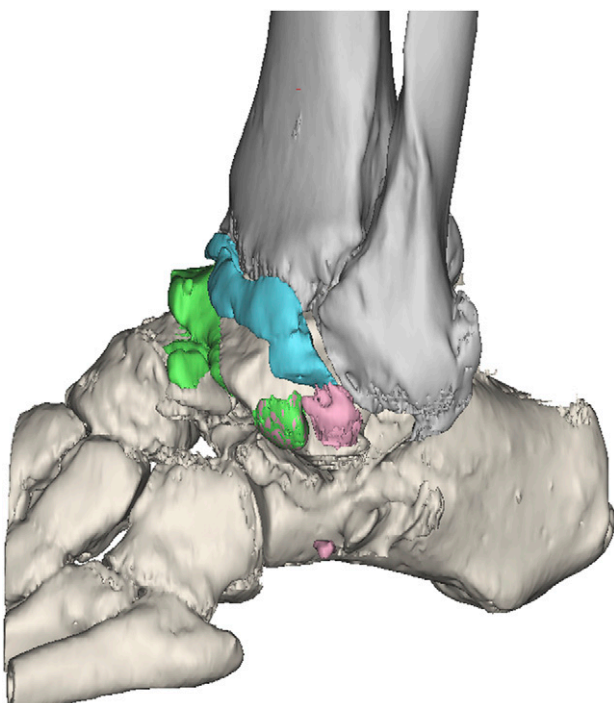Fig. E-1A

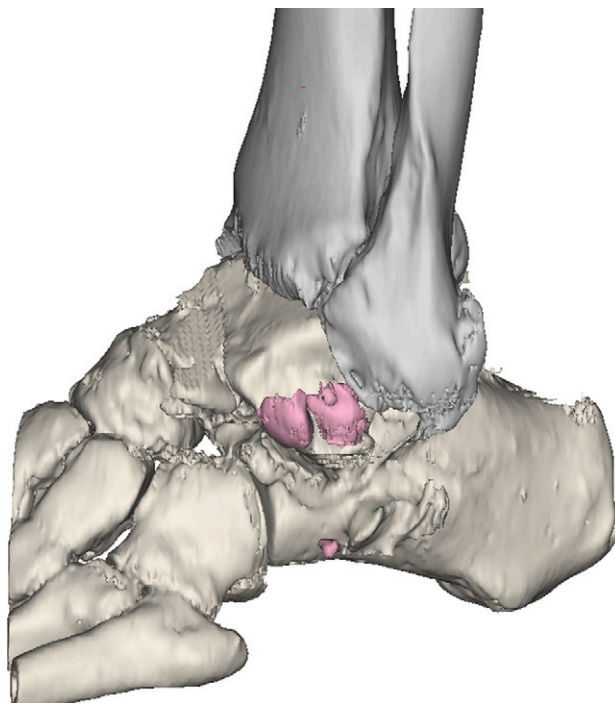


Fig. E-1B

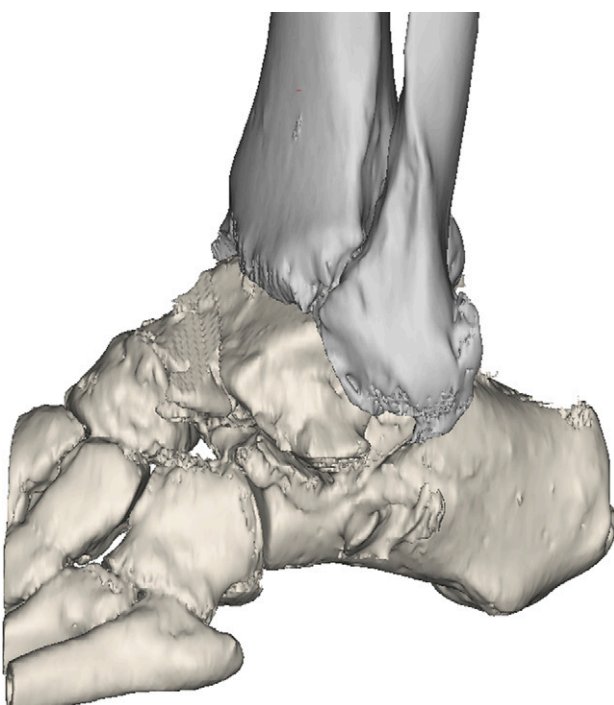


Fig. E-1C

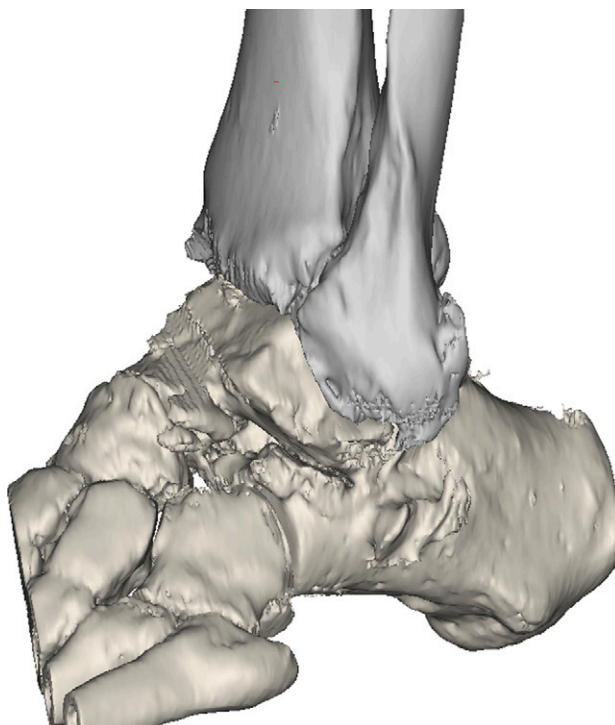


Fig. E-1D

Figs. E-1A through E-1D Three-dimensional computed tomography (CT) scans illustrating lateral gutter impingement. **Fig. E-1A** Preoperative scan showing lateral osteophyte formation on the fibula and the talar process as well as lateral gutter ossicles. **Fig. E-1B** Lateral gutter osteophytes require debridement so that the talus can be rotated back into the ankle mortise. A separate lateral incision may be required for access to these osteophytes. **Fig. E-1C** Open complete lateral debridement of all osteophytes has been performed. **Fig. E-1D** Postoperative scan demonstrating how lateral debridement allows external rotation of the talus to a normal position, reducing hindfoot varus.

TABLE E-1 Ancillary Procedures Performed at the Time of the Index Procedure

	Varus Group (N = 29 of 36 Ankles)	Neutral Group (N = 17 of 36 Ankles)
Calcaneal osteotomy	14	6
First metatarsal osteotomy	19	2
Peroneal tendon transfer	3	2
Tibialis posterior release	1	1
Plantar fascia release	6	1
Open lateral debridement	5	2
Lateral ligament reconstruction	4	3
Achilles tendon lengthening	2	5
Subtalar fusion	3	1
Talonavicular fusion	1	2
Midfoot fusion	—	3
Triple fusion	—	1
Total no. of procedures	58	29

TABLE E-2 Complications

	Varus Group (N = 7 of 36 Ankles)	Neutral Group (N = 5 of 36 Ankles)
Intraoperative fracture	1	—
Progressive edge-loading	2	1
Component revision	1	1
Subsidence and/or progressive radiolucency	1	2
Secondary deep infection	2	1

TABLE E-3 Subsequent Procedures

Patient	Sex, Age (yr)	Etiology	Times(s) to Additional Surgery (mo)	Reason(s) for Additional Surgery
Varus group				
1	F, 61	Recurrent ankle sprains	6, 72	Residual hindfoot varus, enlarging tibial cyst
3	M, 72	Inflammatory arthritis	18	Infection
7	M, 55	Recurrent ankle sprains	30, 44	Lateral impingement, pain and stiffness
9	F, 66	Inflammatory arthritis	1	Subluxation of polyethylene liner
13	F, 56	Fracture	10	Residual hindfoot varus
15	F, 57	Recurrent ankle sprains	6, 27	Residual hindfoot varus, lateral impingement
16	M, 61	Recurrent ankle sprains	30, 32, 37	Lateral impingement, deep infection, ankle fusion
19	M, 74	Recurrent ankle sprains	27	Edge loading and ligament instability
26	M, 63	Inflammatory arthritis	14	Residual hindfoot varus
29	M, 60	Recurrent ankle sprains	18	Lateral impingement and radiographic malalignment
31	M, 64	Recurrent ankle sprains	11	Lateral impingement and ligament instability
32	M, 49	Recurrent ankle sprains	8	Residual hindfoot varus
33	M, 68	Recurrent ankle sprains	3	Residual hindfoot varus and radiographic malalignment
Neutral group				
1	F, 59	Inflammatory arthritis	11	Residual hindfoot varus
7	M, 60	Primary osteoarthritis	43	Enlarging tibial cyst
13	F, 54	Fracture	14	Residual hindfoot varus and radiographic malalignment
18	M, 72	Fracture	25	Edge-loading and residual hindfoot varus
20	M, 65	Recurrent ankle sprains	33	Enlarging talar cyst
26	F, 62	Fracture	6, 8	Infection