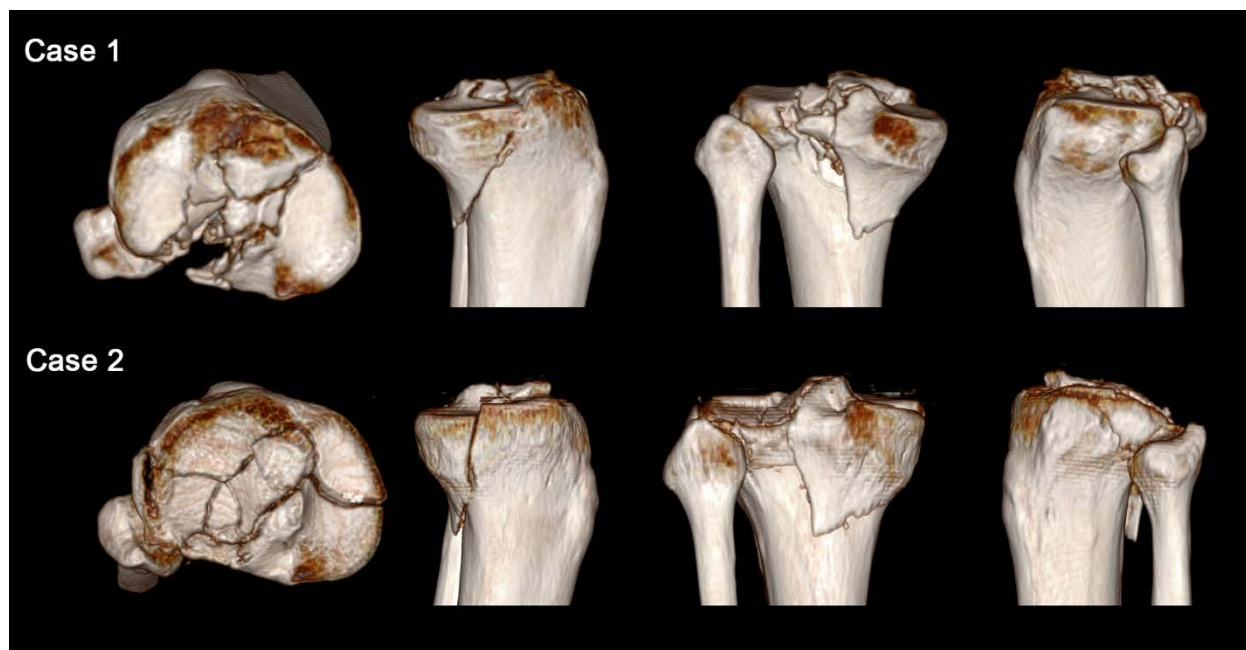
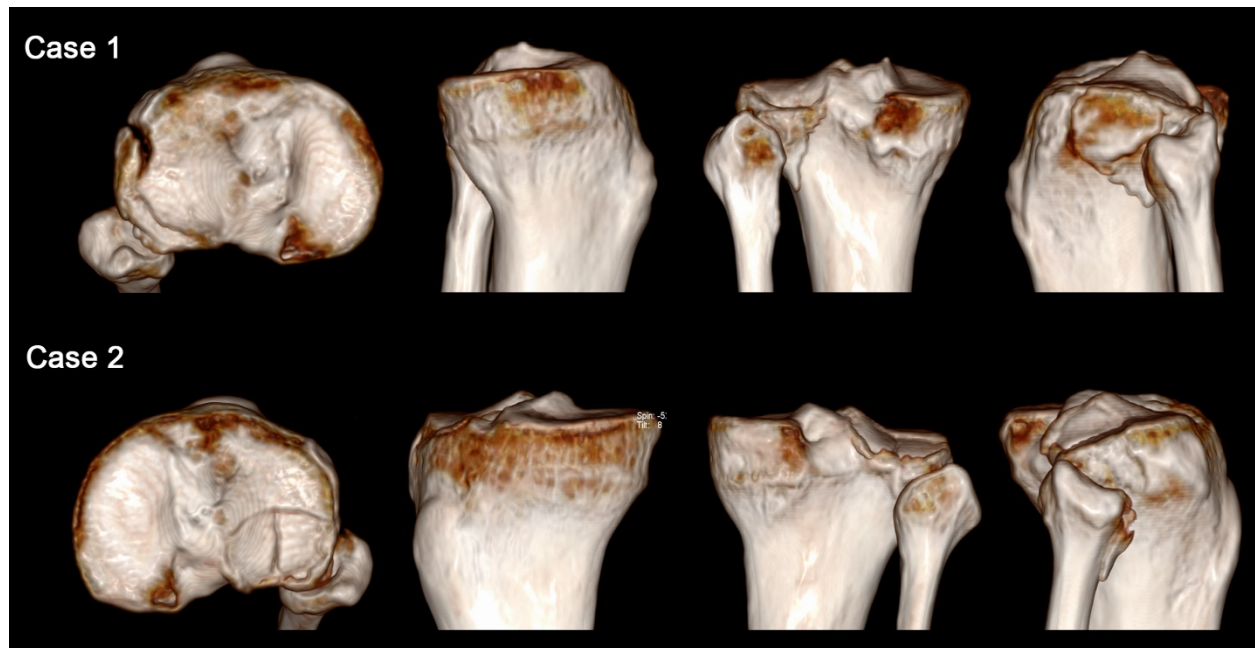


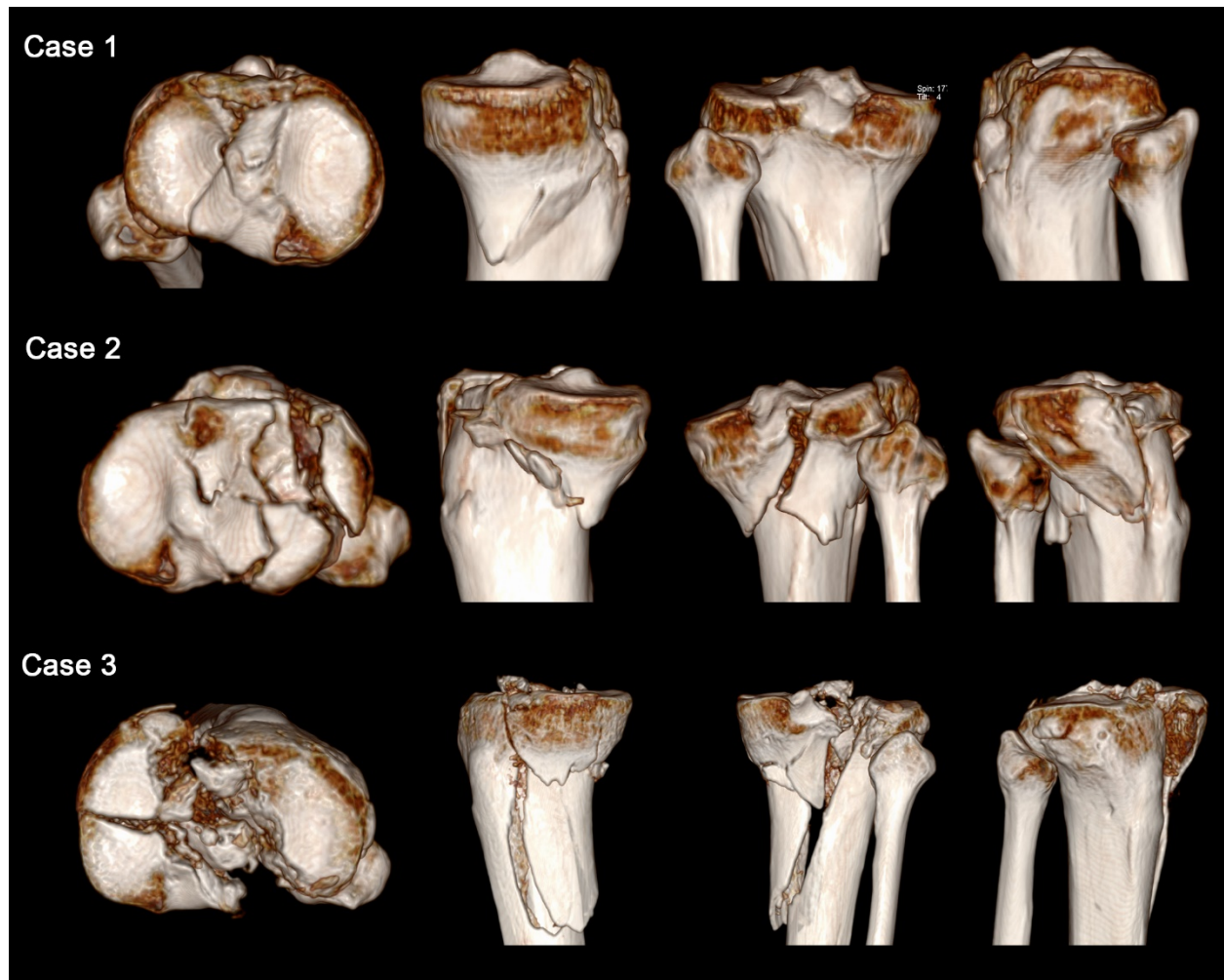
**The following content was supplied by the authors as supporting material and has not been copy-edited or verified by JBJS.**



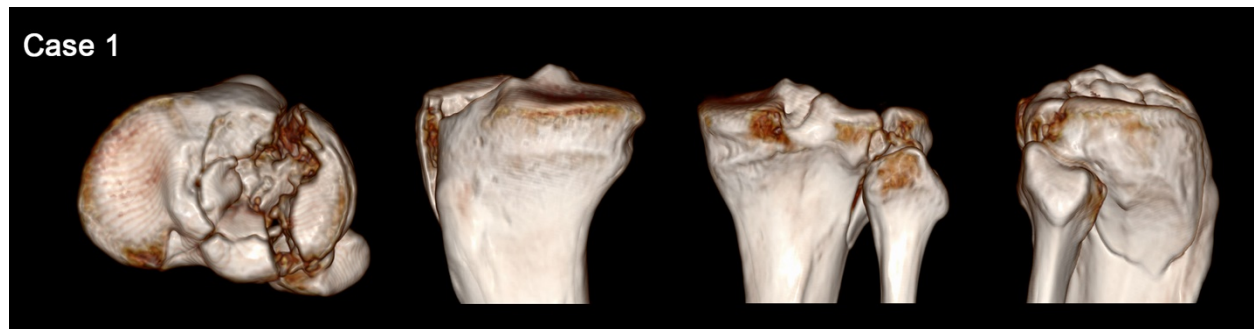
**Supplementary Figure 1.** Representative cases of flexion varus fractures.



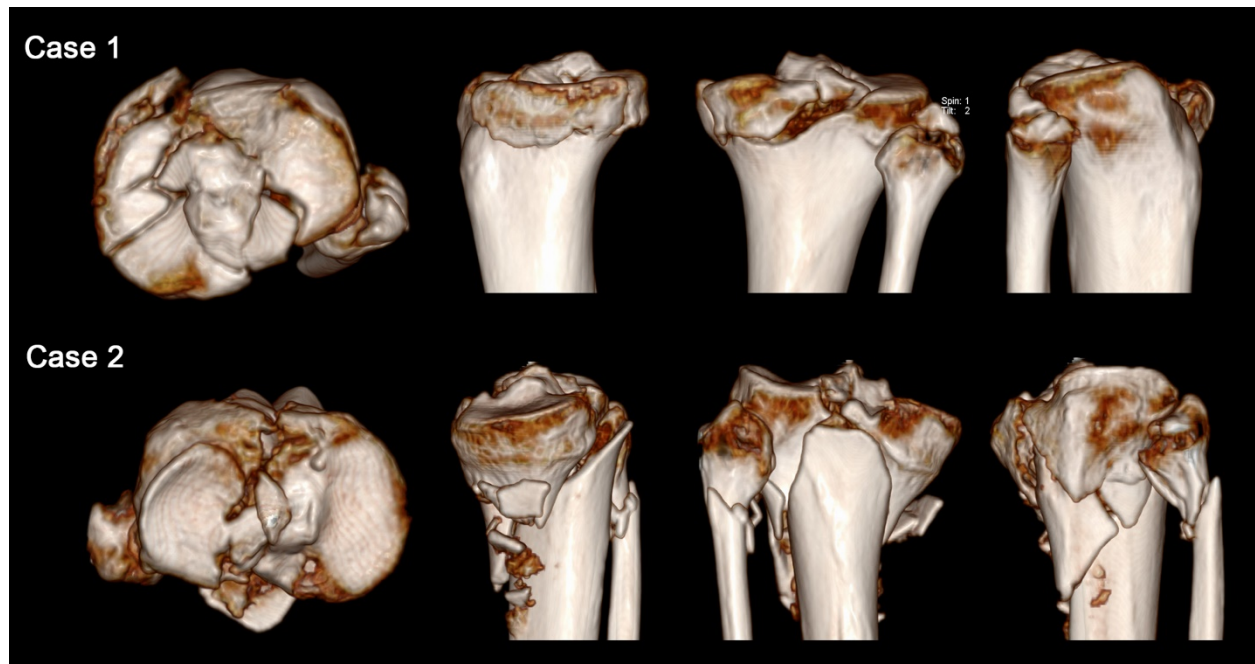
**Supplementary Figure 2.** Representative cases of flexion valgus fractures.



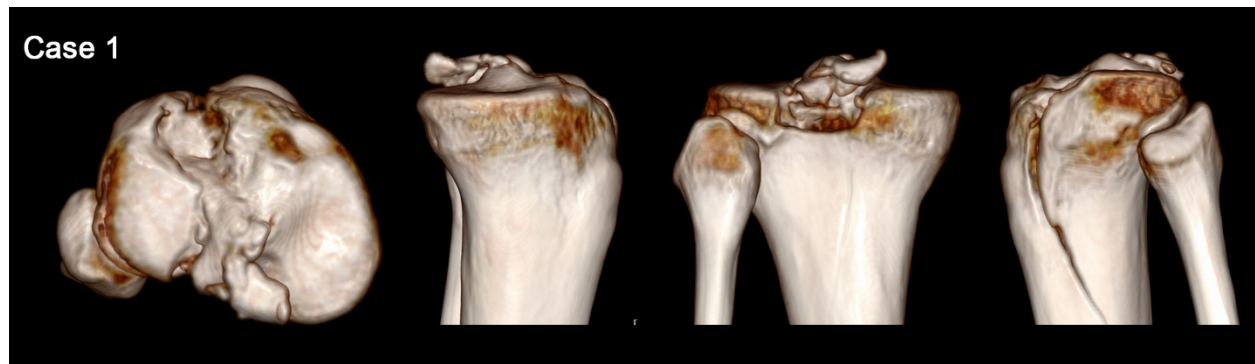**Supplementary Figure 3.** Representative cases of extension varus fractures.



**Supplementary Figure 4.** A representative case of extension valgus fractures.



**Supplementary Figure 5.** Representative cases of hyperextension varus fractures.



**Supplementary Figure 6.** A representative case of hyperextension valgus fractures.