http://dx.doi.org/10.2106/JBJS.20.00883

The following content was supplied by the authors as supporting material and has not been copy-edited or verified by JBJS.

Supplemental Materials

Study animals

The male cynomolgus monkeys (Macaca fascicularis) used for this study had mean body weight and standard deviation of 7.2 ± 0.2 kg and were between 7 to 10 years old. They were obtained from a disease free colony (Covance, Ann Arbor, MI).

Animal Care

The animals were acclimated in an Association for Assessment and Accreditation of Laboratory Animal Care accredited, limited access facility for a minimum of eight weeks prior to initiating the study. The animals were housed in single or paired large cages. They were fed Monkey Chow from an approved supplier supplemented with fruits and had access to water ad libitum. The animals participated in an enrichment program prescribed by the institutional animal care staff.

Physical Examination

All of the animals were weighed and had routine physical examinations performed by the institutional lab animal veterinarian prior to the start of the study. Laboratory screening tests performed prior to enrollment in the study included a baseline CBC, serum chemistry profile, fecal bacteriology and parasitology screen, tuberculosis test, and virus titer screens (herpes B-virus, Measles, Simian Retrovirus, Simian Immunodeficiency Virus, Simian T-cell Leukemia Virus). Only animals determined to be suitable by the institutional veterinarian were enrolled in the study. The general health and well-being of the animals was monitored throughout the study. Prior to surgery, the physical examination was repeated and any pre-surgical laboratory tests deemed to be required by the LAR veterinarian were performed.

BMP-2/CPM and CPM formulation

The rhBMP-2 protein was produced using a CHO cell expression system (Pfizer Inc, Andover, MA). An 0.8 mL volume of saline, 2.65 mg/mL or 8.0 mg/mL BMP-2/buffer was injected into the supplied bladder of the sterile prepackaged CPM powder kits (ETEX Corp, Cambridge, MA) through the injection cap using a sterile 3 mL syringe and 21 gauge needle to yield a CPM alone paste or a 1.5 mg/mL or 4.5 mg/mL BMP-2/CPM paste concentration, respectively. The saline solution or rhBMP-2/buffer solution was mixed with the CPM powder using digital manipulation of the bladder until a uniform paste was obtained. The combined volume of the 0.8 mL rhBMP-2/buffer and 1.25 grams of CPM powder yielded approximately 1.4 mL of paste. The injection cap was removed from the bladder containing the rhBMP-2/CPM paste. The plunger was then removed from a sterile 1.0 mL syringe. Approximately 1.0 mL of the rhBMP-2/CPM paste was extruded

into the open barrel of the 1.0 mL syringe by manually compressing the contents of the bladder while holding the open end of the bladder tightly against the open end of the syringe barrel. The plunger was then replaced into the syringe. The formulated BMP-2/CPM paste remained injectable at room temperature for several hours. The 1.0 mL volume was sufficient to treat multiple animals.

Femoropatellar injection

Anesthesia: Food was withheld from the animals for 18-24 hours prior to surgical anesthesia. Pre-operative antibiotics (Cefazolin, 17 mg/kg) and analgesics (Buprenorphine hydrochloride, 0.01-0.03 mg/kg) were given by injection in the muscle (IM). Animals were then pre-anesthetized with atropine (0.04mg/kg, IM), sedated with Telazol (3-5mg/kg, IM). An endotracheal tube was placed and general anesthesia was maintained with Isoflurane/O_2. An intravenous catheter was placed in the brachial vein and Lactated Ringer's solution was administered intravenously throughout surgery.

Pre-injection preparation: The hair from the mid-femur to the mid-tibia was removed with a clipper and the presurgical preparation of the skin was performed in the surgery prep area using chlorhexidine surgical scrub followed by a 70% alcohol rinse. The animals were then brought into the surgery suite and were placed in lateral recumbency with the torso supported by the surgery table. The distal limbs were positioned to hang off the end of the surgery table. The cables for the ECG, rectal temperature probe and lingual blood gas detector were then placed and connected to the monitoring devices. Intraoperative monitoring of vital signs was performed throughout the injection procedure and was continued until the animals were recovered from general anesthesia and became ambulatory. The upper hind limb was then suspended vertically by the foot from an IV pole using non-sterile elastic wrap around the feet with a length extending up to the top of the IV pole. A 360-degree sterile operative skin preparation was performed from the middle of the calf to the groin with the limbs in the suspended position using chlorhexidine solution followed by a saline rinse and chlorhexidine solution spray. The proximal hind limb was covered with sterile towels secured to the skin with staples leaving the knee exposed. The distal hind limb was then covered with sterile elastic wrap extending to the middle of the calf and the limb was released from the IV pole. A sterile drape with a small hole cut to expose the knee was placed over the animal.

Femoropatellar injection technique: The femoropatellar injections were performed with the hind limb supported by the fluoroscope image intensifier. Prior to injection, the knee was placed in flexion and distal border of the patella identified by digital palpation. A 0.045-inch K-wire was inserted percutaneously into the patella at an oblique angle starting approximately 5.0 mm proximal to the distal border of the patella and ending approximately 5.0 mm from the proximal articular surface of the patella. Orthogonal fluoroscopic images were used to confirm proper orientation of the K-wire. The knee was extended and the tip of the K-wire was then advanced into the femoropatellar joint using fluoroscopic guidance. The K-wire was then removed and an 18-gauge spinal needle was inserted into the K-wire track. The tip of the needle was positioned within the femoropatellar joint using fluoroscopic guidance (**Fig. S1-A and S1-B**). The designated treatment was administered into the femoropatellar joint with a 1.0 mL syringe attached to the spinal needle. Radiodense rhBMP-2/CPM was visible in the femoropatellar joint following

injection (**Fig. S1-C**). The femoropatellar joint was mobilized into flexion and extension following withdrawal of the spinal needle in order to distribute the rhBMP-2/CPM within the joint. Radiodense CPM was apparent radiographically in the posterior joint capsule of the femorotibial joint in most of the animals following mobilization of the joint. The presence of CPM in the femorotibial joint following injection of the femoropatellar joint confirms communication between these two joint compartments of the knee.

Post-injection care

The animals were monitored in a temperature controlled ICU unit during recovery from anesthesia. Postoperative antibiotics (Cefazolin, 17 mg/kg BID) were given IM for two days after surgery. All of the animals received buprenorphine for pre-operative analgesia at 0.03 mg/kg IM. The animals were continued on buprenorphine BID for two full days after treatment regardless of clinical signs. Animals were monitored daily for joint swelling, lameness, apatite and general health. Buprenorphine and/or Flunixin meglumine at 0.5 to 1.0 mg/kg IM was administered on an "as needed" basis for extended analgesia or anti-inflammatory action. Intramuscular injections of tetracycline (25mg/kg) were administered 10 days after treatment and intramuscular injections of calcein (5 mg/kg) were administered fourteen and three days prior to euthanasia.

Tissue Harvest

The animals were perfused with paraformaldehyde following euthanasia to obtain better fixation of the tissue for evaluating cellular responses. The animals were first pre-anesthetized with intramuscular injections of Telazol (5 mg/kg) and Buprenex (0.01 mg/kg). Following preanesthetic induction, a 22-gauge intravenous catheter was placed in the brachial vein. The animals were then anesthetized with an intravenous injection of pentobarbital (15 mg/kg). Once general anesthesia was achieved, 100 U/kg of Heparin sulfate was administered via the peripheral catheter 5 minutes prior to euthanasia. Euthanasia was performed with an intravenous injection of 100 mg/kg pentobarbital. After confirmation of death, skin incisions were made between the 4th to 12th ribs. The ribs were cut from both sides and the diaphragm was removed to expose the heart. An infusion gavage tube was placed into the left ventricle through a stab incision made in the wall of the heart. An L-shape hemostat was applied across the gavage tube entry incision to close the left ventricle around the gavage tube. The superior and inferior venocava were then transected to allow evacuation of the blood during perfusion. Two Liters of 4% paraformaldehyde were perfused into the general circulation through the infusion gavage tube with the use of a perfusion pump. The animals were placed in collection container during perfusion and the affluent fixative mixed with blood was channeled into biohazard waste container via a Tygon tube to the collection container. The perfusion time was approximately 10 to 15 minutes. After the perfusion protocol was completed, an osteotomy was made in the distal shaft of the femur and the proximal shaft of the tibia with an oscillating saw. The interposed knee joint was removed with the skin intact. The specimens were then stored in 4% paraformaldehyde fixative solution at 4° C for subsequent gross pathologic and microscopic evaluation. Knee specimens obtained from animals injected with ^{125}I-labeled-BMP-2/CPM were excised in a similar manner following euthanasia without paraformaldehyde perfusion.

Gross Pathology Evaluation

Gross pathologic evaluation was performed by two board-certified veterinary pathologists blinded to the treatment on all the knee specimens to evaluate the articular cartilage and soft tissue components of the joints. A 180º incision made through the cranial aspect of the skin over the knee was extending through the femorotibial joint capsule. The collateral and cruciate ligaments of the joint were incised. A vertical incision was then made on either side of the patella to remove the patella. The femorotibial joint was placed in full flexion and images of the articular surfaces of the proximal tibia and distal femur, as well as the associated synovium and joint capsule were obtained with a digital camera. Digital images were also obtained for the patellar articular surface. Specimens of the lateral and posterior joint capsule and the lateral and medial meniscus were removed for microscopic evaluation.

Histological Evaluation

Synovial specimen preparation: Synovial membrane specimens excised from the lateral and posterior joint capsule were trimmed and positioned in plastic tissue mounting cassettes. The specimens were processed through alcohol gradients (cleared in xylene) under vacuum and gentle agitation in the Fisher LX 120 Automatic Tissue Processor (ThermoFisher Scientific, Waltham, MA). The processed specimens were then imbedded with paraffin and sectioned at 5.0 μm in thickness in a standard microtome. The cut sections were hydrated with a descending concentration of alcohol and distilled water after removing the paraffin with Xylene. The hydrated sections were then mounted on slides, stained with Goldner's Trichrome, Hematoxylin & Eosin and Safranin-O and coversliped with Permount.

Synovial specimen evaluation: Microscopic findings of the synovium were classified with standard pathological nomenclature at 1, 8 and 16 weeks. The degree of synovial hyperplasia, granulomatous inflammation, and synovial fibrosis were graded on a scale of 0 to 5 as normal, slight, mild, moderate, marked, or severe by two board-certified veterinary pathologists blinded to the treatment. Grades of severity for microscopic findings were subjective. Slight was the least extent discernible and severe was the greatest extent possible. Residual CPM was reported as present when visible. Mean values for synovial microscopic measurements were determined by combining the results from the lateral and posterior joint capsule synovial specimens. Synovial vascularization was quantified by counting the total number of visible vessels in a 10X microscopic field. Mean values were determined from three consecutive 10X fields per specimen slide. Quantification of synovial vascularization was performed by a trained histologist (co-author) in a blinded manner.

Metaphyseal specimen preparation: A Low Speed Isomet (Buehler, Lake Bluff, IL) was used to cut the specimens to the appropriate size for imbedding. The proximal end was marked with permanent ink for orientation purposes. Specimen blocks, oriented in the sagittal plane, were cut from lateral to medial for the distal femur and proximal tibial. Each specimen block was placed into labeled processing bags and immersed into fresh 70% ethanol for fixation.

All calcified knee specimen blocks were processed through alcohol gradients (cleared in xylene) under vacuum and gentle agitation in the Fisher LX 120 Automatic Tissue Processor. Specimen

blocks were infiltrated and embedded in methyl methacrylate and allowed to polymerize for three to five days at room temperature following previously published methods with slight modifications[1]. After polymerization was complete, the specimen blocks were removed from their molds and prepared for thin-sectioning. Specimens were sectioned to 5.0 and 7.0 μm thickness using a Riechert/Leica Jung Polycut (Leica Biosystems, Buffalo Grove, IL). Sections from each specimen block were stretched and pressed on gelatin chrome-alum slides and placed in an oven at 45°-50° C overnight (minimum) to ensure tissue adherence to the slides. Slides were then allowed to reach room temperature prior to staining. The 7.0 μm sections were stained with von Kossa and the 5.0 μm section were left unstained or stained with either Goldner's trichrome, Hematoxylin & Eosin or Safranin-O stain.

Metaphyseal specimen evaluation: Static histomorphometry measurements of the distal femora and proximal tibiae were performed using image analysis software (BIOQUANT OSTEO, Bioquant Image Analysis Corp., Nashville, TN) on the von Kossa-stained sections using black and white digital images displayed on a monitor screen[2,3]. Dynamic histomorphometry measurements were performed using the same image analysis software on unstained sections under ultraviolet light fluorescence microscopy to visualize the tetracycline and calcein fluorochrome labels[2,3]. The articular cartilage evaluation was based on the morphologic character and cellular details seen microscopically with the Goldner's trichrome-stained sections**.** Histomorphometry evaluation was performed by a trained histologist (co-author) in a blinded manner.

^{125}I-labeled-BMP-2 distribution

^{125}I-labeled-BMP-2 formulation: ^{125}I from New England Nuclear (Boston, MA) was used to label BMP-2 with Iodogen™ reagent in chloroform according to the manufacturer's recommended protocol (Pierce, Rockford, IL). A trace amount (~ 1:100) of ^{125}I-labeled-BMP-2 was added to unlabeled BMP-2 solution to formulate the ^{125}I-labeled-BMP-2/CPM paste. Trichloracetic acid precipitation of the radiolabeled solution showed >96% precipitable counts, indicating only a small percent of unbound ^{125}I was present. An average of 10 μCi of ^{125}I-labeled-BMP-2 was administered in the 0.1 mL 1.5 mg/mL ^{125}I-labeled-BMP-2/CPM injection volume.

^{125}I-labeled-BMP-2/CPM scintigraphy imaging: Scintigraphic images of excised knee specimens were obtained two weeks after femoropatellar injection of ^{125}I-labeled-BMP-2/CPM with a large field-of-view planar gamma camera (Siemens, Malvern, PA). Images were also obtained from the excised contralateral control knees. A low energy, high resolution collimator was used to minimize scatter and optimize the image spatial resolution. Excised knee specimens were cut along the sagittal plane. One half of the ^{125}I-labeled-BMP-2/CPM-injected specimens was used for scintigraphy imaging. The other half of the ^{125}I-labeled-BMP-2/CPM-injected specimens was used for autoradiography imaging. The cut side of the specimens used for scintigraphy imaging was first photographed using a digital camera. The cut side of the specimen was then placed directly on the gamma camera covered with an paper drape. Scintigraphy images consisting of 25K total counts were then obtained. This count density was selected to optimize special resolution. Digitized images were scaled and superimposed on the digital photographs of the excised

specimens to obtain a composite scintigraphy/digital photo image using Adobe Photoshop. The composite images were used to determine anatomic localization of the ^{125}I-labeled-BMP-2 within the injected and the contralateral control knees.

^{125}I-labeled-BMP-2/CPM autoradiography imaging: Specimen blocks and 5.0 μm thin sections of from the ^{125}I-labeled-BMP-2/CPM-injected excised knees were prepared as described above. Unstained and light Hematoxylin &Eosin-stained slides were dipped into Kodak Type NTB autoradiography emulsion prepared as per the manufacturer's instructions under dark room conditions using Kodak safelight filter illumination (Eastman Kodak, Rochester, NY). Slides were then transferred to a light-tight box containing a drying agent and were stored in a refrigerator at 5-10°C for one month. Exposed slides were evaluated qualitatively for ^{125}I-labeled-BMP-2 distribution using standard light microscopy.

Data analysis

Data were reported as mean ± standard deviation (SD). Pairwise comparisons were evaluated using equal variance, two-tailed paired Student's t-test. Unpaired comparisons were evaluated using equal variance, two-tailed unpaired Student's t-test. Multiple comparisons were evaluated using one-way analysis of variance (ANOVA). Tukey-Kramer post-hoc test was performed when a significant ANOVA group effect was found. Non-parametric unpaired comparisons were evaluated using Mann-Whitney U test. A p-value of ≤ 0.05 was considered as significant for all evaluations. Group sample sizes are reported in their respective table(s), table(s) and supplemental materials. Sample size for animal studies was determined based on previously publications by the authors allowing detection of a significant difference in mean values at a power of 0.80 and an α of 0.05.

Supplemental References

1. Schenk RK, Olah AJ, Herrmann W. Preparation of calcified tissues for light microscopy. In Dickson GR, editor. Methods of Calcified Tissue Preparation. Amsterdam: Elsevier; 1984. p 1-56.

2. Parfitt AM, Drezner MK, Glorieux FH, Kanis JA, Malluche H, Meunier PJ, Ott SM, Recker RR. Bone histomorphometry: standardization of nomenclature, symbols, and units. Report of the ASBMR Histomorphometry Nomenclature Committee. J Bone Miner Res. 1987;2(6):595-610.

3. Li XJ, Jee WS, Li YL, Patterson-Buckendahl P. Transient effects of subcutaneously administered prostaglandin E2 on cancellous and cortical bone in young adult dogs. Bone. 1990;11(5): 353-64.

4. Seeherman HJ, Li XJ, Smith E, Wozney JM. rhBMP-2/calcium phosphate matrix induces bone formation while limiting transient bone resorption in a nonhuman primate core defect model. J Bone Joint Surg Am. 2012 Oct 3;94(19):1765-76.

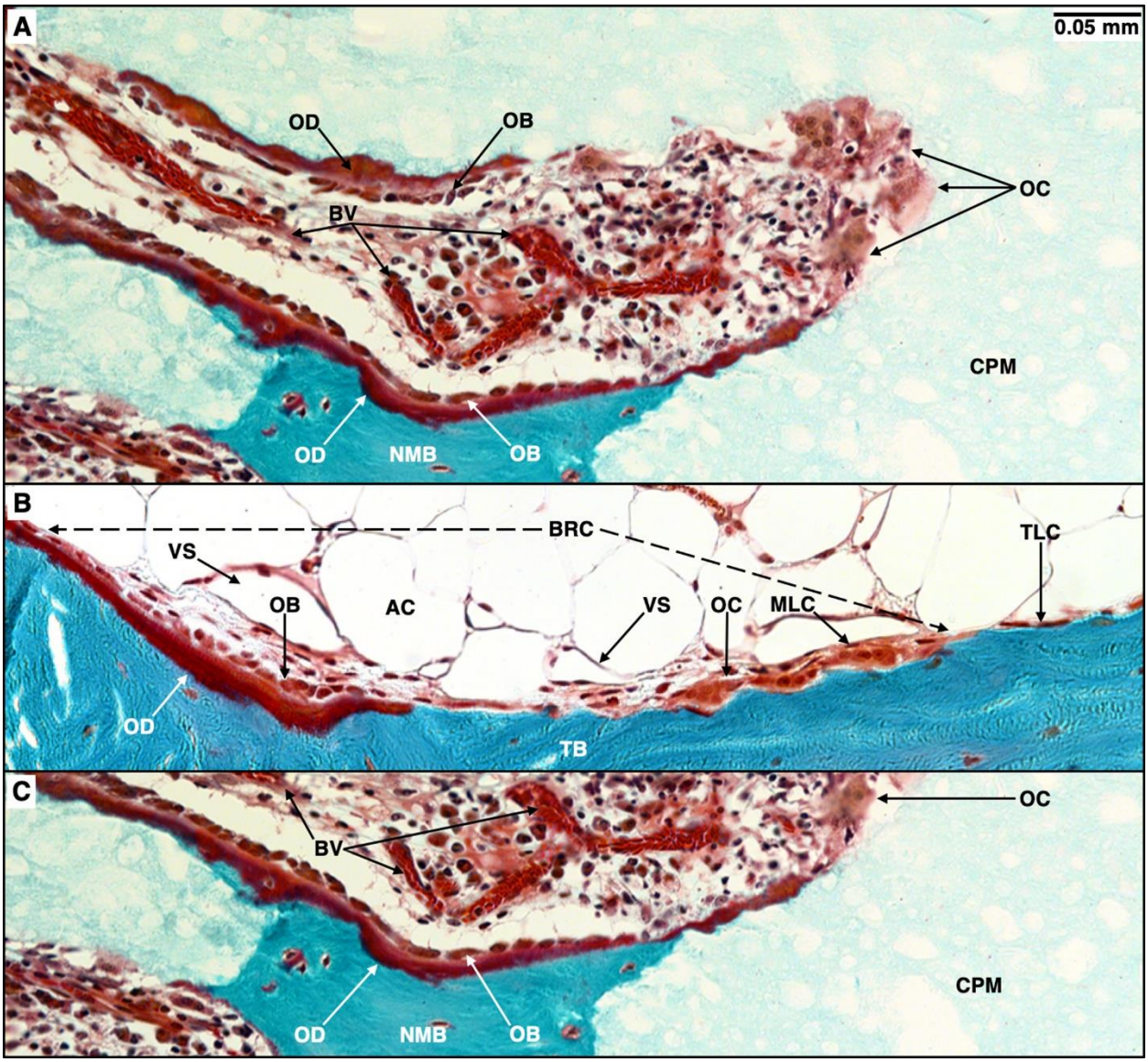

Fig. S1

Figs. S1-A through S1-B Histological comparison of a haversian (osteonal) cortical bone remodeling compartment (BRC) and a trabecular bone remodeling compartment (BRC). **Fig. S1-A** Haversian cortical remodeling unit tunneling through CPM within a nonhuman primate distal radius core defect eight weeks after CPM administration in the core defect[4]. The multinucleated cells consistent with an osteoclast phenotype (OC) are present resorbing CPM at the leading edge of the cutting cone. A blood vessel (BV) is located centrally within the cutting cone. Osteoblasts (OB) actively secreting osteoid (OD) are present along the trailing perimeter of the cutting cone. New mineralizing bone (NMB) is present within the CPM adjacent to osteoid perimeter of the cutting cone. The presence of bone forming cortical BRC moving through inert CPM provides conclusive evidence that all the cellular components of this cutting cone have to be supplied by the central blood vessel. **Fig. S1-B** A trabecular BRC and associated venous sinusoids (VS) consisting of region of osteoclast resorption and a region of osteoblast osteoid bone formation under a common layer of marrow lining cells (MLC) contiguous with trabecular lining cells (TLC) on the surface of an adjacent section of quiescent trabecular bone. **Fig. S1-C** The BRC moving across a trabecular surface resembles one half of the haversian cutting cone depicted in **Fig. S1-A** (Goldner's Trichrome Stain).

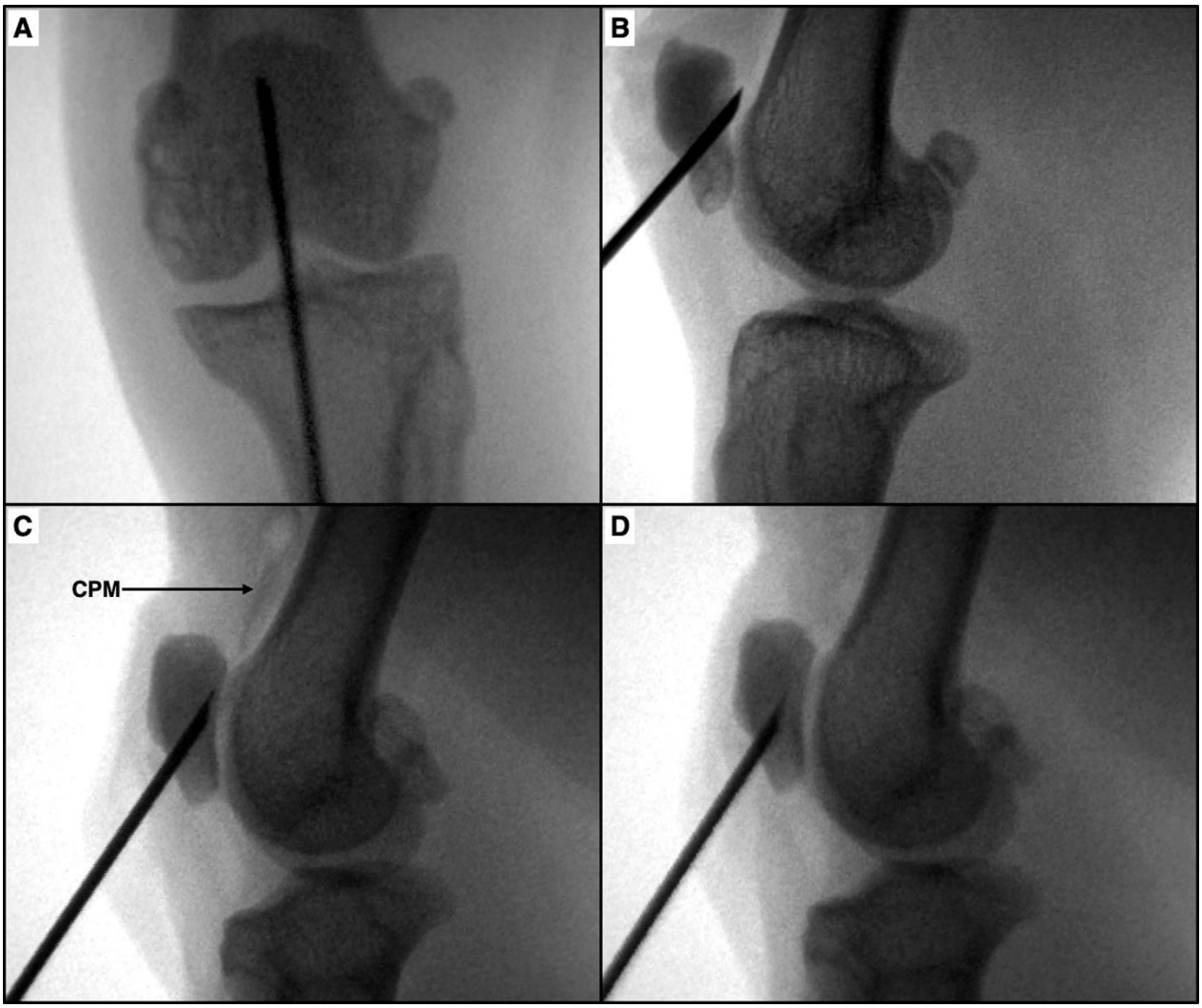

Fig. S2

Figs. S2-A through S2-D Fluoroscopic images of a representative nonhuman primate femoropatellar and femorotibial joint demonstrating trans-patellar intra-articular BMP-2/CPM injection. **Figs. S2-A and S2-B** Anterior to posterior and lateral to medial images demonstrating spinal needle placement prior to injection. **Fig. S2-C and S2-D** Lateral to medial images demonstrating radiodense CPM within the femoropatellar immediately after injection and dispersion of the radiodense CPM within the femoropatellar and femorotibial joints after flexion of the joint five minutes after injection.

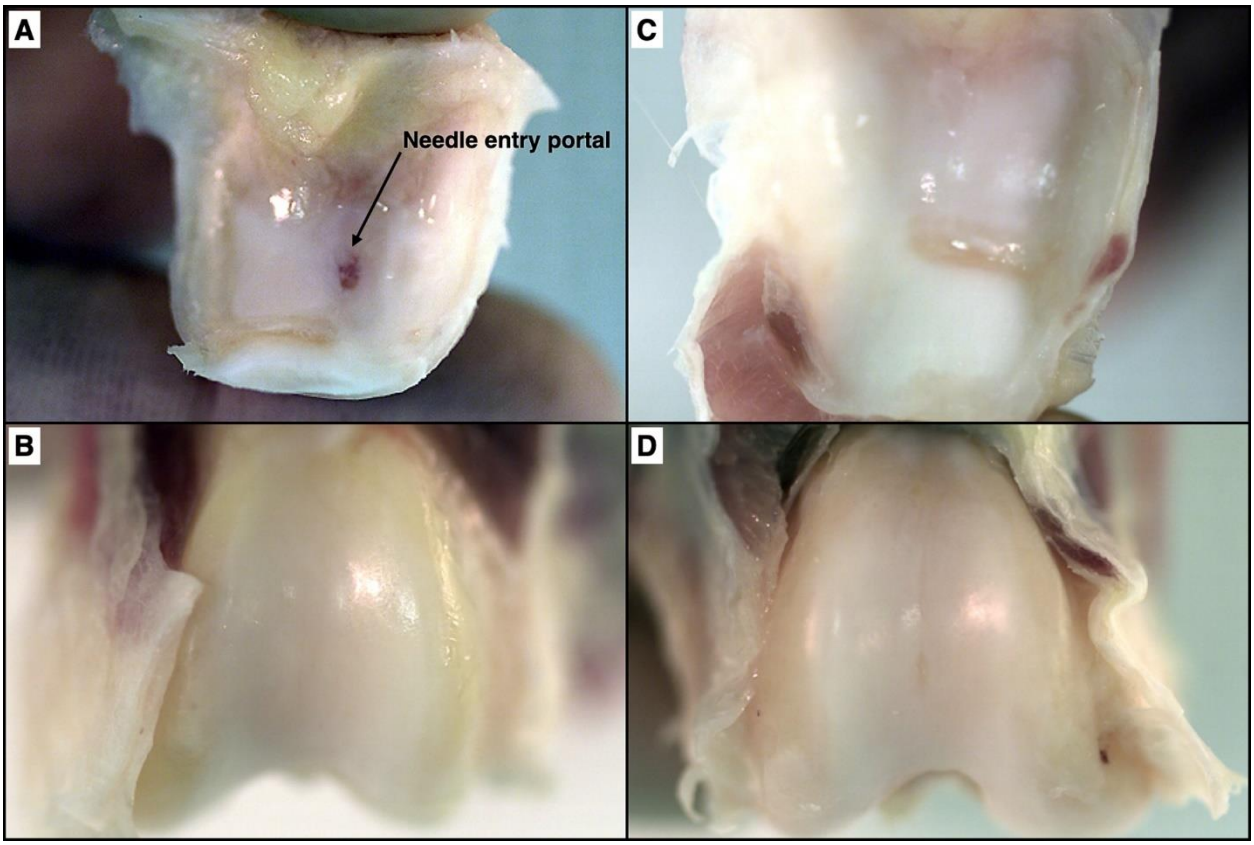

Fig. S3

Figs S3-A through S3-D Photographs of representative nonhuman primate femoropatellar joints harvested 8 and 16 weeks after femoropatellar injection of 1.5 mg/mL BMP-2/CPM. **Figs. S3-A and S3-B** Normal appearing patellar and trochlear ridge articular cartilage 8 weeks after 1.5 mg/mL BMP-2/CPM-treatment. The needle entry portal is present in the patellar articular cartilage. (**Figs. S3-C and S3-D**) Normal appearing patellar and trochlear ridge articular cartilage of the contralateral joint 16 weeks after 1.5 mg/mL BMP-2/CPM treatment. The entry portal in the cartilage is no longer visible at 16 weeks in this animal's patella. The thin centrally located linear superficial cartilage abrasion in the trochlear groove may have been caused by the injection needle.

http://dx.doi.org/10.2106/JBJS.20.00883

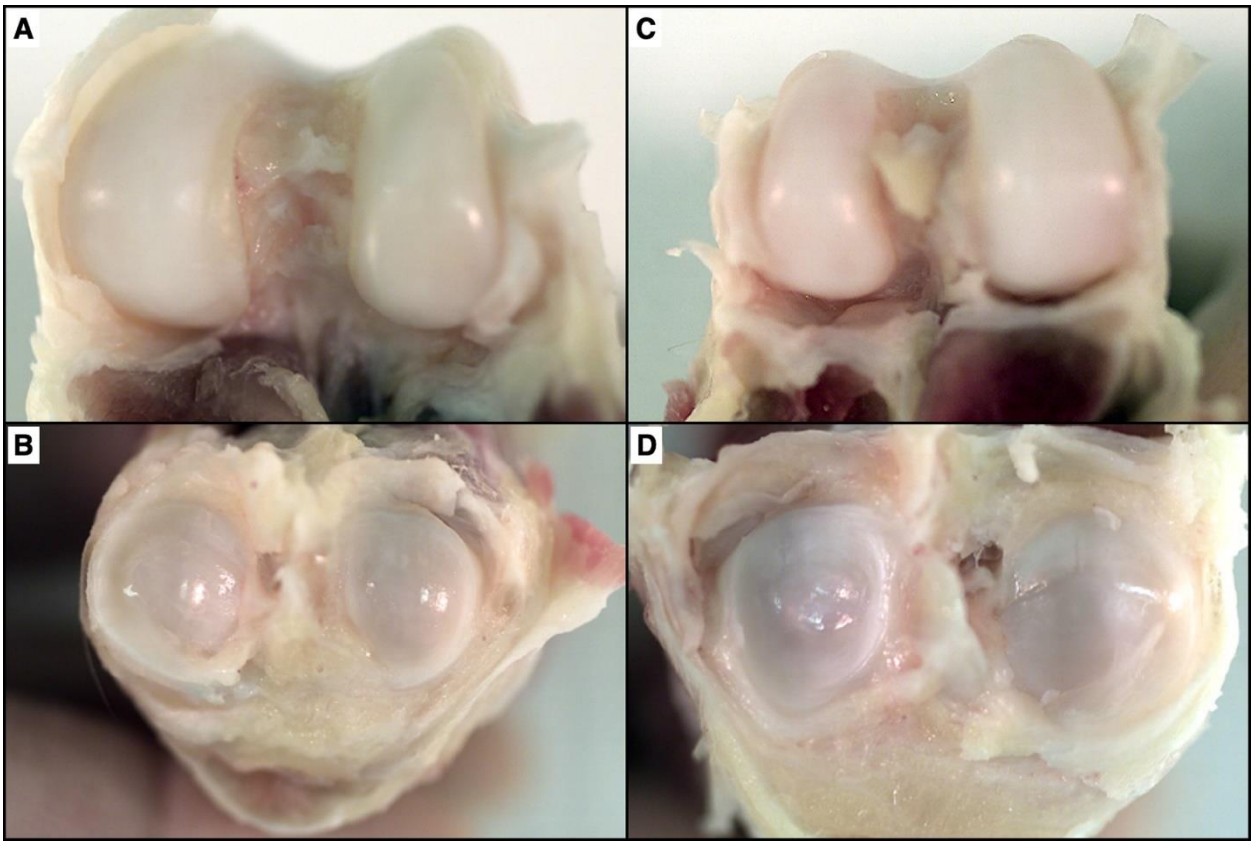

Fig. S4

Figs. S4-A through S4-D Photographs of representative nonhuman primate femorotibial joints harvested 8 and 16 weeks after femoropatellar injection of 1.5 mg/mL BMP-2/CPM. **Figs. S4-A** Normal appearing femoral condylar articular cartilage, proximal tibia articular cartilage and menisci 8 weeks after 1.5 mg/mL BMP-2/CPM-treatment. (**Figs. S4-C and S4-D**) Normal appearing femoral condylar articular cartilage, proximal tibia articular cartilage and menisci 16 weeks after 1.5 mg/mL BMP-2/CPM-treatment.

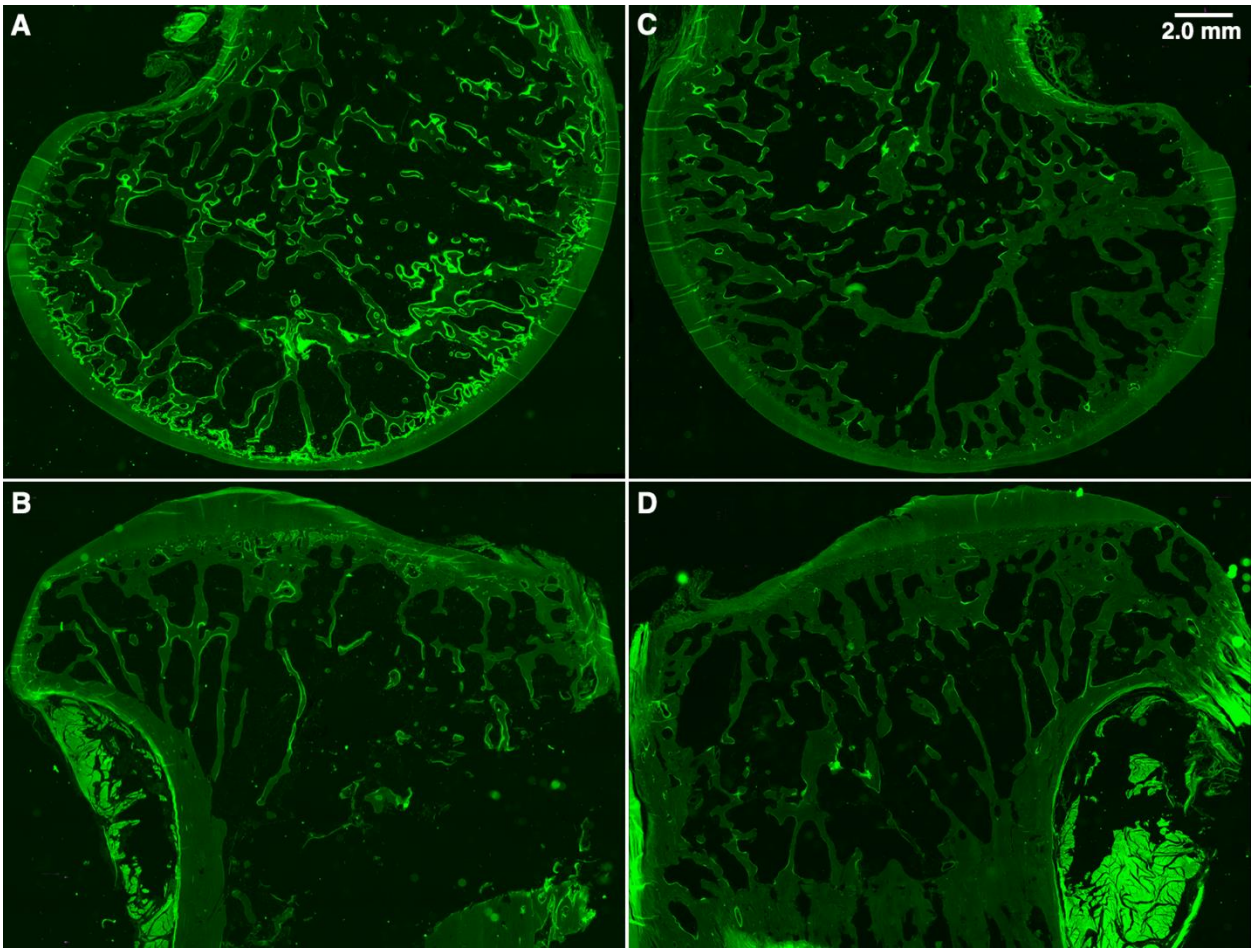

Fig. S5

Figs. S5-A through S5-D Histological appearance of fluorochrome-labeled uptake in the distal femur and proximal tibia specimen from the same nonhuman primate 1.5 mg/mL BMP-2/CPM-treated and contralateral saline-treated femorotibial joints presented in figure 6 eight weeks after treatment. **(Figs. S5-A and S5-B)** Fluorochrome label uptake in the distal femur and proximal tibia of the BMP-2/CPM-treated joint. **Figs. S5-C and S5-D** Fluorochrome label uptake in the distal femur and proximal tibia from the contralateral saline-treated joint. The dramatic increase in fluorochrome-labeled surfaces in the BMP-2/CPM-treated knee compared to the contralateral control is consistent with the corresponding increase in surfaces with formation bone remodeling compartments (FBRCs) observed in the BMP-2/CPM versus contralateral control-treated knees (Fig. 6)(unstained sections under ultraviolet light illumination).

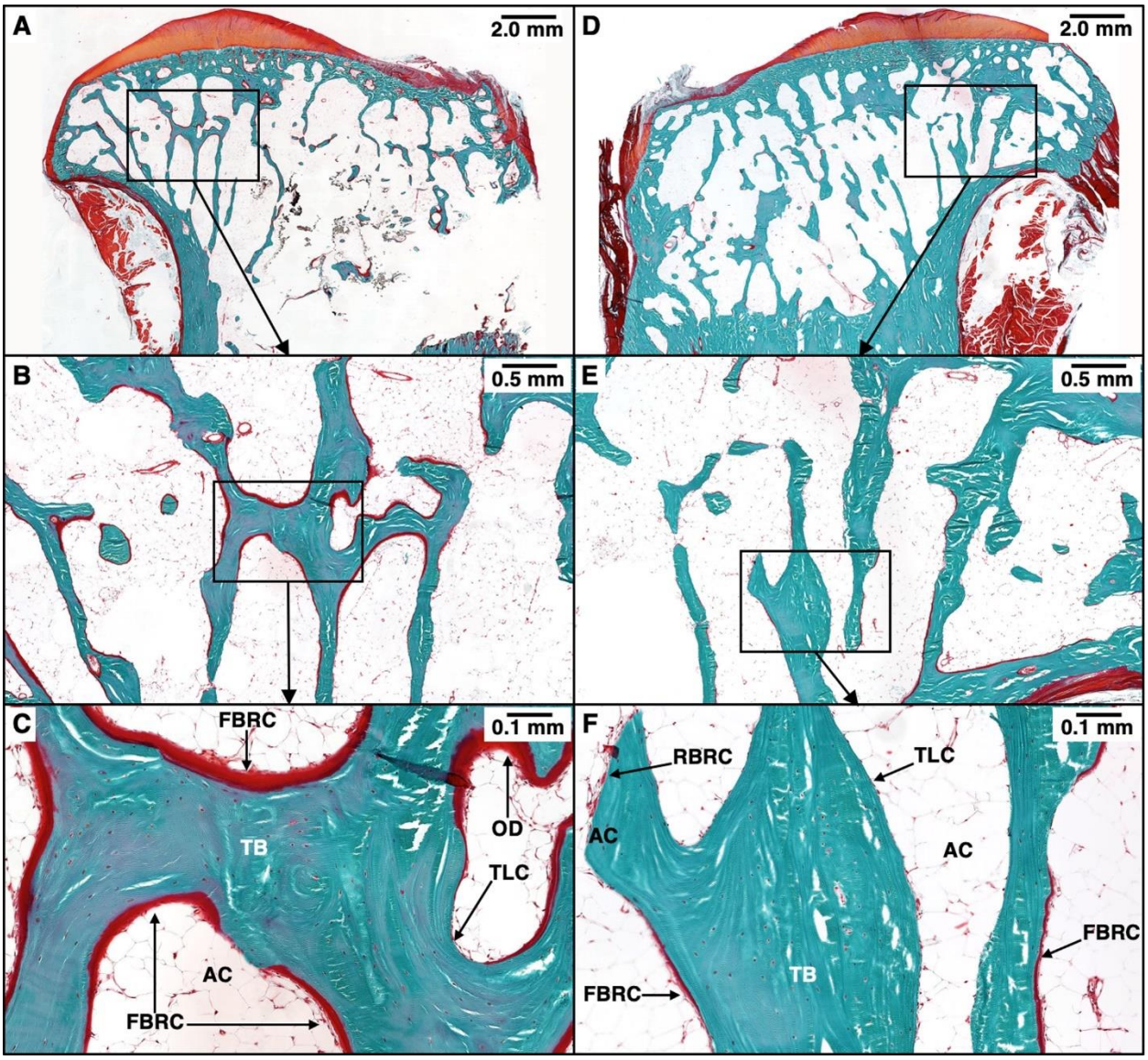

Fig. S6

Figs. S6-A through S6-F Histological appearance of a proximal tibia specimen from a representative nonhuman primate 1.5 mg/mL BMP-2/CPM-treated and contralateral saline-treated femorotibial joint 8 weeks after treatment. **Figs. S6-A, S6-B and S6-C** Trabecular bone and quiescent marrow stroma, consisting primarily of adipose cells (AC), in the proximal tibia from a 1.5 mg/mL BMP-2/CPM-treated femorotibial joint. Extensive formation bone remodeling compartment (FBRC) activity and associated increased osteoid (OD) surfaces are present on the majority of the pre-existing trabecular bone surfaces (Fig. S6-C). The marrow stroma remained quiescent despite the increased FBRC activity. **Figs. S6-D, S6-E and S6-F** Trabecular bone and marrow stroma in the corresponding region of the proximal tibia from the contralateral saline-treated femorotibial joint. The majority of the bone surfaces are covered with trabecular lining cells (TLC). Occasional FBRC and resorption bone remodeling compartments (RBRC) are also present. (Goldner's Trichrome Stain).

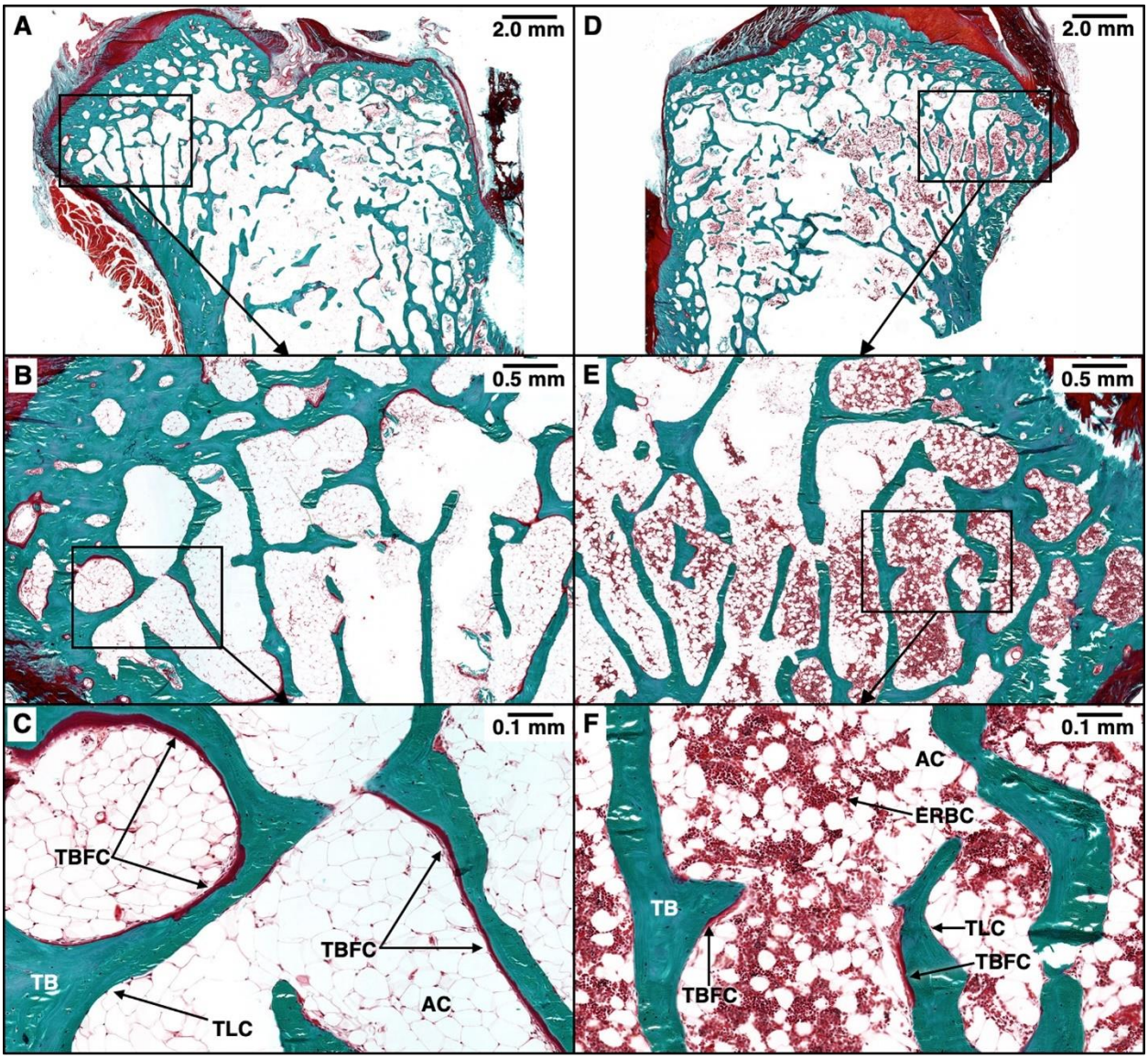

Fig. S7

Figs. S7-A through S7-F Histological appearance of a proximal tibia specimen from a representative nonhuman primate CPM-treated and contralateral saline-treated femorotibial joint 8 weeks after treatment. **Figs. S7-A, S7-B and S7-C** Trabecular bone and quiescent marrow stroma, consisting primarily of adipose cells (AC), in the proximal tibia of a CPM-treated femorotibial joint. The number of formation bone remodeling compartments (FBRC) and associated osteoid (OD) surfaces is increased compared to the contralateral control but is less than was observed in the BMP-2/CPM-treated joints (Fig. S6, Table SII). The marrow stroma remained quiescent despite the increased FBRC activity. **Figs. S7-D, S7-E and S7-F** Trabecular bone in a corresponding region of the proximal tibia from the contralateral saline-treated femorotibial joint. The majority of the bone surfaces are covered with trabecular lining cells (TLC). Occasional FBRCs are also present. The increased amount of extravasated red blood cells (ERBC) in the marrow stroma may be a euthanasia related perfusion fixation artifact. (Goldner's Trichrome Stain).

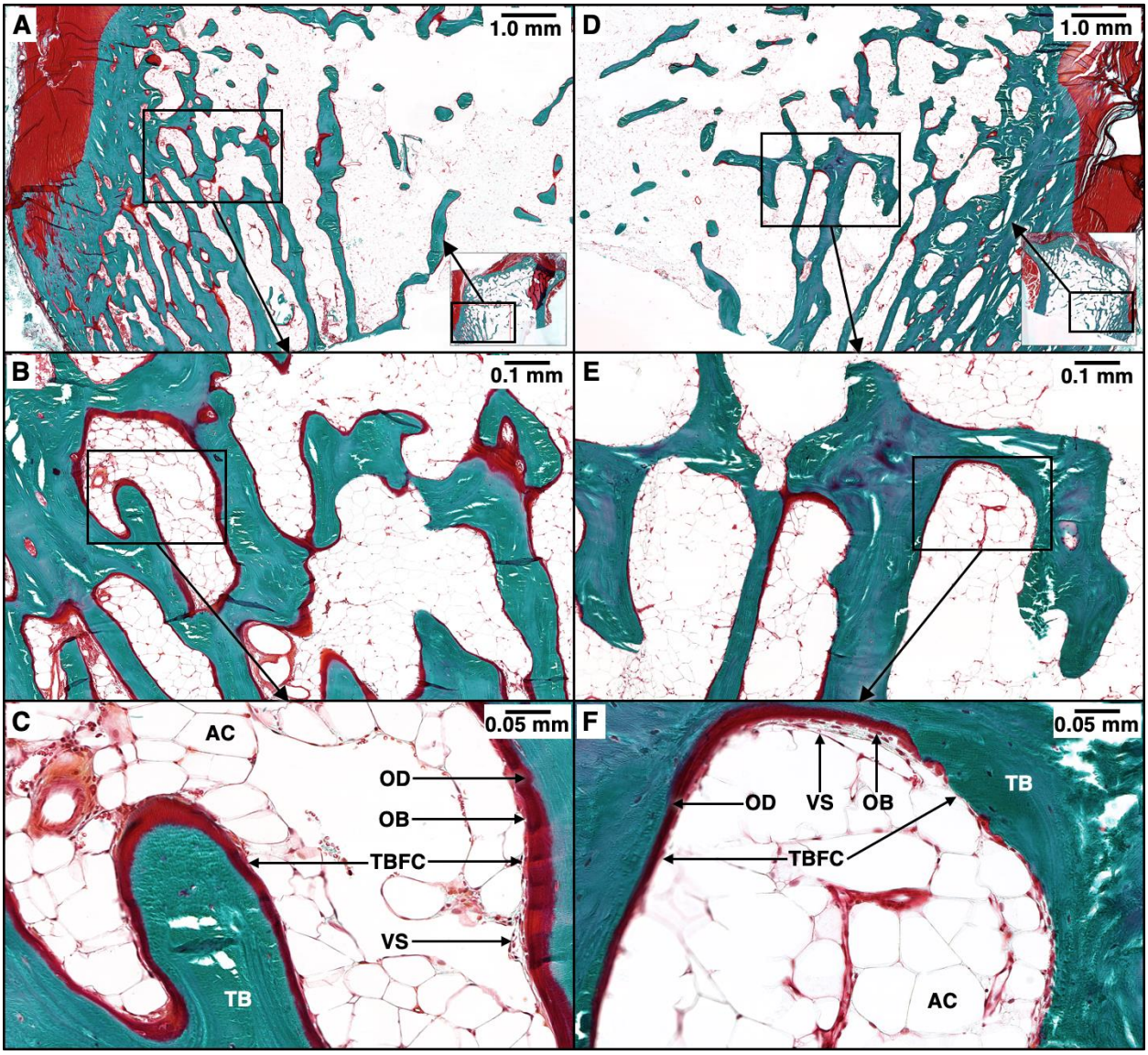

Fig. S8

Figs. S8-A through S8-F Histological appearance of a proximal tibia specimen from a representative nonhuman primate 8 weeks after injection of 4.5 mg/mL BMP-2/CPM in one femorotibial joint and 16 weeks after injection of 4.5 mg/mL BMP-2/CPM in the contralateral femorotibial joint. **Figs. S8-A, 8-B and 8-C** Trabecular bone (TB) and quiescent marrow stroma, consisting primarily of adipose cells (AC), in the proximal tibia 8 weeks after injection of 4.5 mg/mL BMP-2/CPM femorotibial joint. Trabecular bone formation compartments (TBFC) containing osteoblasts (OB), associated increased osteoid (OD) surfaces and paratrabecular venous sinusoids (VS) are present on the majority of the pre-existing trabecular bone. **Figs. 8-D, 8-E and 8-F** Trabecular bone and quiescent marrow stroma in the corresponding region of the proximal tibia 16 weeks after injection of 4.5 mg/mL BMP-2/CPM in the contralateral femorotibial joint. The number of TBFCs with OBs and associated osteoid surfaces is decreased at 16 weeks compared to the contralateral proximal end of the tibia eight weeks after BMP/CPM femorotibial injection (Table SIII)(Goldner's Trichrome Stain).

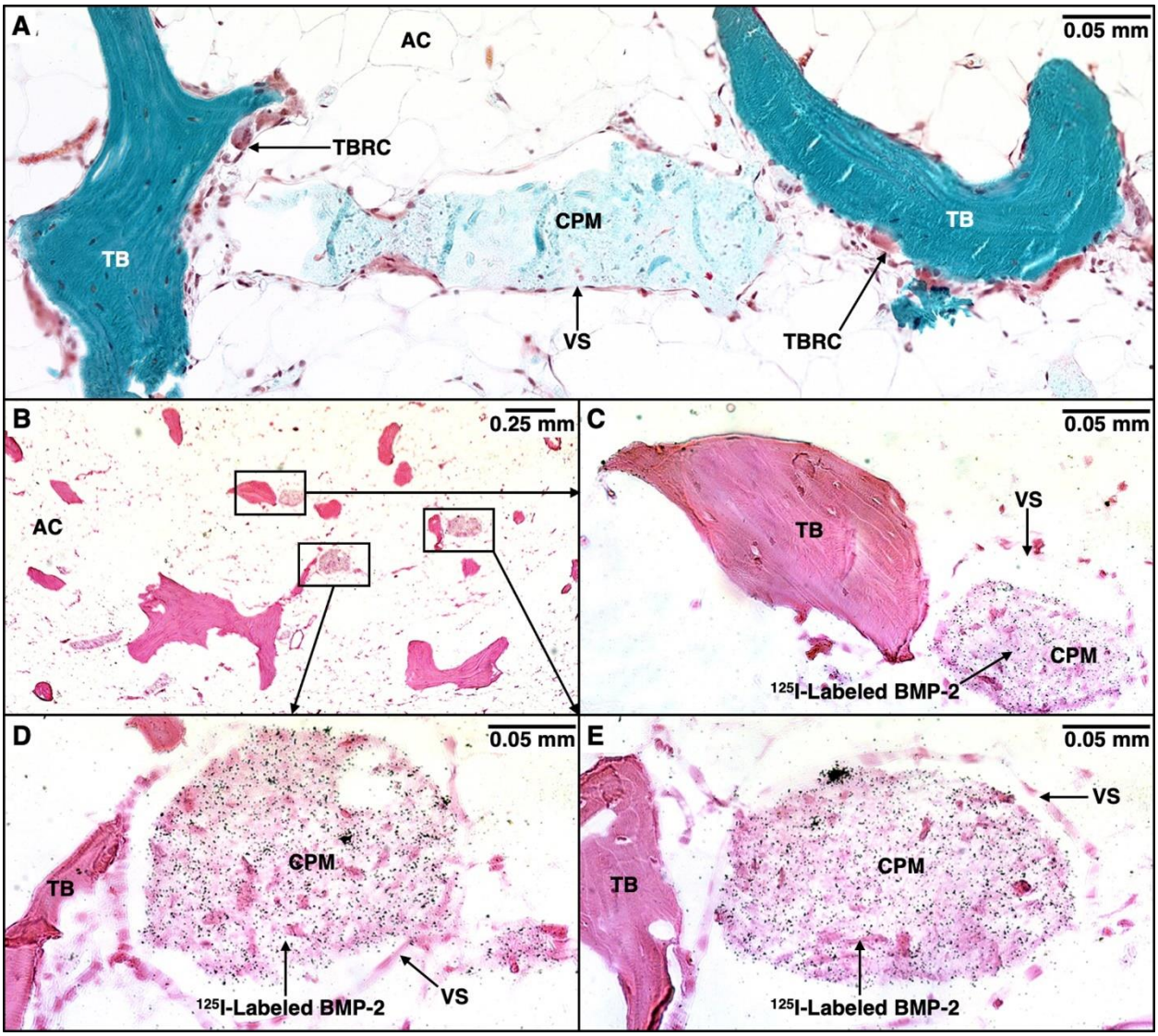

Fig. S9

Figs. S9-A through S9-E Histological appearance of trabecular bone and marrow stroma from a representative distal femur 2 weeks following intra-articular injection of ^{125}I-labeled-BMP-2/CPM. **Fig. S9-A** Trabecular bone and marrow stroma, consisting primarily of adipose cells (AC), in the distal femur two weeks after femoropatellar injection of ^{125}I-labeled-BMP-2/CPM demonstrating accumulation of residual CPM within a paratrabecular venous sinusoid (VS) associated with trabecular bone resorption compartments (TBRC) (Goldner's Trichrome Stain). **Figs. S9-B, S9-C, S9-D and S9-E** Counterstained autoradiography histological section of articular cartilage and subchondral bone from a distal femur 2 weeks following intra-articular injection of ^{125}I-labeled-BMP-2/CPM demonstrating co-localization of ^{125}I-label with residual CPM within the metaphyseal paratrabecular venous sinusoids (light Hematoxylin and Eosin stain counter stained autoradiography section to show cellular morphology).

http://dx.doi.org/10.2106/JBJS.20.00883

TABLE SI Histological Quantification of Femorotibial Capsular Synovial/Entheseal Vascularization 8 Weeks After Femoropatellar Intra-Articular Injection of CPM or BMP-2/CPM Compared to Their Contralateral Saline-treated Controls and 8 Weeks After CPM or BMP-2/CPM Treatment Alone*

Group	CPM†‡ (n = 6)	1.5 mg/mL BMP-2/CPM† (n = 3)	4.5 mg/mL BMP-2/CPM† (n = 3)	1.5 mg/mL BMP-2/CPM (n = 4)	4.5 mg/mL BMP-2/CPM (n = 4)	Combined 1.5 mg/mL BMP-2/CPM‡ (n = 7)	Combined 4.5 mg/mL BMP-2/CPM‡ (n = 7)
Treated (vessels/10X Field)	16.6 ± 4.0 (a,A)	34.3 ± 2.0 (a)	45.3 ± 4.8 (a)	41.4 ± 4.0	45.5 ± 5.1	38.4 ± 5.0 (B)	45.4 ± 4.0 (C)
Contralateral control (vessels/10X Field)	6.5 ± 1.3 (b)	7.4 ± 0.7 (b)	5.6 ± 1.3 (b)				

*The values are given as the mean and the standard deviation of the number of large venous vessels per 10X microscopic field. Combined 1.5 mg/mL BMP/CPM = the combination of the two 1.5 mg/mL BMP/CPM groups. Combined 4.5 mg/mL BMP/CPM = the combination of the two 4.5 mg/mL BMP/CPM groups. †The values for treated and the values for their respective contralateral control values not sharing the same lower case letter are significantly different. For treated values versus their contralateral control, using the paired t-test, the difference was significant for CMP ($p < 0.0005$), 1.5 mg/mL BMP/CPM ($p < 0.0007$), and 4.5 mg/mL BMP/CPM ($p < 0.003$). ‡The values for CMP, combined 1.5 mg/mL BMP/CPM, and combined 4.5 BMP/CPM not sharing the same upper case letter are significantly different. For the comparison of CPM to combined 1.5 mg/mL BMP/CPM, and 4.5 mg/mL BMP/CPM, using analysis of variance, the group effect = $p < 0.0001$. Using the Tukey-Kramer post-hoc test, the difference between CMP versus combined 1.5 mg/mL BMP/CPM or CPM versus 4.5 mg/mL BMP/CPM was significant ($p < 0.00006$), and the difference between 1.5 mg/mL BMP/CPM versus 4.5 mg/mL BMP/CPM was significant ($p < 0.026$).

http://dx.doi.org/10.2106/JBJS.20.00883

Table SII Histomorphometric Measurements of Proximal Tibial Specimens Eight Weeks After Femoropatellar Intra-articular Injection of CPM or Combined BMP-2/CPM Compared to Their Contralateral Saline-Treated Controls*

Group	BV/TV†‡ *(%)*	TbTh†‡ *(μm)*	OS†‡ *(%)*	MS†‡ *(%)*	MAR†‡ *(μm/d)*	BFR†‡ *(%/yr)*
CPM (n = 6)	18.4 ± 3.2 (a)	137 ± 24 (a)	27.7 ± 6.5 (a)	16.8 ± 6.2 (a)	1.02 ± 0.18 (a)	78.3 ± 22.6 (a)
Contralateral control	17.0 ± 3.2 (a)	128 ± 21 (a)	6.8 ± 3.5 (b)	6.2 ± 2.0 (b)	0.91 ± 0.25 (a)	26.3 ± 12.7 (b)
Percentage change from contralateral control	8.7 ± 8.3 (A)	7.0 ± 7.1 (A)	358 ± 151 (A)	217 ± 200 (A)	15.2 ± 18.5 (A)	297 ± 284 (A)
Combined BMP-2/CPM (n = 6)	20.2 ± 4.5 (a)	132 ± 21 (a)	70.1 ± 14.3 (a)	40.4 ± 12.1 (a)	1.11 ± 0.1 (a)	187.0 ± 66.9 (a)
Combined contralateral control	18.1 ± 3.4 (b)	122 ± 17 (b)	5.7 ± 1.3 (b)	6.3 ± 2.0 (b)	0.94 ± 0.23 (b)	26.7 ± 4.5 (b)
Percentage change from combined contralateral control	11.3 ± 9.2 (A)	8.5 ± 5.9 (A)	1175 ± 289 (B)	615 ± 399 (B)	22.7 ± 22.2 (A)	586 ± 172 (B)

*The values are given as the mean and the standard deviation. BV/TV = bone volume/total volume (measured as area), TbTh = trabecular thickness, OS = osteoid surface, MS = mineralizing surface, MAR = mineral apposition rate, BFR = bone formation rate, CPM = calcium phosphate matrix. The combined BMP/CPM and Combined contralateral control are the values from 1.5 and 4.5 mg/mL BMP-2/CPM groups and their respective contralateral controls, and the percentage change from contralateral control and combined contralateral control is the percentage change of treated values from their respective contralateral controls. The values for 1.5 and 4.5 BMP-2/CPM groups and the values for their respective contralateral controls were combined on the basis that the values for their respective percentage change from the contralateral controls were not significantly different (see Appendix Table SIV). †The values for CPM and combined BMP-2/CPM versus their respective contralateral controls that do not share the same lowercase letters are significantly different. For CPM versus contralateral controls, with the paired t test, the difference was not significant for BV/TV ($p > 0.06$; power = 0.49) , TbTh ($p > 0.06$; power = 0.15), and MAR ($p > 0.17$; power = 0.25), and it was significant for OS ($p < 0.0002$), MS ($p < 0.02$), and BFR ($p < 0.01$). For combined BMP/CPM versus their combined contralateral controls with the paired t-test, the difference was significant for BV/TV ($p < 0.03$), TbTh ($p < 0.02$), OS ($p < 0.00009$), MS ($p < 0.0003$), MAR ($p < 0.002$), and BFR ($p < 0.04$). ‡The values for the percentage change for the CPM and combined BMP-2/CPM groups from their respective contralateral controls that do not share the same uppercase letters are significantly different. For the CPM percentage change from the contralateral controls versus the combined BMP-2/CPM percentage change from the contralateral controls, with the unpaired t test, the difference was significant for OS ($p < 0.0001$), MS ($p < 0.05$), and BFR ($p < 0.05$), and it was not significant for BV/TV ($p > 0.62$; power = 0.08), TbTh ($p > 0.7$; power = 0.06) and MAR ($p > 0.54$; power =0.09).

http://dx.doi.org/10.2106/JBJS.20.00883

Table SIII Histomorphometric Measurements of Distal Femoral Specimens 8 Weeks After Femoropatellar Intra-articular Injection of CPM or BMP-2/CPM Compared to Their Contralateral Saline-Treated Controls*

Group	BV/TV† *(%)*	TbTh† *(μm)*	OS† *(%)*	MS† *(%)*	MAR† *(μm/d)*	BFR† *(%/yr)*
1.5 BMP-2/CPM (n = 3)	34.3 ± 4.1	330 ± 39	71.5 ± 21.1	37.8 ± 14.6	1.06 ± 0.11	131.1 ± 51.1
Contralateral control	31.8 ± 4.1	266 ± 29	10.8 ± 4.5	3.3 ± 1.4	0.8 ± 0.1	7.7 ± 3.8
Percentage change from contralateral control	8.0 ± 5.2 (A)	24.9 ± 17.6 (A)	631 ± 346 (A)	1094 ± 225 (A)	32.4 ± 8.0 (A)	1761 ± 631 (A)
4.5 BMP-2/CPM (n = 3)	33.7 ± 1.0	328 ± 20	68.5 ± 7.8	44.5 ± 13.6	1.1 ± 0.04	149.3 ± 40.3
Contralateral control	31.1 ± 1.9	269 ± 14	11.7 ± 0.8	4.7 ± 0.5	0.81 ± 0.09	10.9 ± 1.8
Percentage change from contralateral control	8.8 ± 4.9 (A)	21.8 ± 2.1 (A)	485 ± 39(A)	847 ± 225 (A)	37.8 ± 20 (A)	1249 ± 229 (A)

*The values are given as the mean and the standard deviation. BV/TV = bone volume/total volume (measured as area), TbTh = trabecular thickness, OS = osteoid surface, MS = mineralizing surface, MAR = mineral apposition rate, BFR = bone formation rate, 1.5 BMP-2/CPM = 1.5 mg/mL BMP-2/CPM group, and 4.5 BMP-2/CPM = 4.5 mg/mL BMP-2/CPM group. The percentage change from contralateral control is the percentage change of the 1.5 mg/mL BMP-2/CPM values or the 4.5 mg/mL BMP-2/CPM values from their respective contralateral controls. †The values for percentage change from their respective contralateral controls that do not share the same lowercase letters are significantly different. For the 1.5 mg/mL BMP-2/CPM percentage change from their contralateral control versus the 4.5 mg/mL BMP-2/CPM percentage change from their contralateral control, using the unpaired Mann-Whitney U test, the difference was not significant for BV/TV ($p > 0.28$; power = 0.05), TbTh ($p > 0.51$; power = 0.06), OS ($p > 0.82$; power = 0.09), MS ($p > 0.27$; power = 0.18), MAR ($p > 0.51$; power = 0.06), and BFR ($p > 0.27$; power = 0.18). Based on these results, the values for the 1.5 and the 4.5 mg/mL BMP-2/CPM groups and the values for their respective contralateral controls were combined (Combined BMP-2/CPM and Combined contralateral control, Table IV).

http://dx.doi.org/10.2106/JBJS.20.00883

Table SIV Histomorphometric Measurements of Proximal Tibial Specimens 8 Weeks After Femoropatellar Intra-articular Injection of BMP-2/CPM Compared to Their Contralateral Saline-Treated Controls*

Group	BV/TV† *(%)*	TbTh† *(μm)*	OS† *(%)*	MS† *(%)*	MAR† *(μm/d)*	BFR† *(%/yr)*
1.5 BMP-2/CPM (n = 3)	16.7 ± 1.7	124 ± 11	64.3 ± 10.4	46.0 ± 14.7	1.16 ± 0.18	224.0 ± 60.3
Contralateral control	15.2 ± 0.8	114 ± 10	4.6 ± 0.9	6.9 ± 2.9	0.96 ± 0.33	28.6 ± 5.3
Percentage change from contralateral control	9.4 ± 9.2 (A)	9.6 ± 6.9 (A)	1316 ± 234 (A)	732 ± 593 (A)	28.8 ± 31.8 (A)	683 ± 139 (A)
4.5 BMP-2/CPM (n = 3)	23.6 ± 3.4	141 ± 28	75.8 ± 17.4	34.7 ± 7.2	1.06 ± 0.19	149.9 ± 58.3
Contralateral control	20.8 ± 2.2	130 ± 20	6.8 ± 0.5	5.8 ± 0.8	0.91 ± 0.16	24.8 ± 3.4
Percentage change from contralateral control	13.3 ± 10.8 (A)	7.5 ± 5.9 (A)	1033 ± 307 (A)	499 ± 82 (A)	16.5 ± 10.7 (A)	489 ± 161 (A)

*The values are given as the mean and the standard deviation. BV/TV = bone volume/total volume (measured as area), TbTh = trabecular thickness, OS = osteoid surface, MS = mineralizing surface, MAR = mineral apposition rate, BFR = bone formation rate, 1.5 BMP-2/CPM = 1.5 mg/mL BMP-2/CPM group, and 4.5 BMP-2/CPM = 4.5 mg/mL BMP-2/CPM group. The percentage change from contralateral control is the percentage change of the 1.5 mg/mL BMP-2/CPM values or the 4.5 mg/mL BMP-2/CPM values from their respective contralateral controls. †The values for percentage change from their respective contralateral controls that do not share the same lowercase letters are significantly different. For the 1.5 mg/mL BMP-2/CPM percentage change from their contralateral control versus the 4.5 mg/mL BMP-2/CPM percentage change from their contralateral control, using the Mann-Whitney U test, the difference was not significant for BV/TV ($p > 0.52$; power = 0.05), TbTh ($p > 0.82$; power = 0.06), OS ($p > 0.12$; power = 0.17), MS ($p > 0.52$; power = 0.08), MAR ($p > 0.82$; power = 0.08), and BFR ($p > 0.12$; power = 0.23). Based on these results, the values for the 1.5 and the 4.5 mg/mL BMP-2/CPM groups and the values for their respective contralateral controls were combined (Combined BMP-2/CPM and Combined contralateral control, Table SII).

http://dx.doi.org/10.2106/JBJS.20.00883

Table SV Combined Histomorphometric Measurements of Proximal Tibial Specimens 8 and 16 Weeks After Femoropatellar Intra-Articular Injection of BMP-2/CPM*

Group (n = 4)	BV/TV† *(%)*	TbTh† *(μm)*	OS† *(%)*	MS† *(%)*	MAR† *(μm/d)*	BFR† *(%/yr)*
Combined 8-wk BMP-2/CPM (n = 8)	18.6 ± 4.3 (a)	127 ± 24 (a)	64.0 ± 18.5 (a)	45.9 ± 6.1 (a)	1.13 ± 0.17 (a)	239.8 ± 33.8 (a)
Combined 16-wk BMP-2/CPM (n = 8)	21.8 ± 4.5 (b)	146 ± 24 (b)	39.5 ± 10.4 (b)	30.1 ± 7.0 (b)	0.92 ± 0.21 (b)	118.5 ± 36.2 (b)
Percentage change from the combined 8-wk value	17.8 ± 8.5	15.8 ± 9.4	-35.9 ± 15.9	-34.7 ± 11.2	-19.0 ± 10.2	-50.4 ± 15.1

*The values are given as the mean and the standard deviation. BV/TV = bone volume/total volume (measured as area), TbTh = trabecular thickness, OS = osteoid surface, MS = mineralizing surface, MAR = mineral apposition rate, BFR = bone formation rate, combined 8-wk and combined 16-wk BMP-2/CPM = the combined 1.5 and 4.5 BMP-2/CPM 8-wk data and the combined 1.5 and 4.5 mg/mL BMP-2/CPM 16-wk data (Table SVI), percentage change from the combined 8-week value = percentage change of the combined 16-week BMP-2/CPM values from their respective contralateral combined 8-week BMP-2/CPM values. Justification for combining the 8-wk 1.5 and 4.5 mg/mL BMP-2/CPM values and the 16-wk 1.5 and 4.5 mg/mL BMP-2/CPM values was based on the lack of a significant difference in the percentage change from the 8-wk values for both groups (Table SVI). †The values for the combined 8-wk and combined 16-wk BMP-2/CPM that do not share the same lowercase letters are significantly different. With the paired t test, the difference was significant for BV/TV ($p > 0.0001$), TbTh ($p > 0.002$), OS ($p < 0.002$), MS ($p < 0.0002$), MAR ($p > 0.0008$), and BFR ($p < 0.0007$).

http://dx.doi.org/10.2106/JBJS.20.00883

Table SVI Histomorphometric Measurements of Proximal Tibial Specimens 8 and 16 Weeks after Femoropatellar Intra-articular Injection of BMP-2/CPM

Group (n = 4)	BV/TV† *(%)*	TbTh† *(μm)*	OS† *(%)*	MS† *(%)*	MAR† *(μm/d)*	BFR† *(%/yr)*
8-wk 1.5 BMP-2/CPM	21.6 ± 5.4	136 ± 32	65.8 ± 26.5	48.8 ± 2.3	1.08 ± 0.16	252.5 ± 18.2
Contralateral 16-week 1.5 BMP-2/CPM	23.7 ± 4.8	151 ± 28	39.1 ± 9.7	33.1 ± 5.7	0.87 ± 0.22	123.4 ± 29.5
Percentage change from the 8-wk value	14.6 ± 3.9 (A)	13.0 ± 8.6 (A)	-35.5 ± 17.6 (A)	-32.4 ± 8.5 (A)	-20.2 ± 8.6 (A)	-50.3 ± 15.3 (A)
8-wk 4.5 BMP-2/CPM	16.4 ± 3.3	118 ± 12	62.2 ± 9.5	43.1 ± 7.8	1.17 ± 0.18	227.0 ± 43.5
Contralateral 16-week 4.5 BMP-2/CPM	19.8 ± 3.7	140 ± 26	39.9 ± 12.7	27.2 ± 7.7	0.96 ± 0.22	113.6 ± 46.2
Percentage change from the 8-wk value	21.1 ± 11.1 (A)	18.6 ± 10.6 (A)	-36.2 ± 16.9	-37.1 ± 14.4 (A)	-17.9 ± 12.8 (A)	-50.5 ± 17.2 (A)

*The values are given as the mean and the standard deviation. BV/TV = bone volume/total volume (measured as area), TbTh = trabecular thickness, OS = osteoid surface, MS = mineralizing surface, MAR = mineral apposition rate, BFR = bone formation rate, 1.5 and 4.5 BMP-2/CPM = 1.5 and 4.5 mg/mL BMP-2/CPM, percentage change from the 8-week value = percentage change of the 16-week 1.5 and 4.5 BMP-2/CPM values from their respective contralateral 8-week values. †The values for the 1.5 and 4.5 BMP-2/CPM percentage change from the 8-week value that share the same uppercase letter are not significantly different. With the Mann-Whitney U test, the difference was not significant for BV/TV ($p > 0.67$; power = 0.15), TbTh ($p > 0.38$; power = 0.11), OS ($p > 0.77$; power = 0.05), MS ($p > 0.77$; power = 0.08), MAR ($p > 0.56$; power = 0.06), and BFR ($p > 0.77$; power = 0.05). Based on these results their corresponding 8-week and 16-week values were combined (combined 8-week BMP-2/CPM and combined 16-week BMP-2/CPM, Table SV).