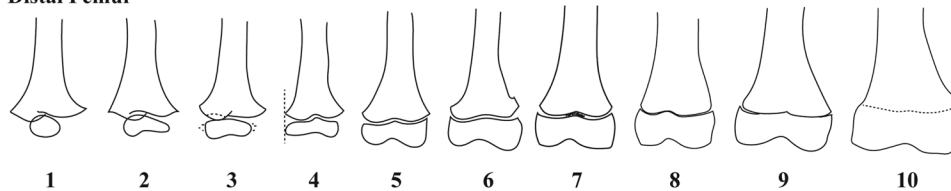
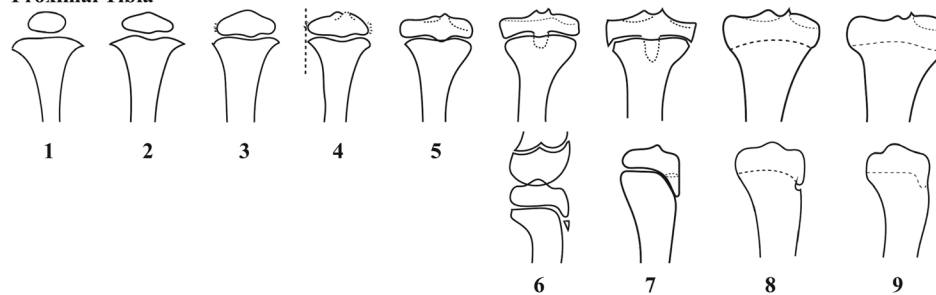


The following content was supplied by the authors as supporting material and has not been copy-edited or verified by JBJS.

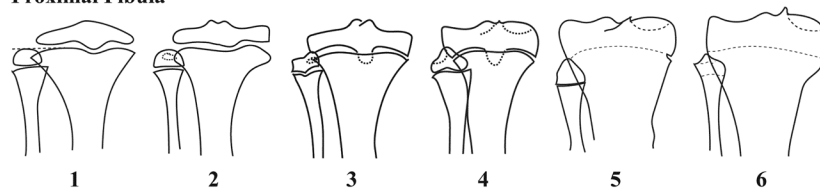
Distal Femur



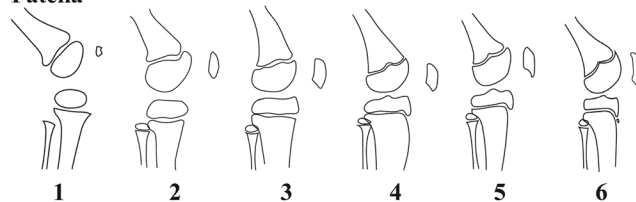
Proximal Tibia



Proximal Fibula



Patella



APPENDIX I – Modified Pyle and Hoerr staging system, images represent a right knee. **Distal femur (PHFem)**: 1) egg shape epiphysis; 2) “wood shoe” appearance of epiphysis; 3) disseminated calcification appears along the medial and lateral epiphyseal margins; 4) lateral aspect of metaphysis and epiphysis aligned in straight vertical line; 5) inner margin of medial half of epiphysis becomes concave and more congruent with medial aspect of metaphyseal edge, junction of lateral margin and subarticular surface of lateral condyle rounded; 6) medial epicondyle readily apparent as small protuberance just below beak-like proximal projection of medial inner bone margin of epiphysis, medial end of metaphysis is a sharp point projecting medially (adductor tubercle); 7) definite rounded angle of demarcation divides medial condyle into a “side” and “subarticular” surface, epiphysal line is fuzzy centrally but terminal plate still distinctly highlighted, articular surface of medial condyle is flat; 8) epiphysis caps shaft closely, triangular enlargements at end of epiphyseal lines virtually disappeared, angle of demarcation between side and subarticular surfaces medially and laterally are sharp angles (becoming more rounded going forward); 9) physal line is extremely thin and difficult to define centrally but can be seen at periphery; 10) Epiphysal-metaphyseal union is complete and physal line completely

replaced by line of fusion of greater density. **Proximal tibia (PHTib):** 1) elliptical outer margin, straight inner margin of epiphysis; 2) medial and lateral aspects of epiphysis begin to flatten obliquely, central indented notch in metaphysis appears; 3) medial aspect of epiphysis becomes more squared off, disseminated calcification along lateral margin of epiphysis/condyle; 4) two tubercles on intercondylar eminence appear, disseminated calcification of medial epiphysis begins, lateral aspect of metaphysis and epiphysis aligned in straight vertical line; 5) tongue of tibial epiphysis has definite outline and projects downward onto tibial metaphysis, lateral margin of epiphysis is flattened and demarcated from subarticular surface by rounded corner, medial epiphyseal margin also becoming flat, small notch forming between the tibial tubercles; 6) with slight flexion of the knee, tibial tubercles project upwards into the intercondyloid fossa (lateral), separate center of ossification in the distal tip of epiphyseal tongue appears (lateral), lateral margin of epiphysis is straight/flat; 7) onset of fusion between the epiphyseal tongue and shaft begins (lateral), epiphyseal line reduced in thickness centrally and fuzzy but terminal plates remain distinct, epiphysis caps the shaft closely and triangular enlargements at the end of epiphyseal lines begin to disappear; 8) epiphyseal-metaphyseal fusion initiated near the center, fusion of epiphyseal tongue with front of tibial shaft nearly completed up to the distal/inferior tip (lateral); 9) epiphyseal-diaphyseal union is complete and epiphyseal line completely replaced by line of fusion of greater density. **Proximal fibula (PHFib):** 1) highest point of margin of epiphysis in the same transverse plane as physeal line of tibia; 2) small indentation in outer/superior margin of epiphysis (first sign of articular facet); 3) articular facet of epiphysis intersects metaphyseal margin of tibia and styloid process of fibula begins to calcify; 4) epiphysis and metaphysis have same transverse diameter; 5) physeal line in fibula extremely thin but still present and begins disappearing in medial to lateral direction; 6) epiphyseal-metaphyseal fusion complete. **Patella (PHPat):** 1) single nodule ossification center; 2) angle of demarcation between posterior/articular surface and inferior surface becomes apparent; 3) postero-inferior surface is flat and makes sharp obtuse angle with posterior surface, superior surface formed and patella now has four surfaces; 4) patella is nearly a parallelogram; 5) inferior surface of patella becomes slightly concave; 6) posterior patella becomes slightly concave and anterior surface is convex anteriorly, superior and inferior surfaces are nearly parallel.

Appendix II. Instructions for evaluating the seven radiographic parameters in the final knee skeletal maturity model.

FemK – “Capping” of the lateral distal femoral epiphysis over the metaphysis

How to evaluate:

- Draw a line tangential to the distal femoral metaphysis undulation (Figure 1 – Line 1)
- Draw a line parallel to Line 1 that intersects the start of the beveled lateral margin of the distal femoral metaphysis (Figure 1 – Line 2)

How to grade:

- Absent – assign value of 0
 - Assign value of 0 if superolateral margin of distal femoral epiphysis is below or touching Line 2 (if any part of margin can be seen above Line 2, value of 1 is assigned) (Figure 2A)
- Incomplete – assign value of 1
 - Assign value of 1 if superolateral margin of distal femoral epiphysis crosses above Line 2, but is not fully congruent with the lateral margin of the metaphysis (Figure 2B)
- Complete – assign value of 2
 - Assign value of 2 if superolateral margin of distal femoral epiphysis cross above Line 2 and is congruent with the lateral margin of the metaphysis (Figure 2C)

FemL – Fusion of the lateral distal femoral physis

How to evaluate:

- Assessment of fusion of the lateral distal femoral physis, which begins to close medially and progresses laterally with age

How to grade:

- Absent – assign value of 0
 - Assign value of 0 if the lateral distal femoral physis is completely open and has not begun to close, evidenced by a radiolucent gap between the epiphysis and metaphysis through the complete extent of the lateral distal femur (Figure 3A)
- Incomplete/Partial – assign value of 1
 - Assign value of 1 if the lateral distal femoral physis has begun to fuse, but fusion is not yet complete, evidenced by the disappearance of the radiolucent gap beginning to disappear medially, but still apparent laterally (Figure 3B)
- Complete – assign value of 2
 - Assign value of 2 if the lateral distal femoral physis has completely fused, evidence by complete disappearance of the radiolucent gap between the epiphysis and metaphysis over the complete extent of the lateral distal femur (Figure 3C)

TibA – Ratio of proximal tibia epiphyseal width to metaphyseal width

How to evaluate:

- First, draw a line from the medial most to lateral most points of the proximal tibial metaphysis at its widest portion (Figure 4 – Line 1)
- Second, draw a line parallel to Line 1 from the medial most to lateral most points of the proximal tibial epiphysis at its widest portion (Figure 4 – Line 2)

How to grade:

- The value for TibA is calculated by dividing the epiphyseal width (value of Line 2) by the metaphyseal width (value of Line 1)
- $TibA = \frac{\text{Proximal Tibia Epiphyseal Width}}{\text{Proximal Tibia Metaphyseal Width}}$

TibN – “Capping” of the lateral proximal tibial epiphysis over the metaphysis

How to evaluate:

- Assessment of the shape of the inferolateral margin of the proximal tibial epiphysis

How to grade:

- Absent – assign value of 0
 - Assign value of 0 if the inferolateral margin of the proximal tibial epiphysis is blunted with no downward peak or projection (Figure 5A)
- Present – assign value of 1
 - Assign value of 1 if the inferolateral margin of the proximal tibial epiphysis projects downwards with or without a distinct peak (Figure 5B)

TibP – “Capping” of the medial proximal tibial epiphysis over the metaphysis

How to evaluate:

- Assessment of the shape of the inferomedial margin of the proximal tibial epiphysis

How to grade:

- Absent – assign value of 0
 - Assign value of 0 if the inferomedial margin of the proximal tibial epiphysis is blunted with no downward peak or projection (Figure 6A)
- Present – assign value of 1
 - Assign value of 1 if the inferomedial margin of the proximal tibial epiphysis projects downwards with or without a distinct peak (Figure 6B)

TibQ – Fusion of the lateral proximal tibial physis

How to evaluate:

- Assessment of fusion of the lateral proximal tibial physis, which begins to close medially and progresses laterally with age

- Note that only the lateral 1/3 of the proximal tibial physis is assessed, as the central portion of the physis is obscured by the tibial tubercle

How to grade:

- Absent – assign value of 0
 - Assign value of 0 if the lateral proximal tibial physis is completely open and has not begun to close, evidenced by a radiolucent gap between the epiphysis and metaphysis through the complete extent of the lateral 1/3 of the proximal tibia (Figure 7A)
- Incomplete/Partial – assign value of 1
 - Assign value of 1 if the lateral proximal tibial physis has begun to fuse, but fusion is not yet complete, evidenced by the disappearance of the radiolucent gap beginning to disappear medially, but still apparent laterally (Figure 7B)
- Complete – assign value of 2
 - Assign value of 2 if the lateral proximal tibial physis has completely fused, evidenced by complete disappearance of the radiolucent gap between the epiphysis and metaphysis through the complete extent of the lateral 1/3 of the proximal tibia (Figure 7C)

FibA – Ratio of proximal fibula epiphyseal width to metaphyseal width

How to evaluate:

- First, draw a line from the medial most to lateral most points of the proximal fibular metaphysis at its widest portion (Figure 8 – Line 1)
- Second, draw a line parallel to Line 1 from the medial most to lateral most points of the proximal fibular epiphysis at its widest portion (Figure 8 – Line 2)

How to grade:

- The value for FibA is calculated by dividing the epiphyseal width (value of Line 2) by the metaphyseal width (value of Line 1)
- $$FibA = \frac{\text{Proximal Fibula Epiphyseal Width}}{\text{Proximal Fibula Metaphyseal Width}}$$

Example of using parameters to predict years away from 90% of final height: 10 year old Male

Parameter	Factor	Graded Value	Product
Constant	-12.348	-	-12.348
Age	0.379	10	3.79
Sex	-0.662	1	-0.662
FemK	0.375	0	0
FemL	0.237	0	0
TibA	3.888	1.08	4.199
TibN	0.351	0	0
TibP	0.289	0	0
TibQ	0.279	0	0
FibA	2.395	0.83	1.988
SUM			-3.03

Thus, based on the model, this 10-year-old male is 3.03 years away from reaching 90% of his final height. Mean age at 90% final height is 11.40 years in females, and 13.20 years in males. Thus, the estimated skeletal age in this case is 13.20 years – 3.03 years = 10.17 years.

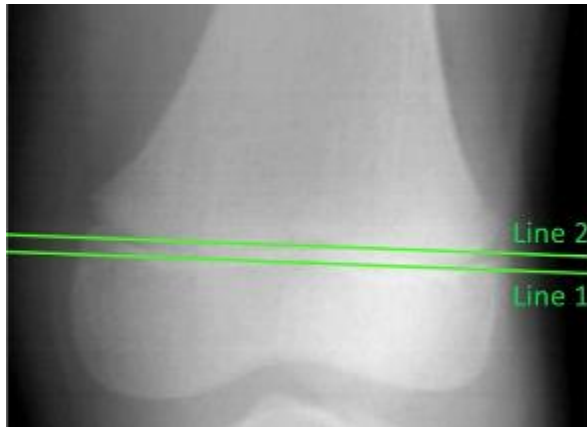


Figure 1. FemK – Lines drawn to assess capping of the lateral distal femur

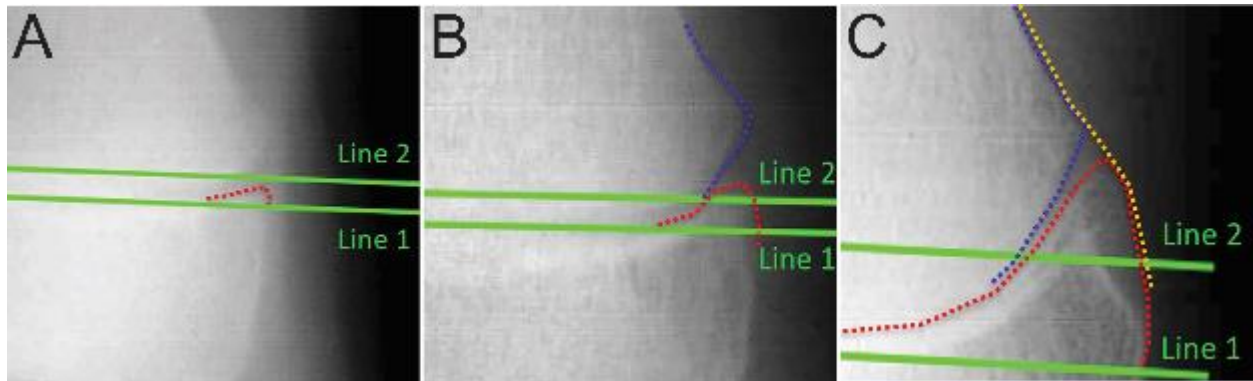


Figure 2. FemK **A)** Absent (0) **B)** Incomplete (1) **C)** Complete (2). Red line – superolateral margin of distal femoral epiphysis. Blue line – beveled edge of lateral margin of distal femoral metaphysis. Orange line – highlighting the congruency between distal femoral epiphysis and metaphysis.

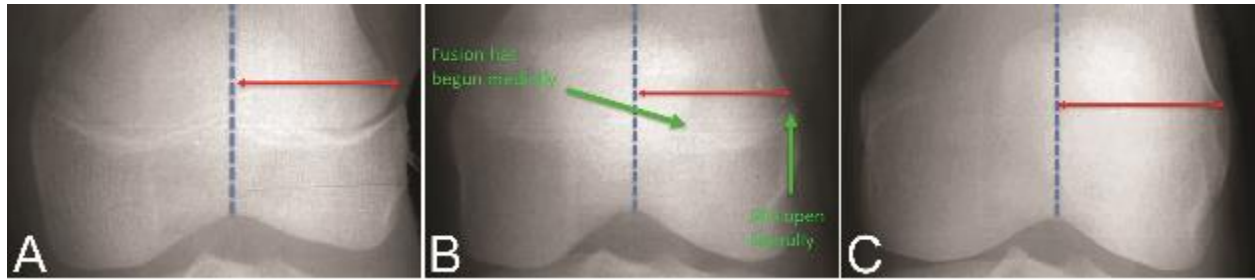


Figure 3. Fem L **A)** Absent (0) – fusion has not yet begun **B)** Incomplete/Partial (1) – fusion has begun medially, but not yet complete laterally **C)** Complete – fusion complete throughout the lateral distal femoral physis. Blue line – midpoint between medial/lateral aspects of distal femur. Red line – lateral distal femur.

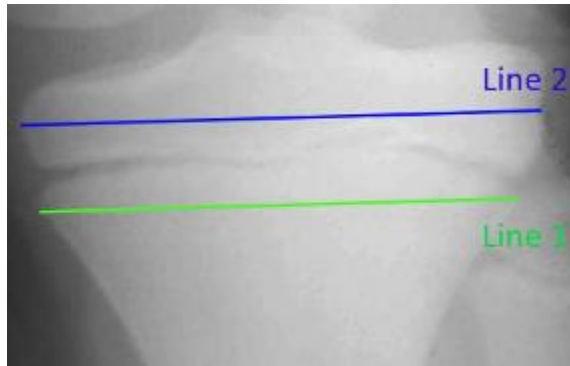


Figure 4. TibA – Ratio of proximal tibial epiphyseal width (Line 2) to metaphyseal width (Line 1).

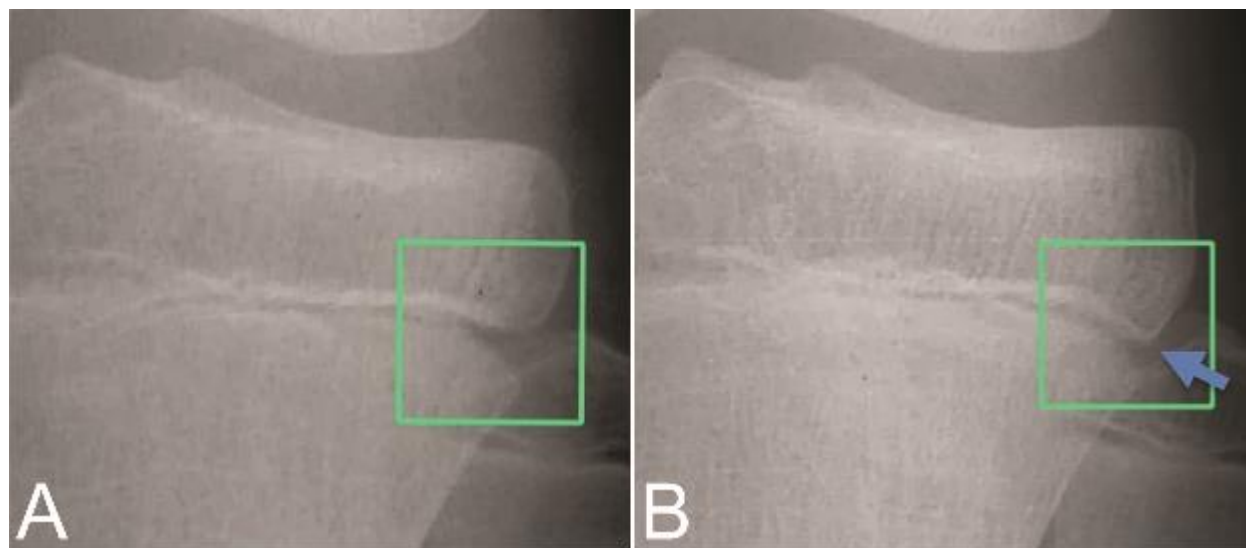


Figure 5. TibN **A)** Absent (0) – blunted inferolateral margin of proximal tibial epiphysis **B)** Present (1) – downward projection/peak at inferolateral margin of proximal tibial epiphysis (arrow).

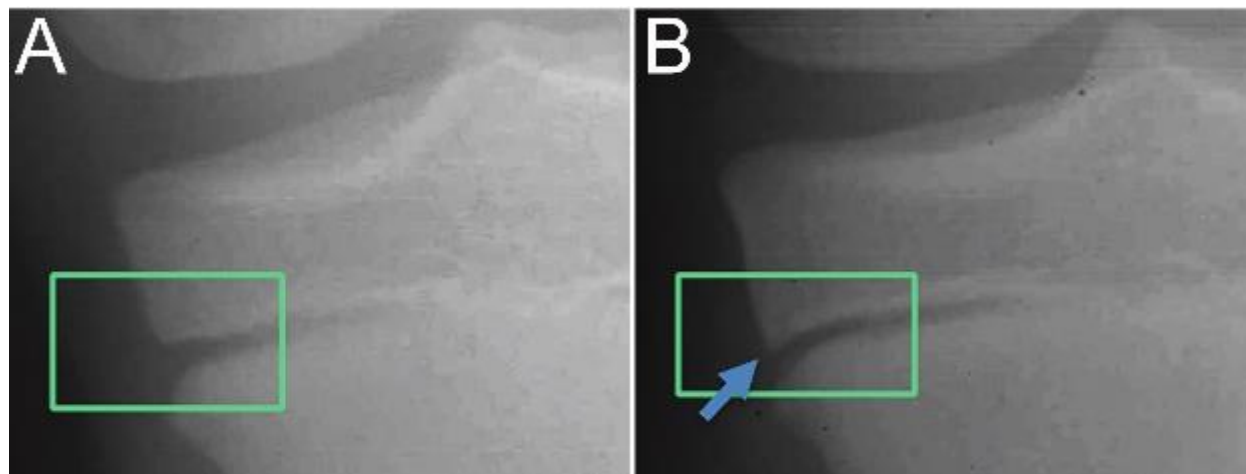


Figure 6. TibP **A)** Absent (0) – blunted inferomedial margin of proximal tibial epiphysis **B)** Present (1) – downward projection/peak at inferomedial margin of proximal tibial epiphysis (arrow).

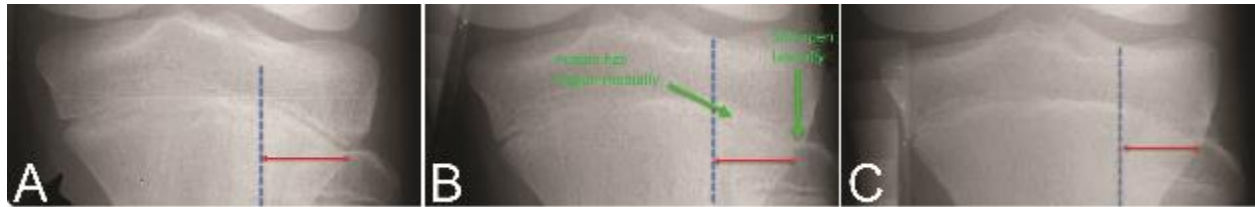


Figure 7. TibQ A) Absent (0) – fusion has not yet begun **B)** Incomplete/Partial (1) – fusion has begun medially, but not yet complete laterally **C)** Complete (2) – fusion complete throughout the lateral proximal tibial physis. Blue line – delineating the lateral 1/3 of lateral proximal tibia. Red line – lateral 1/3 of proximal tibia.

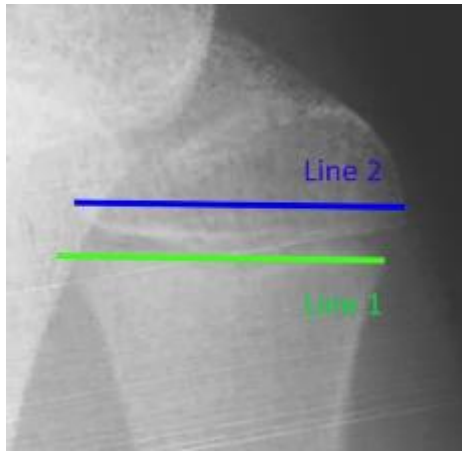


Figure 8. FibA – Ratio of proximal fibular epiphyseal width (Line 2) to metaphyseal width (Line 1).