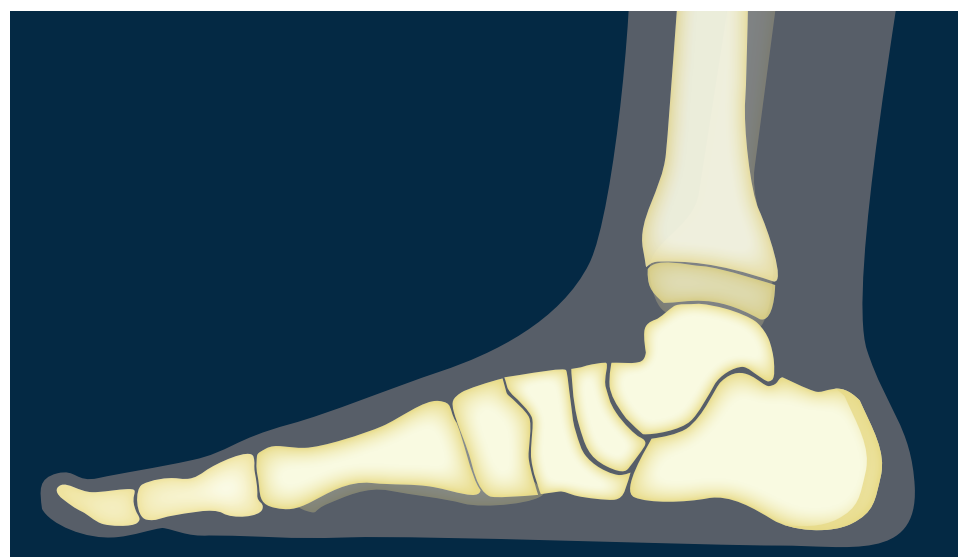
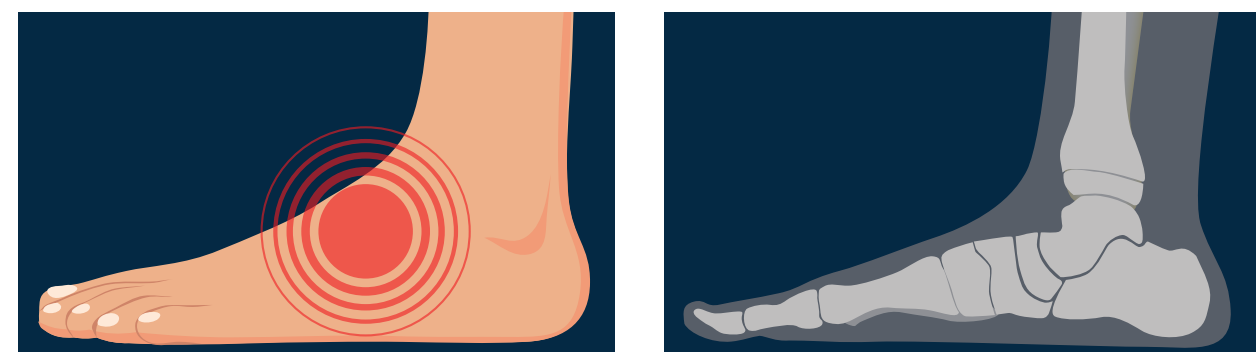


# Link Between Subjective Symptoms and Radiographic Severity in Children with Pes Planovalgus

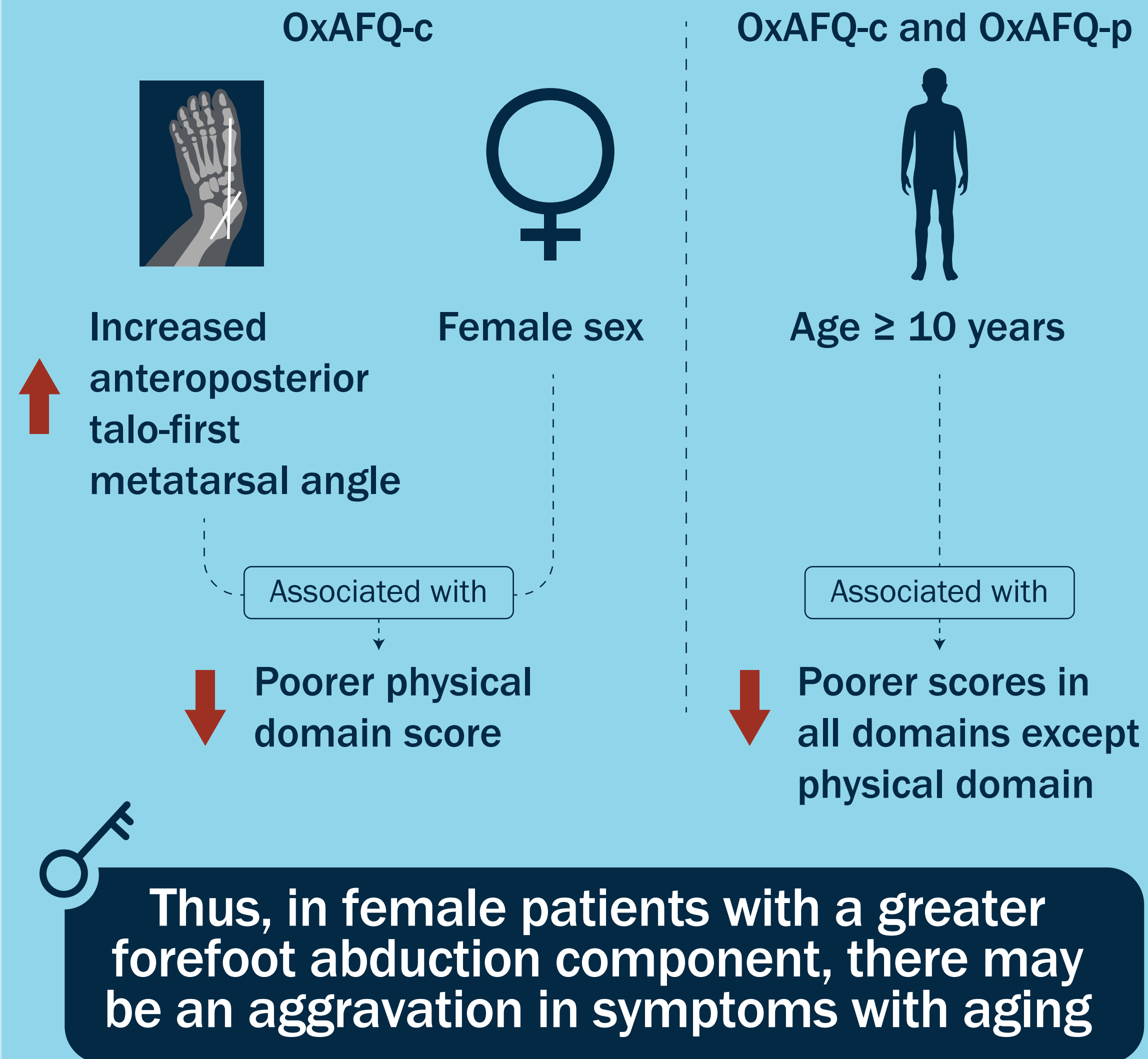
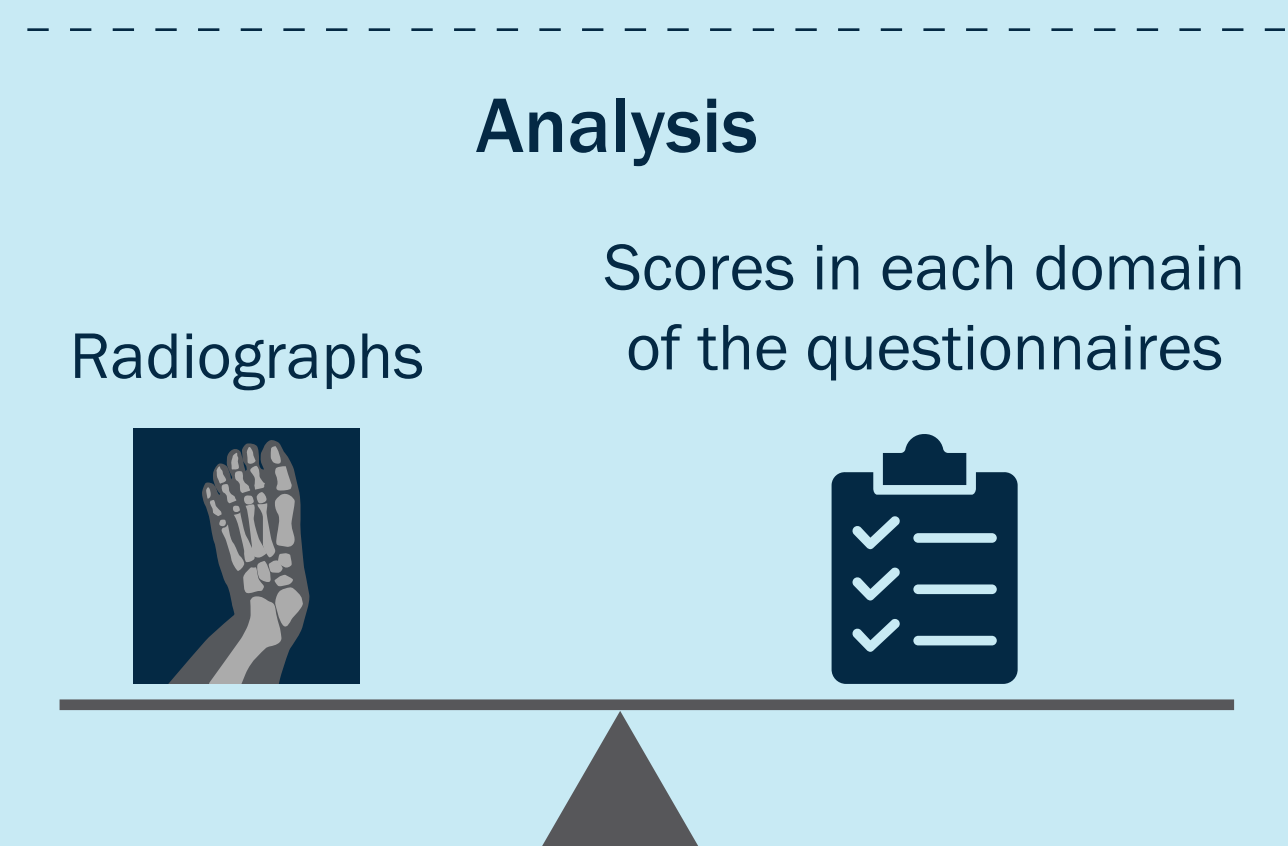
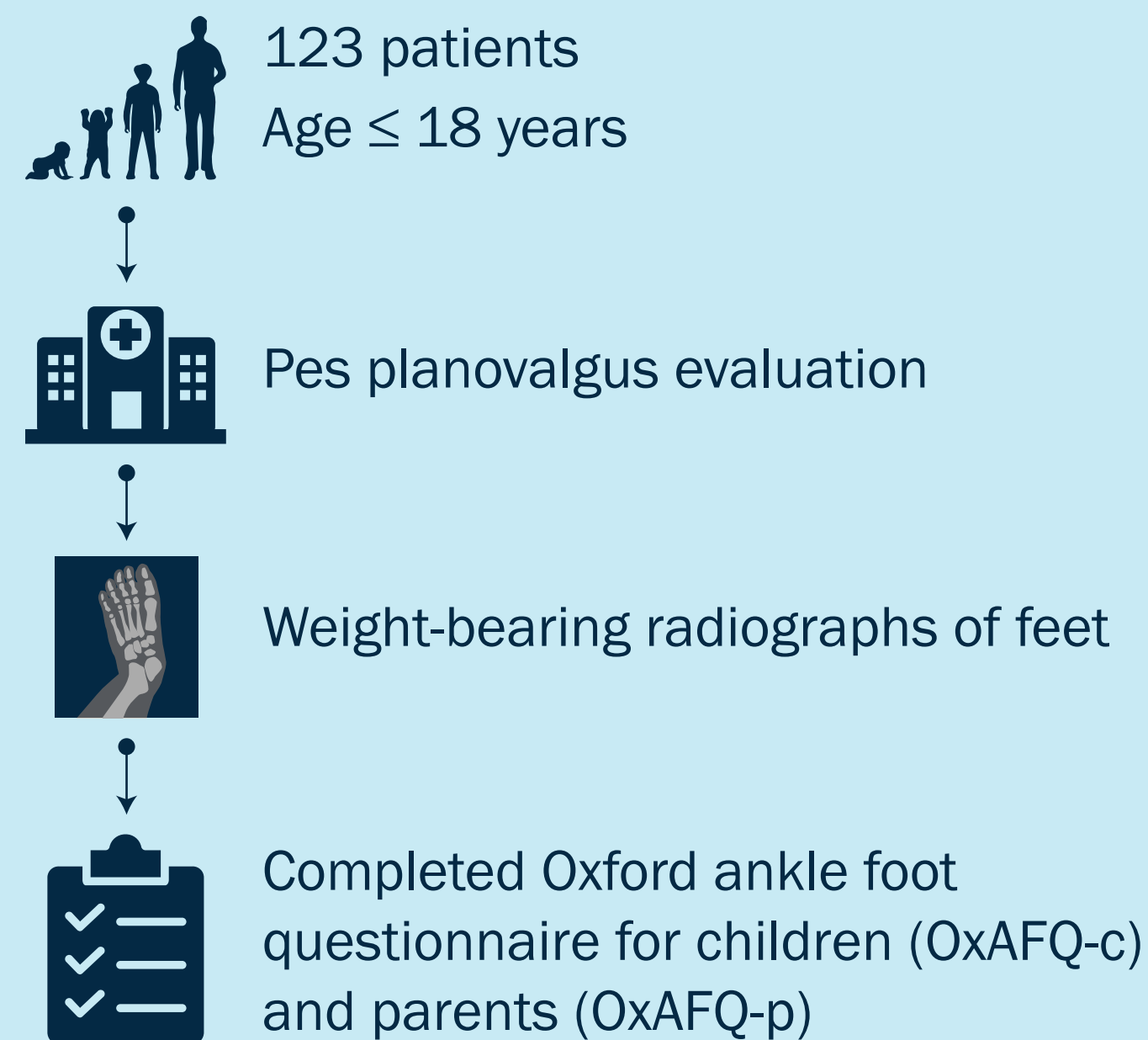
Idiopathic pes planovalgus, or flat feet, is a common type of deformity in children and adolescents



Discrepancies have been noted between subjective symptoms and radiographic severity



However, the association between the two remains insufficiently explored



**Factors Affecting Subjective Symptoms in Children with Pes Planovalgus Deformity: A Study Using the Oxford Ankle Foot Questionnaire**  
Min et al. (2020) | DOI: 10.2106/JBJS.19.01504

[www.jbjs.org](http://www.jbjs.org)

[f theJBJS](#)

[@JBJS](#)

