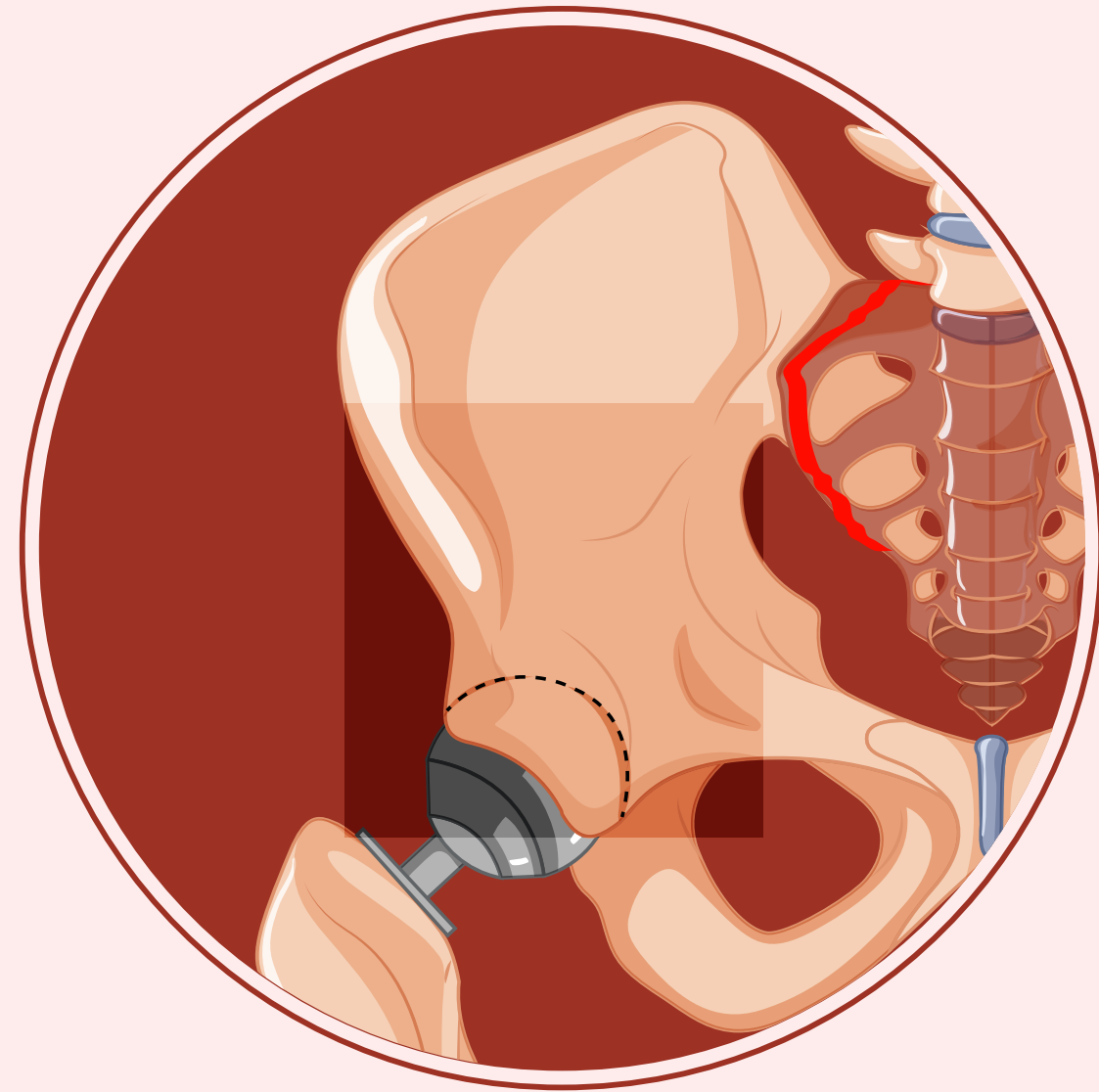


Can Sacral Insufficiency Fractures Develop After Total Hip Arthroplasty?

Sacral insufficiency fractures (SIF) occur in elderly patients and are related to osteoporosis



Total hip arthroplasty (THA) is a procedure frequently performed in elderly patients

Is THA a risk factor for SIF?

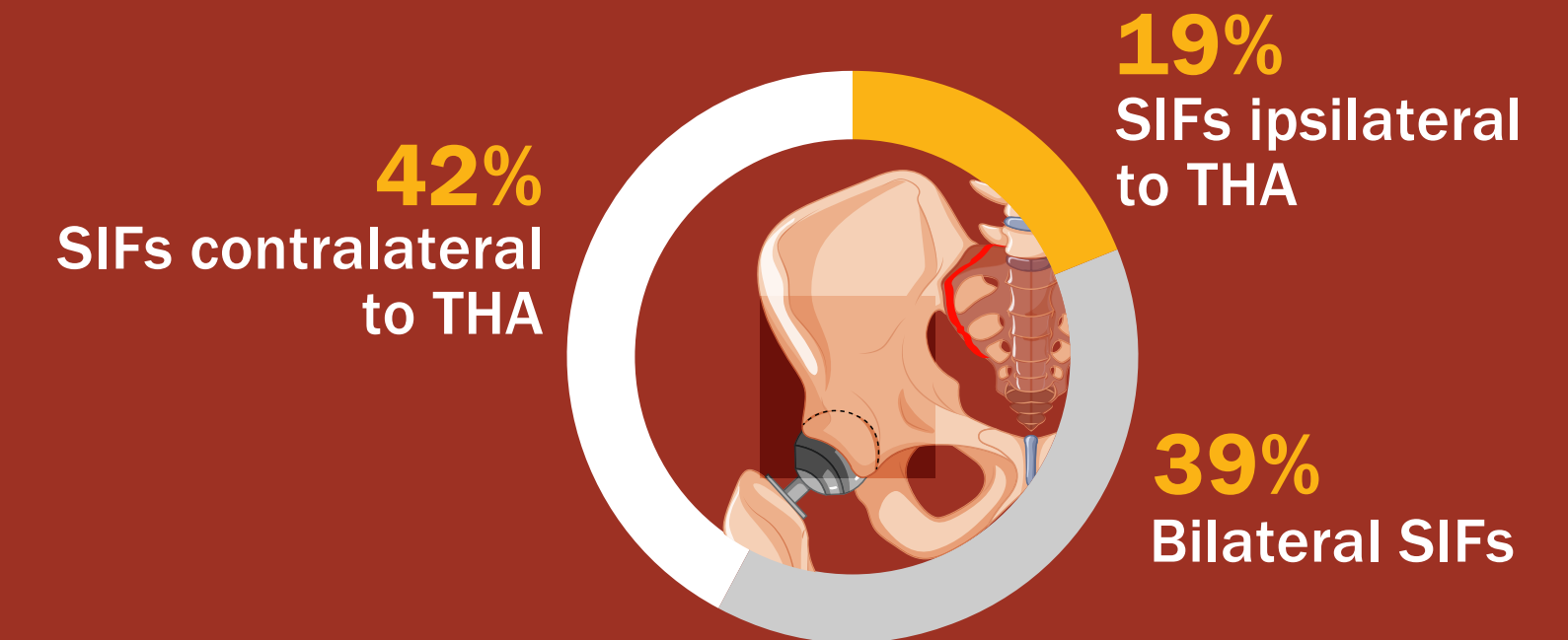
Retrospective study of 171 patients with SIF

50 patients with THA

31 patients with unilateral THA

Localization of SIF in relation to THA

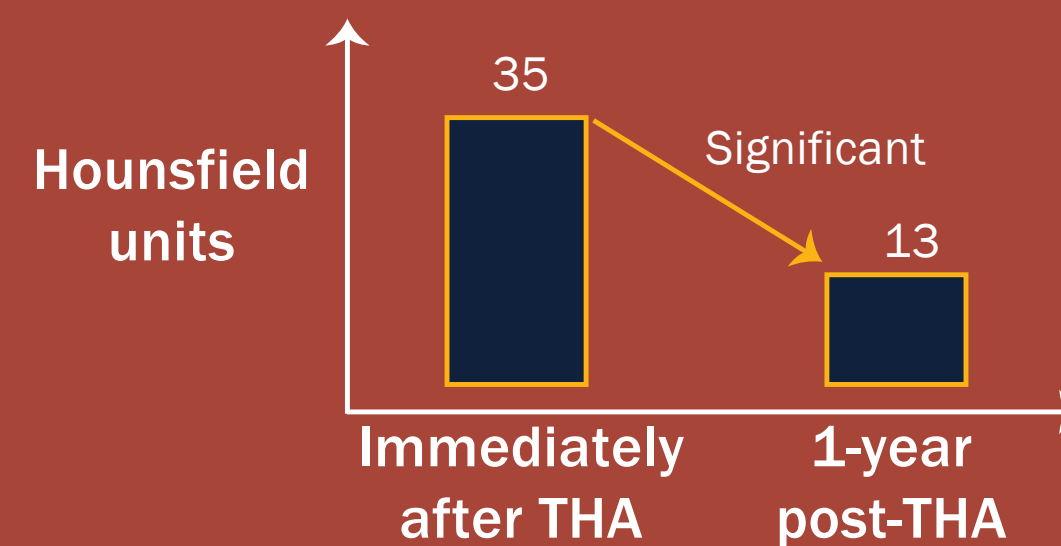
Rate of SIFs in patients with a unilateral THA



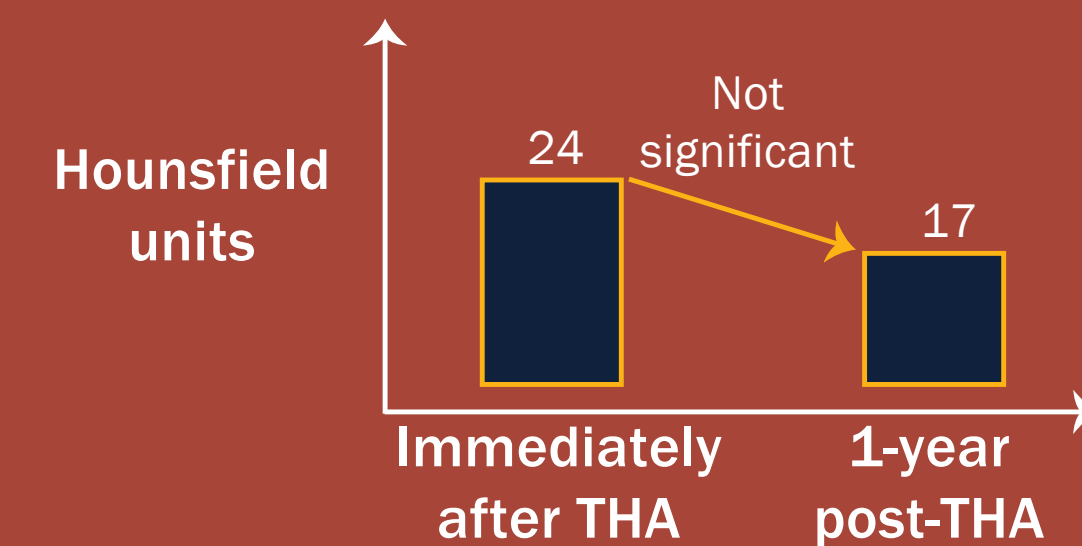
Retrospective study of 39 bone healthy patients with unilateral THA

Changes of bone mineral density at the sacral alae analyzed immediately after THA and at 1 year follow-up using CT

In sacral ala contralateral to THA



In sacral ala ipsilateral to THA



Total hip arthroplasty may negatively affect the contralateral side of the sacrum resulting in sacral insufficiency fractures

Does Total Hip Arthroplasty Influence the Development and Localization of Sacral Insufficiency Fractures?

Graul et al. (2022) | DOI: 10.2106/JBJS.21.00218

www.jbjs.org | theJBJS | @JBJS

