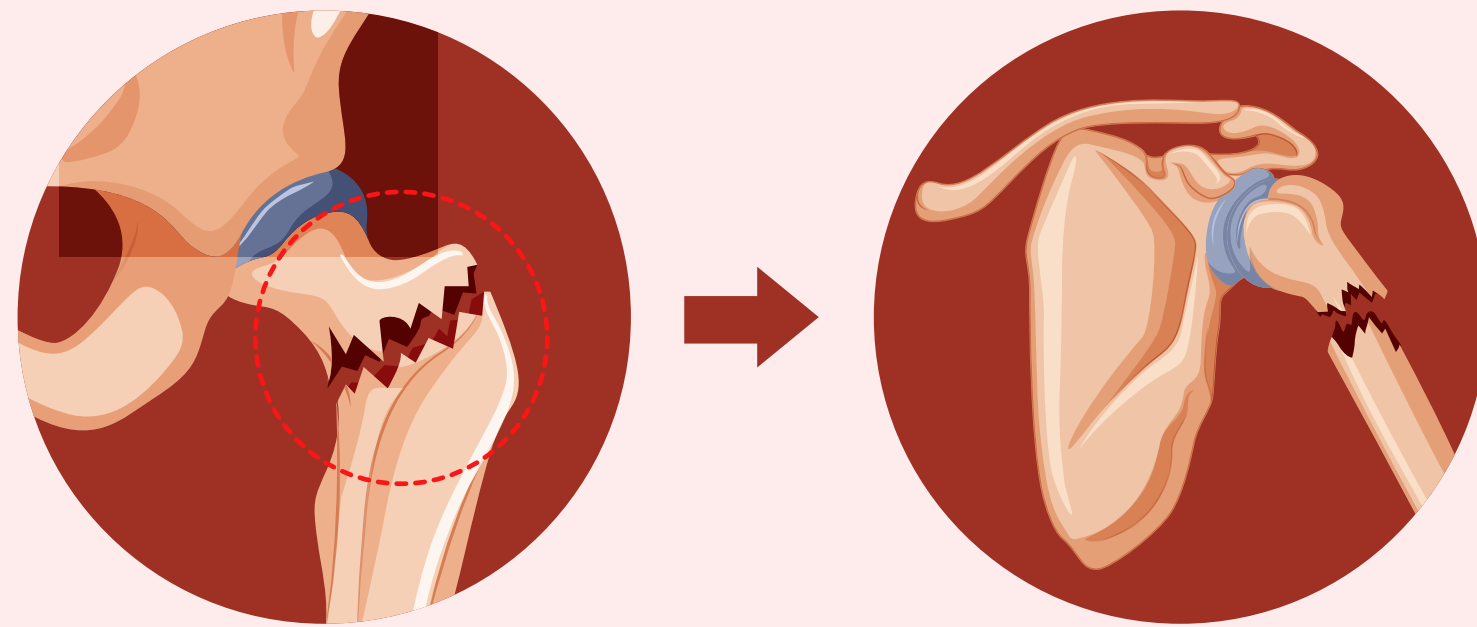


Incidence of Subsequent Fractures After an Index Femoral Neck Fracture

Fragility fractures of the femoral neck in the elderly can be followed by subsequent fractures, putting patients at risk



However, only a few of these patients undergo interventions to prevent subsequent fractures, and data on the subject is scarce

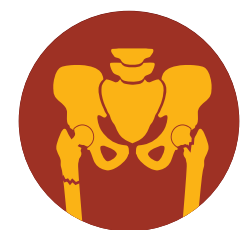

2 global cohorts of 2,520 elderly patients with femoral neck fractures

Data collection

Subsequent fracture

Use of bone protective medication

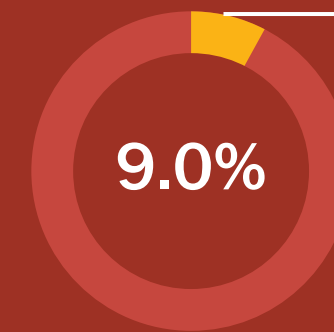


Incidence

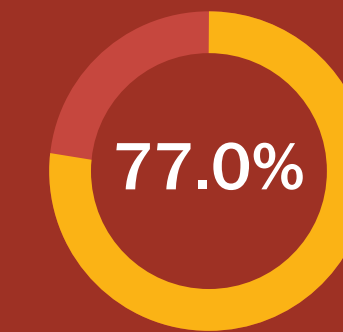
Time of occurrence



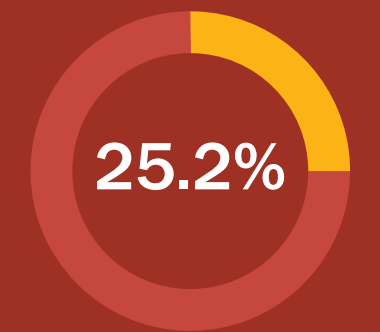
By 24 months after the initial femoral neck fracture:



Patients experienced a subsequent fracture

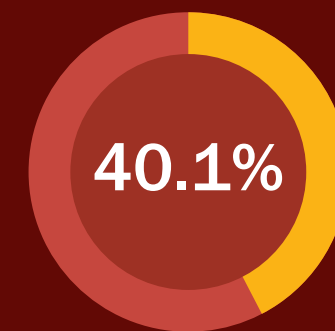


Patients who experienced a subsequent fracture were female

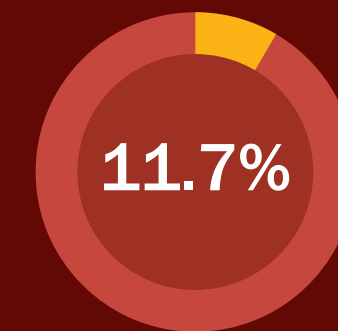


Patients reported use of bone-protective medication

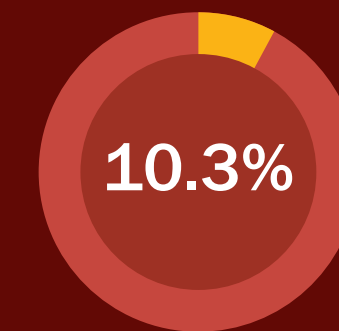
Common locations for subsequent fractures



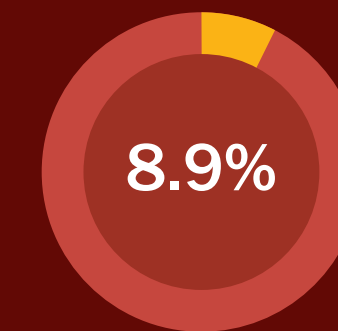
Contralateral hip



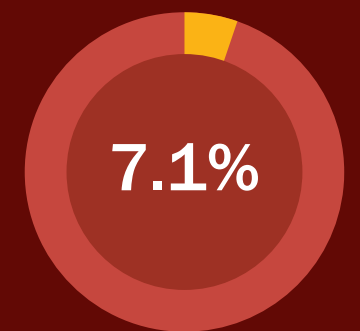
Proximal humerus



Vertebra



Pelvis




Rib

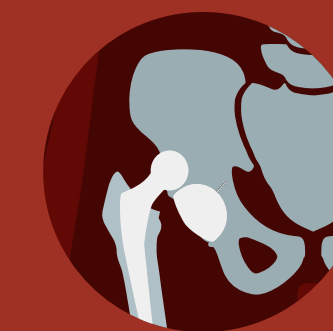Increased likelihood of receiving bone-protective medication for:



Female patients



Patients with nondisplaced fractures



Patients who have undergone arthroplasty

Elderly patients with an index femoral neck fracture commonly suffer from subsequent fragility fractures; administering bone protective medication could help prevent this occurrence

High Rates of Imminent Subsequent Fracture After Femoral Neck Fracture in the Elderly

Bogoch et al. (2022) | DOI: 10.2106/JBJS.22.00088

www.jbjs.org

theJBJS

@JBJS

