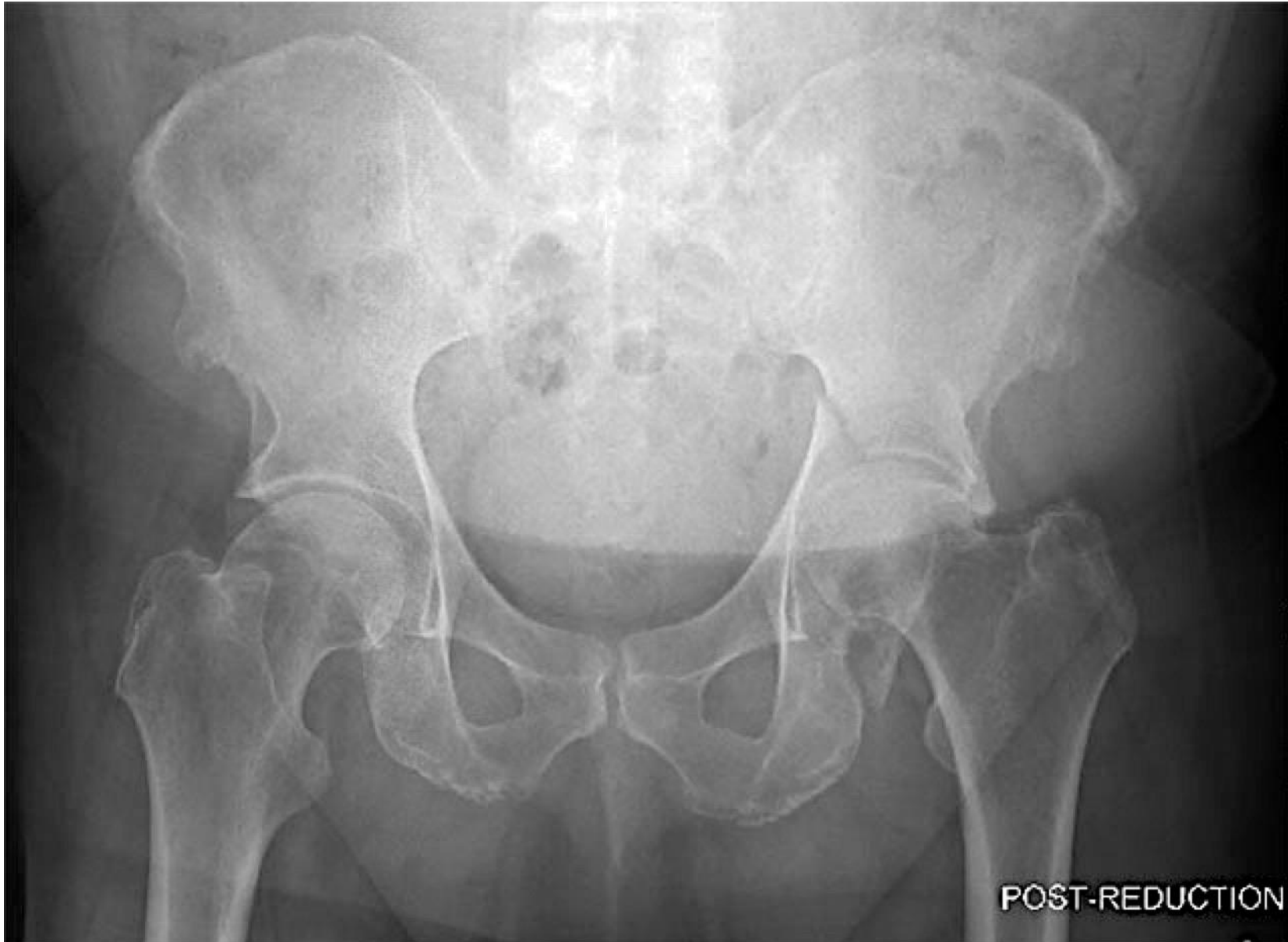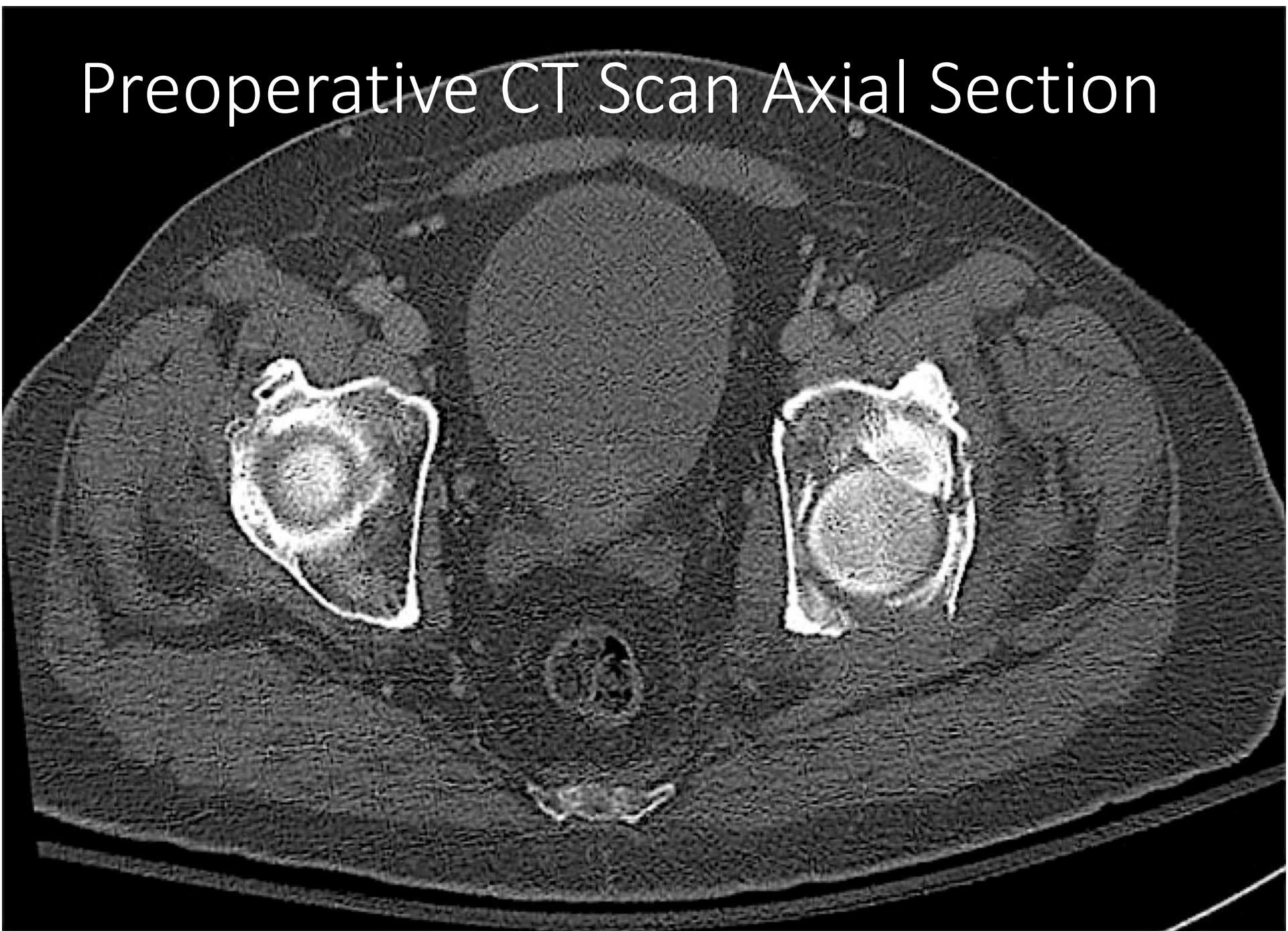


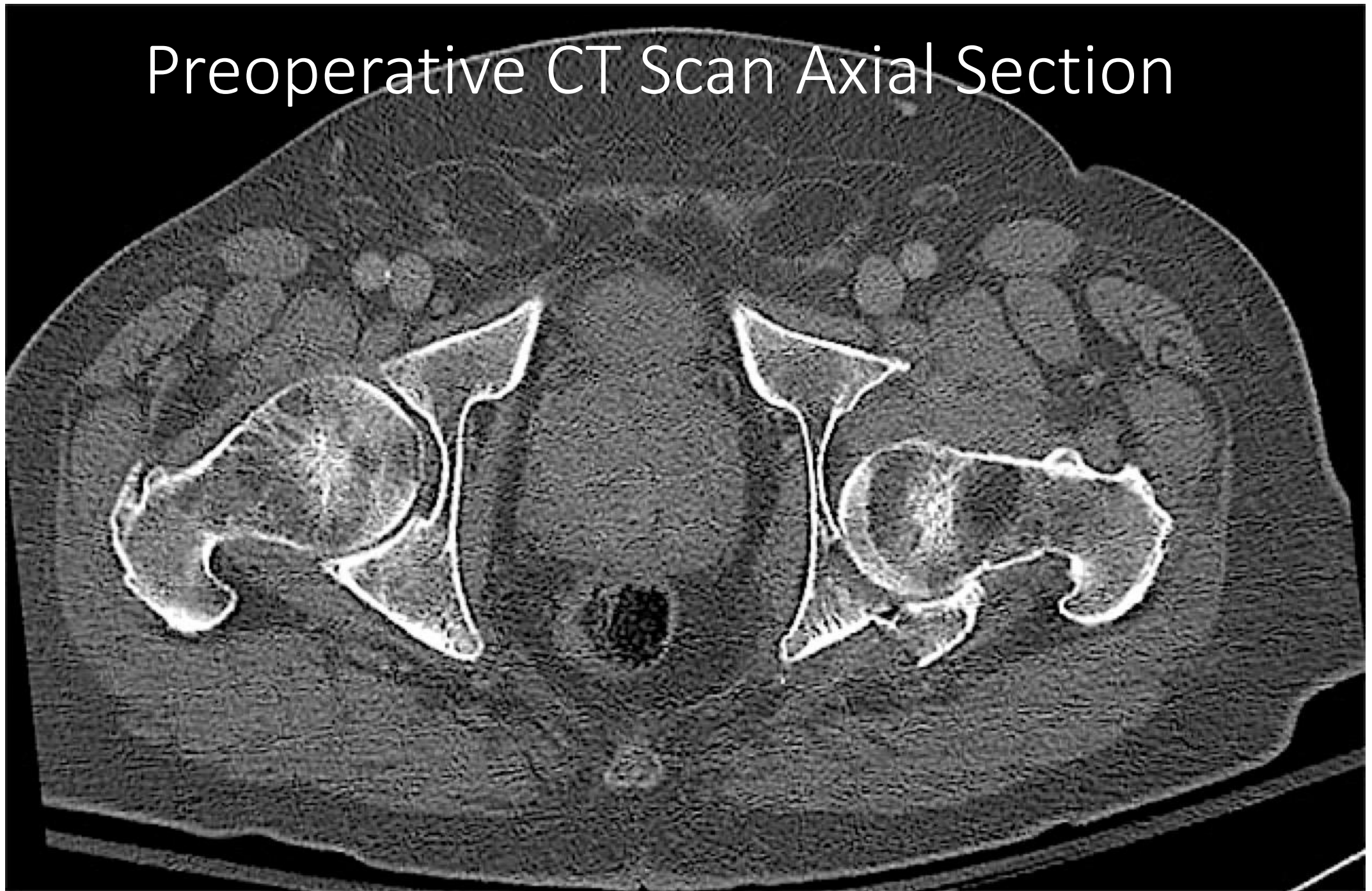
A patient sustained a comminuted transverse plus posterior wall fracture as shown on the preoperative post-reduction AP radiograph



# Preoperative CT Scan Axial Section

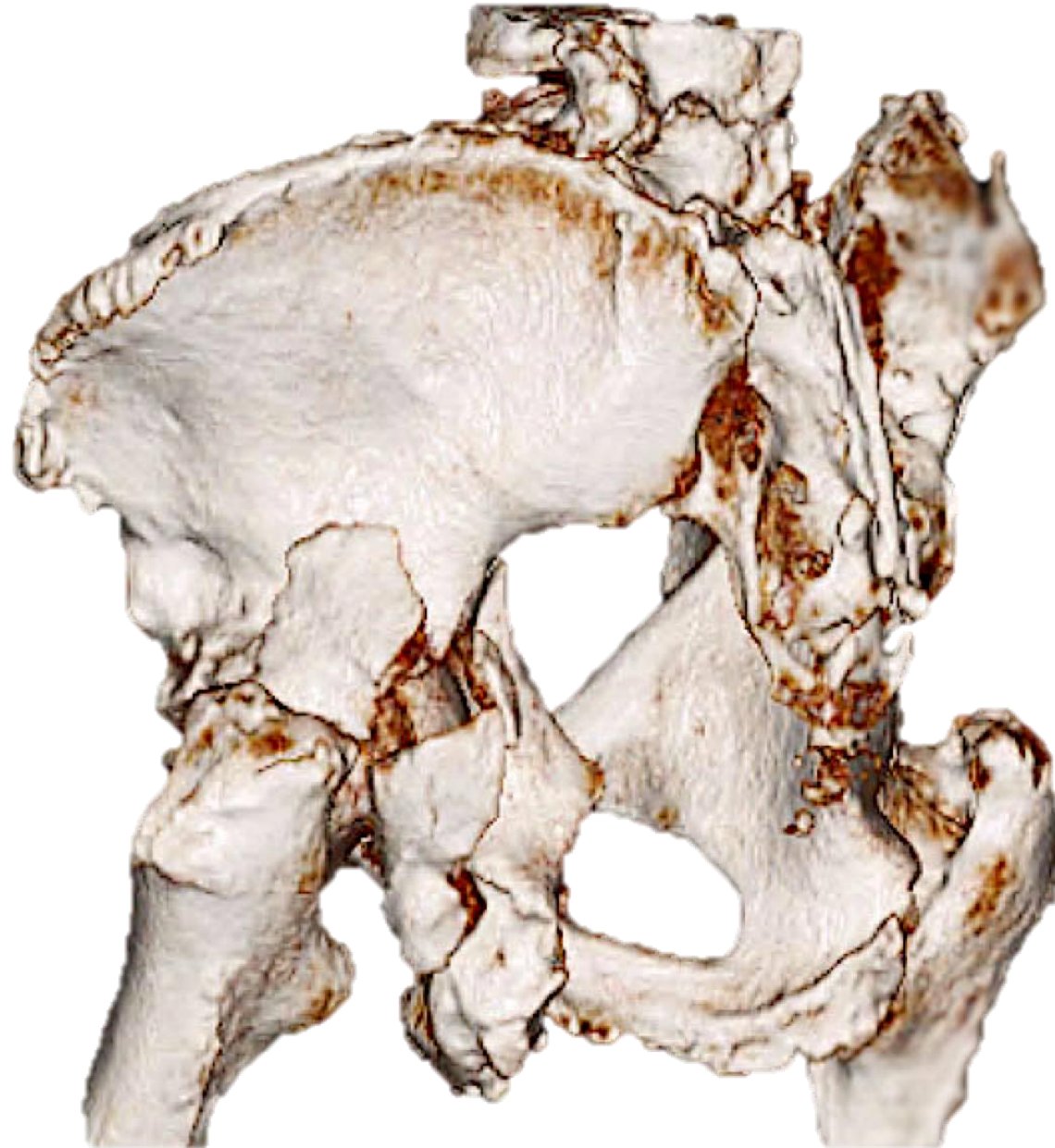

# Preoperative CT Scan Axial Section

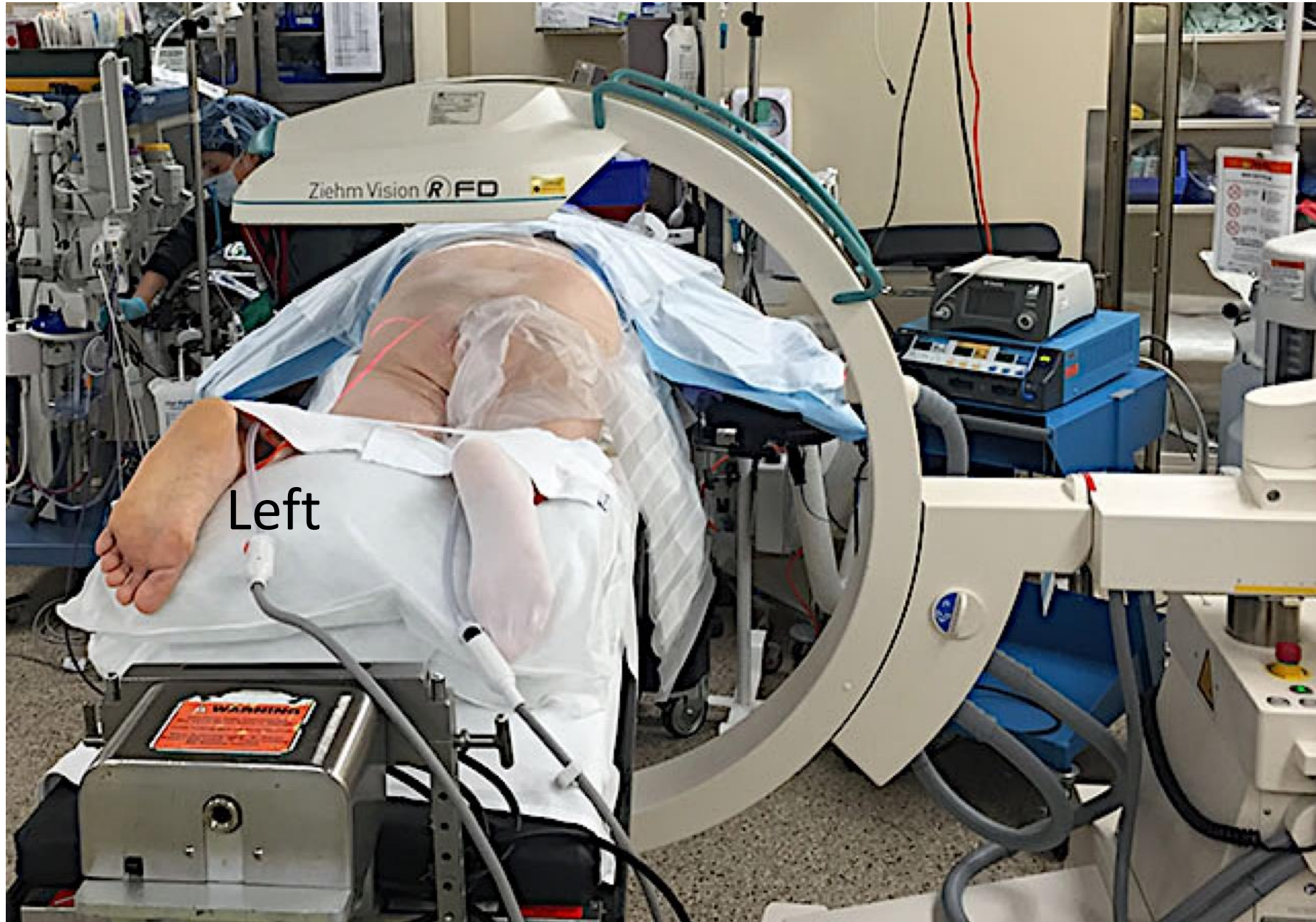



# Preoperative 3D CT Reconstruction



In the operating room, the patient was placed prone and the Ziehm RFD 3D C-arm unit was appropriately positioned





Standard fluoroscopic imaging was performed, including the AP (A) and obturator oblique (B) views, showing reduction

