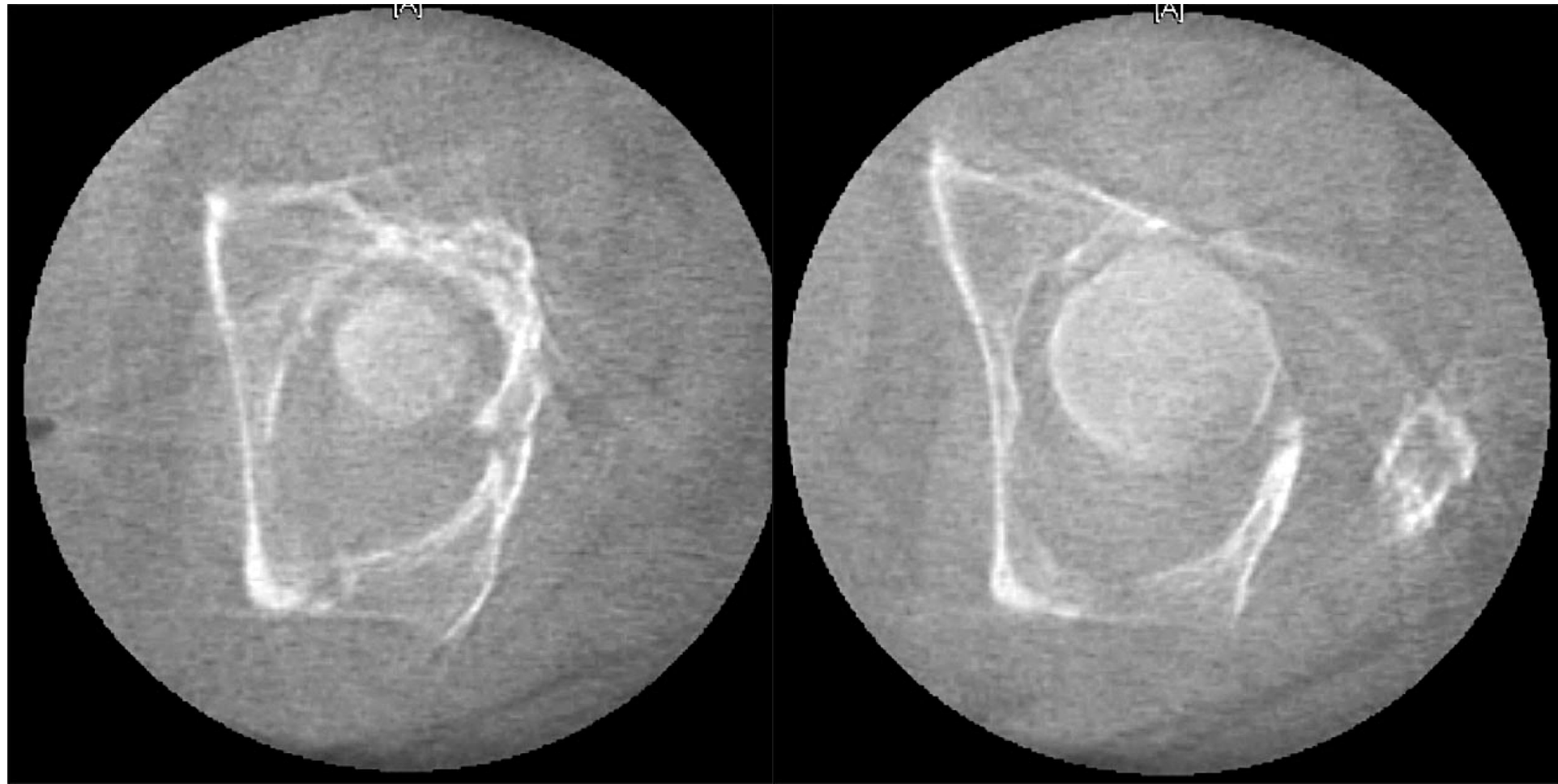
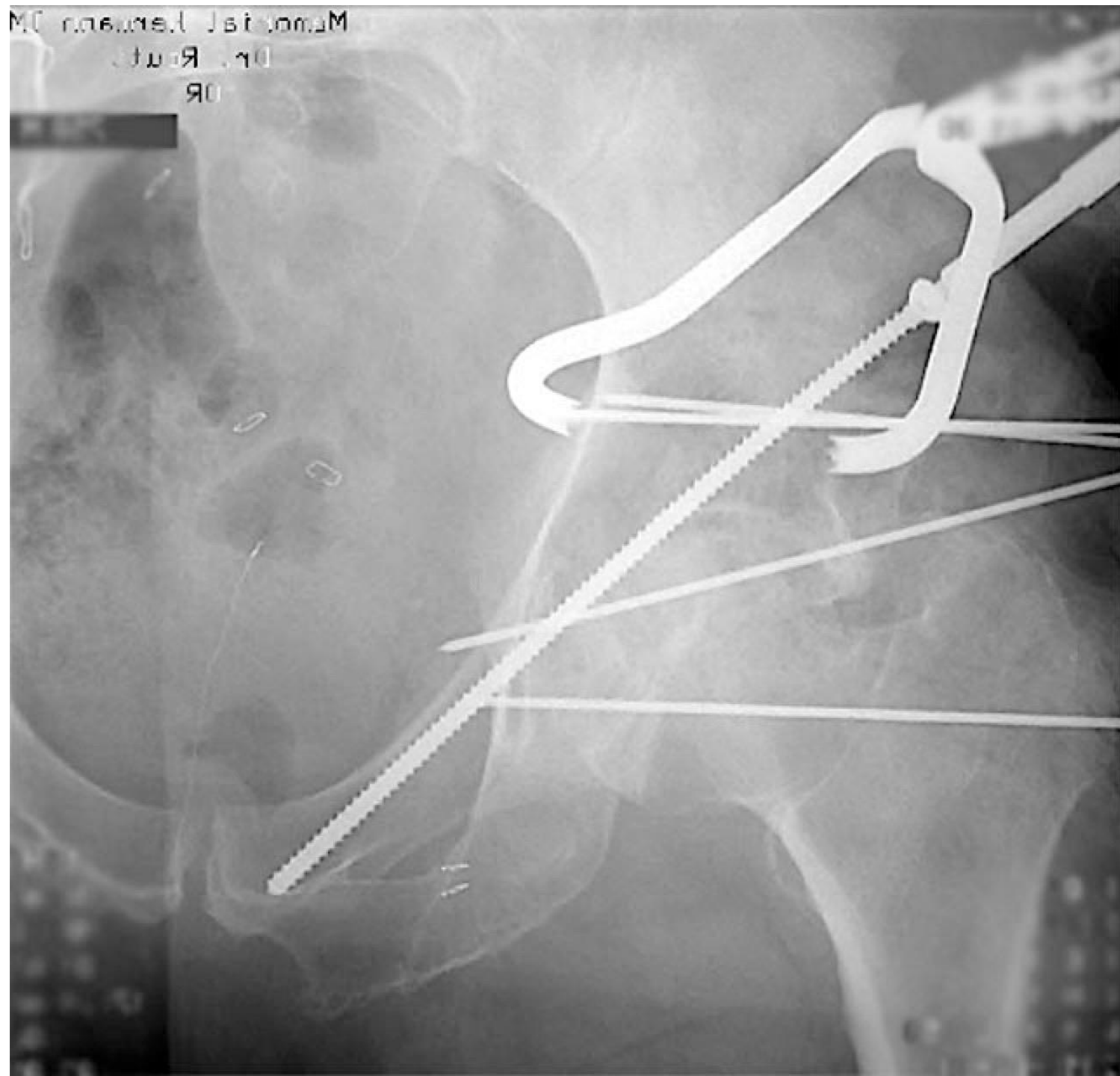


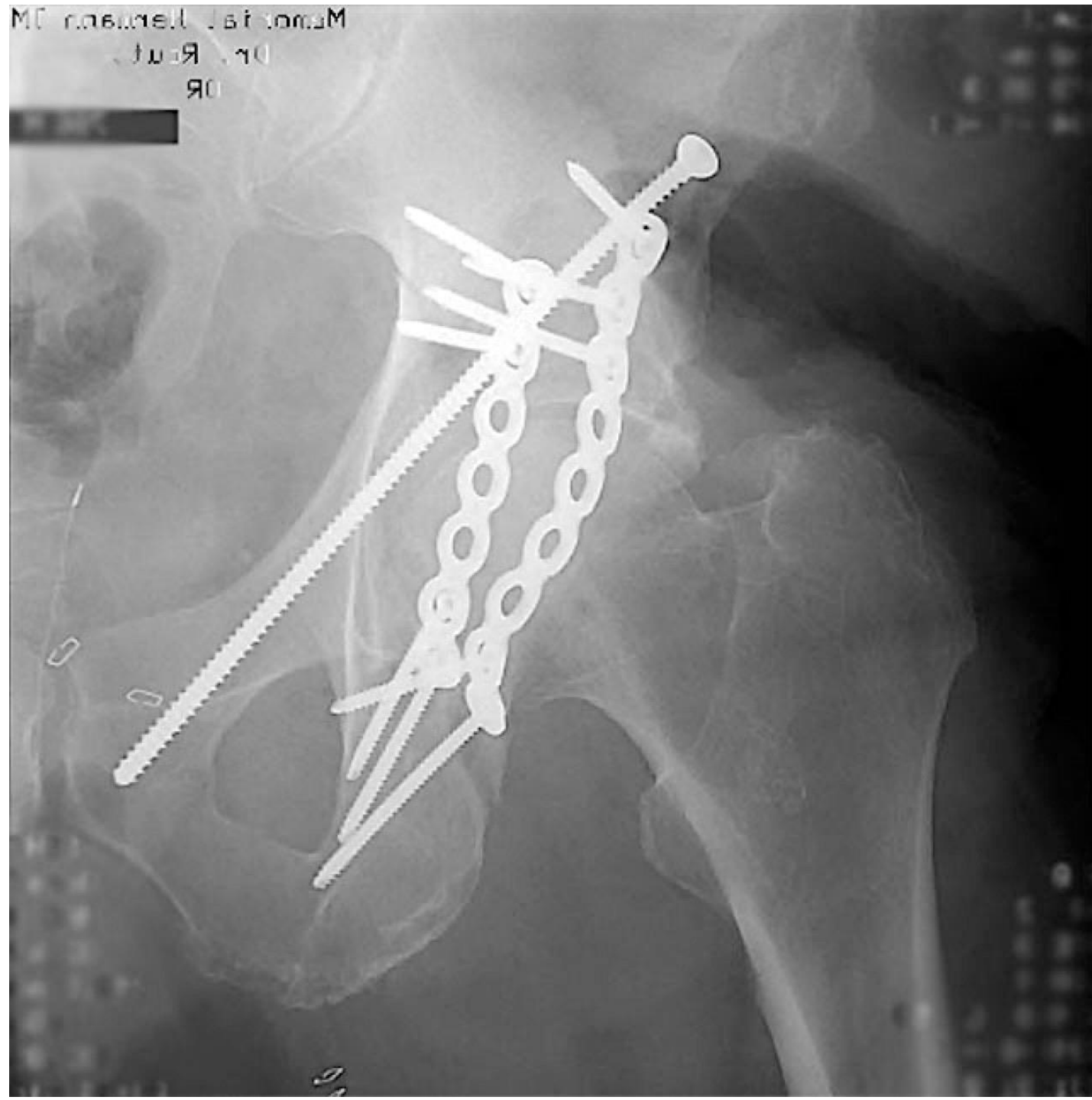
Examples of the Real Time CT Quality Intraoperative Pre-Surgery Images provided by the Ziehm C-arm spin



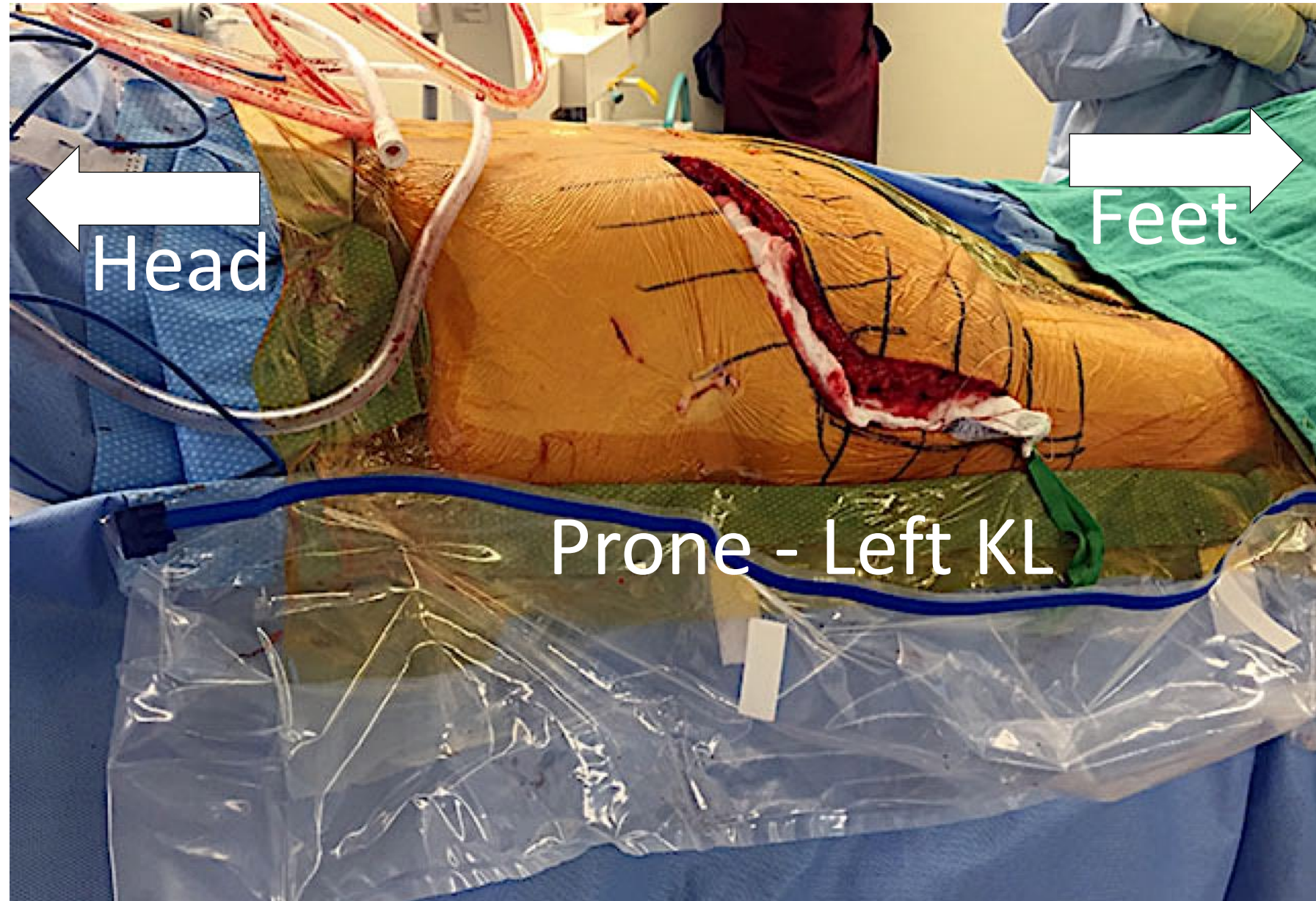
Standard fluoroscopic intraoperative image of the reduction and fixation maneuvers with the patient prone using the Kocher-Langenbeck approach



Intraoperative AP
fluoroscopic view of the final
fixation



In preparation for the post-fixation C-arm spin, the wound is packed



And the patient
is draped



