

FIG 1

Original AP Pelvis x-ray
in ER 35 yo female with
an 61C31.b injury

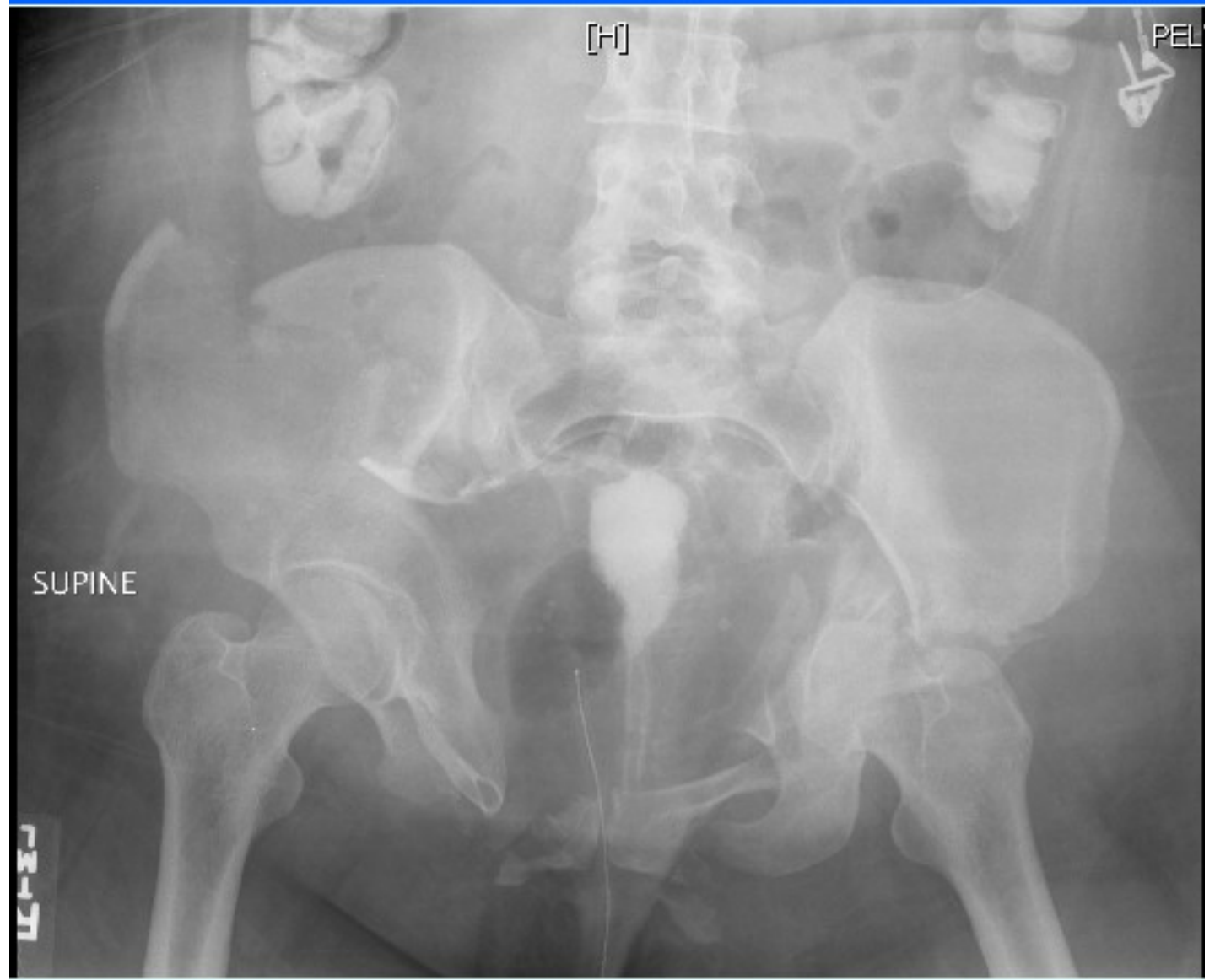


FIG 2 CT Scan

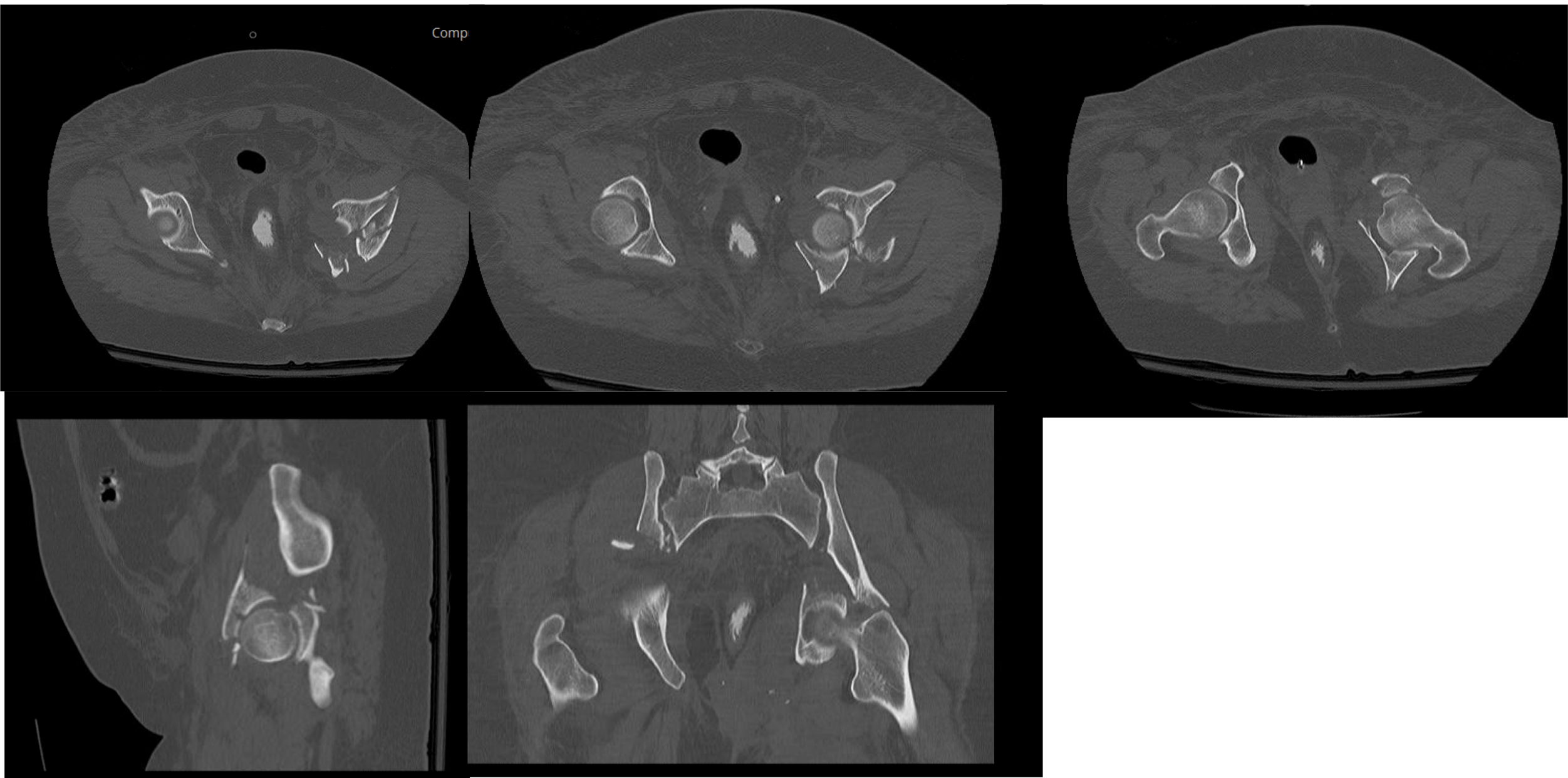


FIG 3 3D Reconstruction

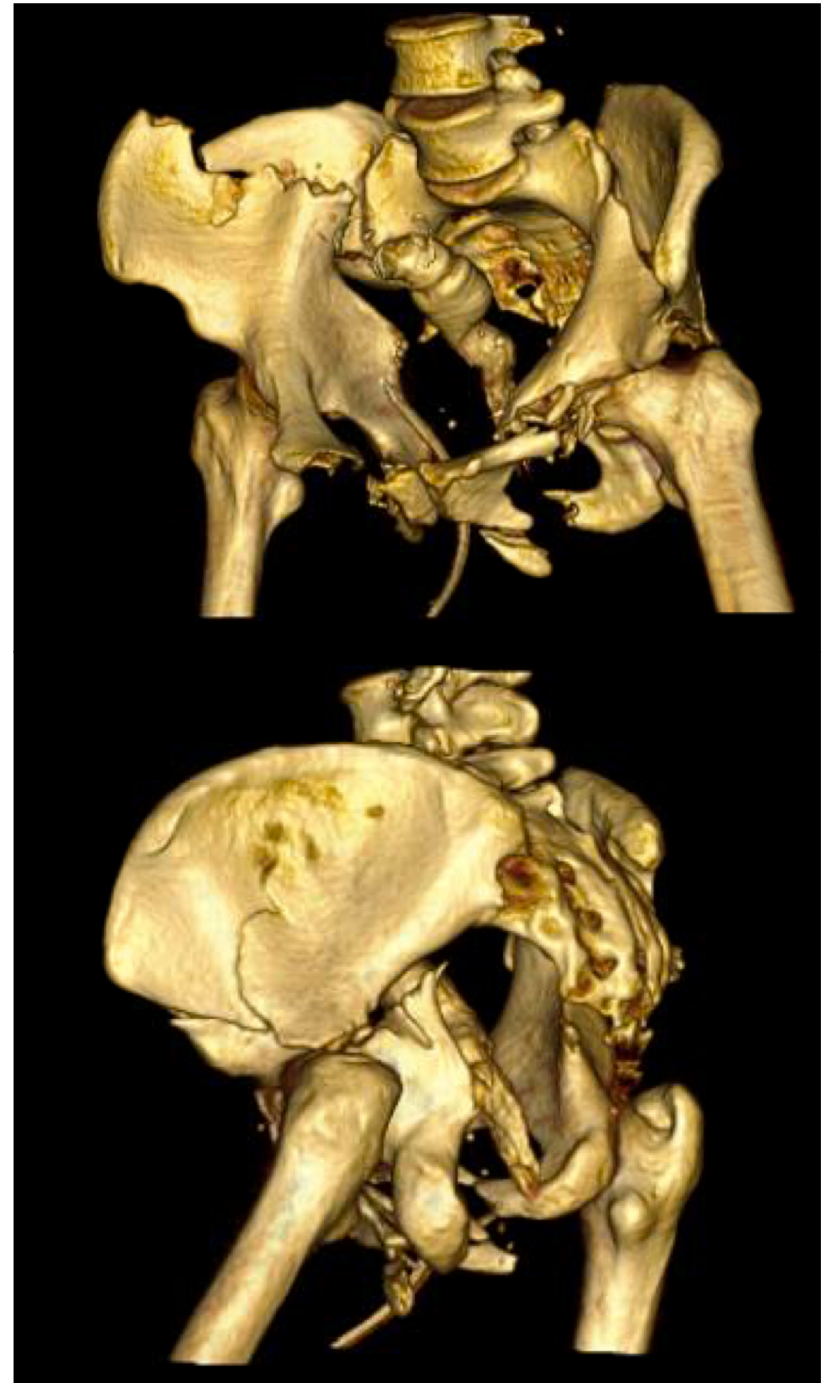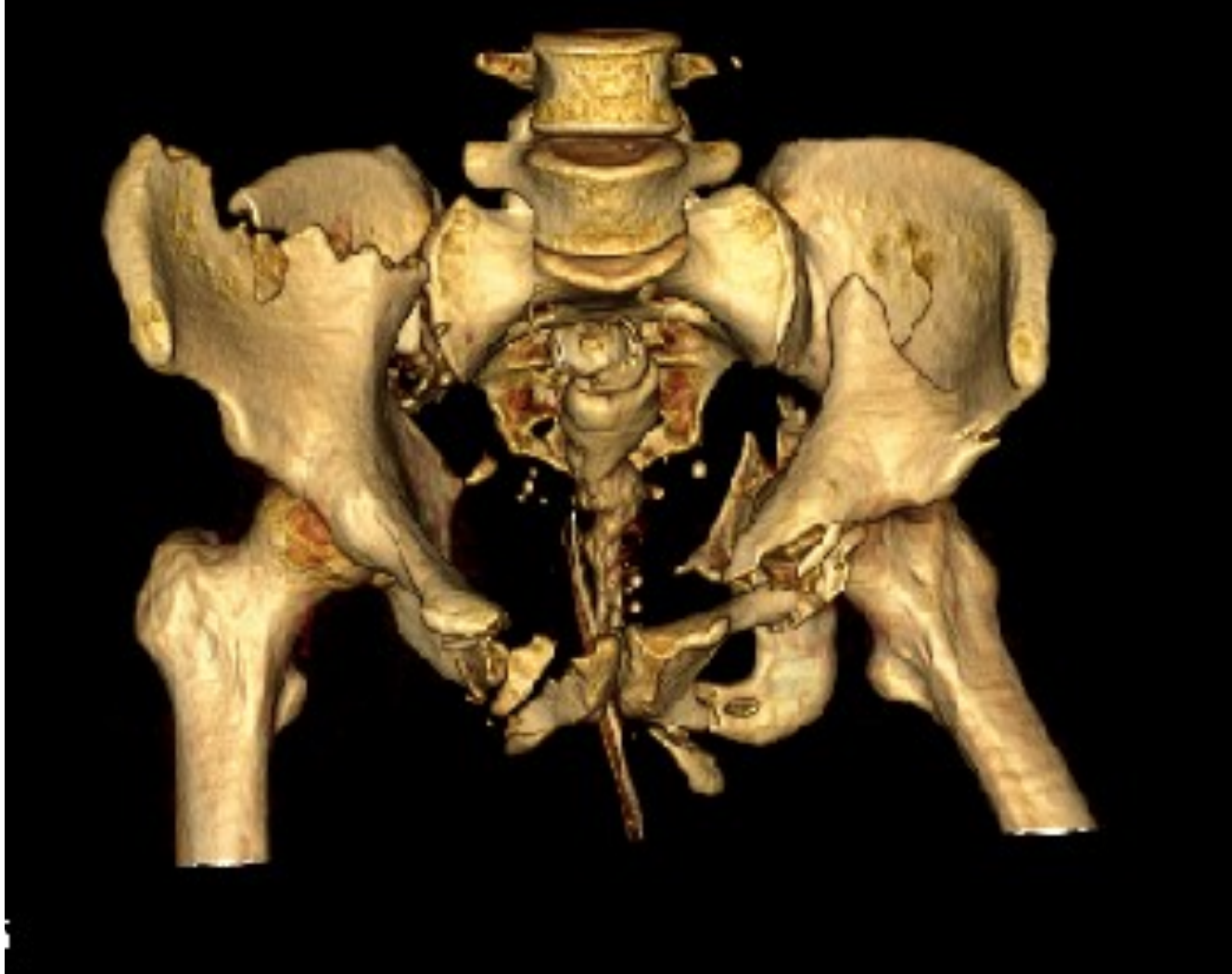


FIG 4 CT pelvis in a Binder

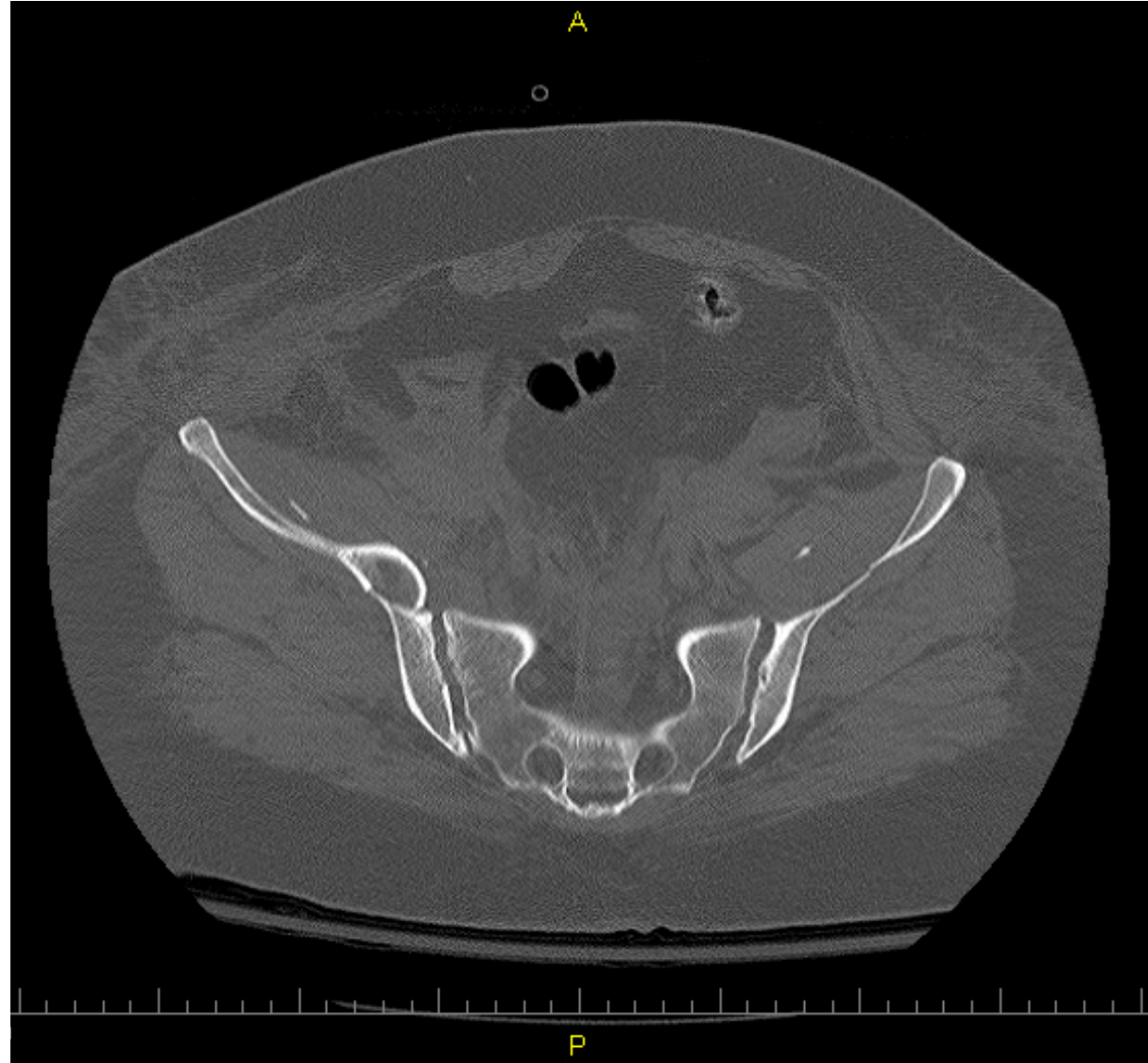


FIG 5

We started by
reducing the
posterior right
iliac fracture and
SI injury fixed
with an SI screw

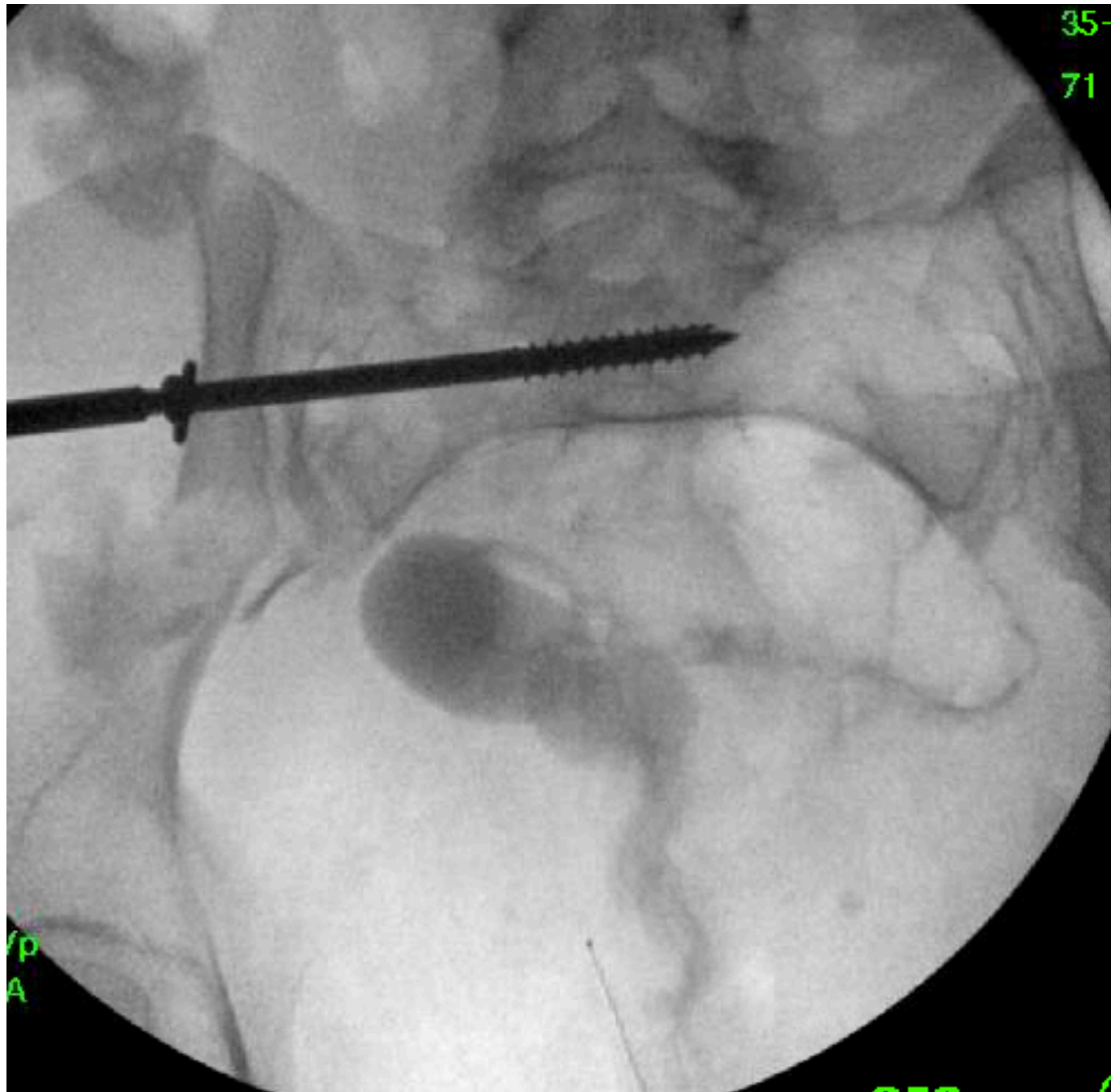


FIG 6 Iliac wing reduced and fixed at the brim and followed by an LC2 screw

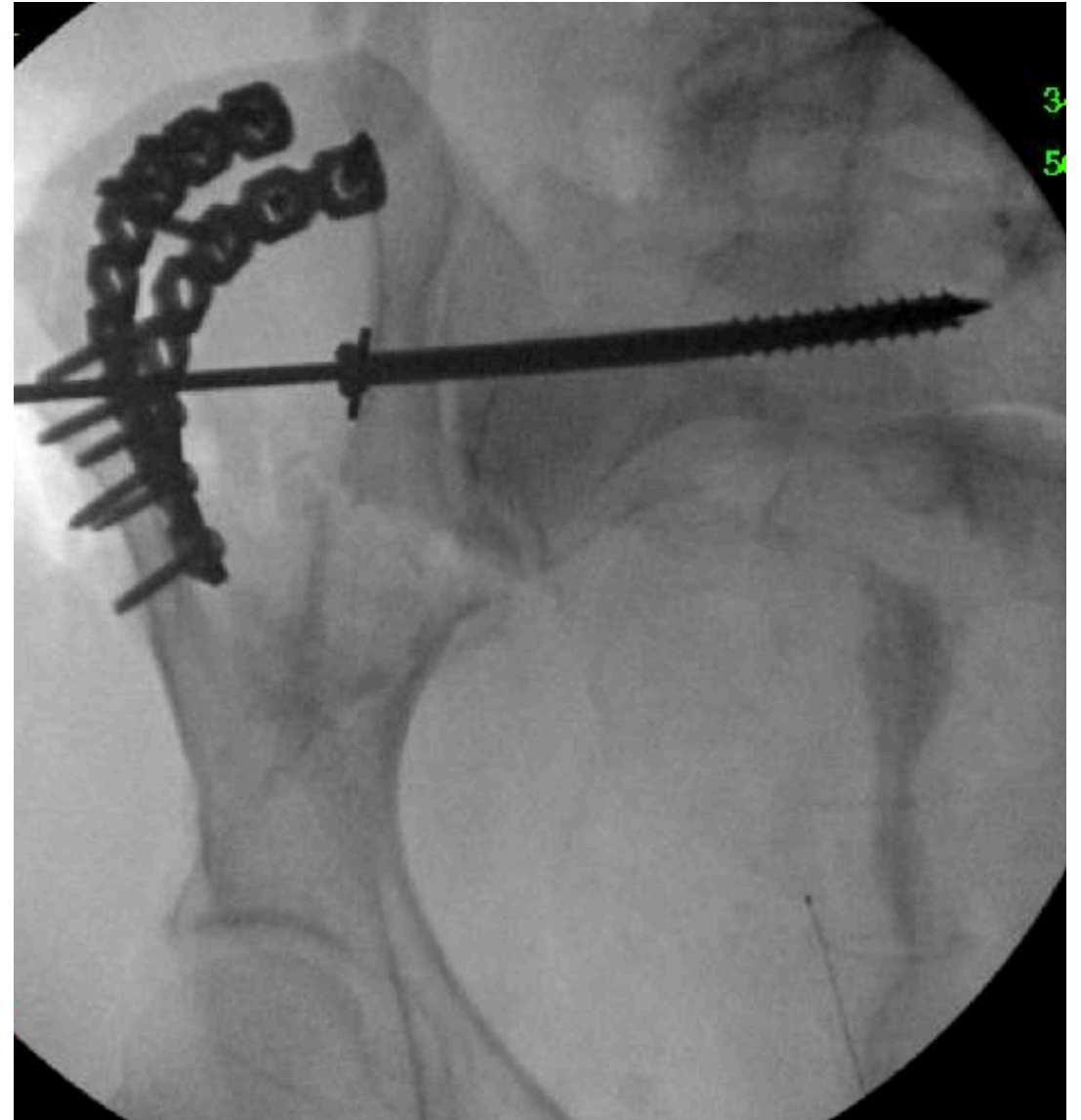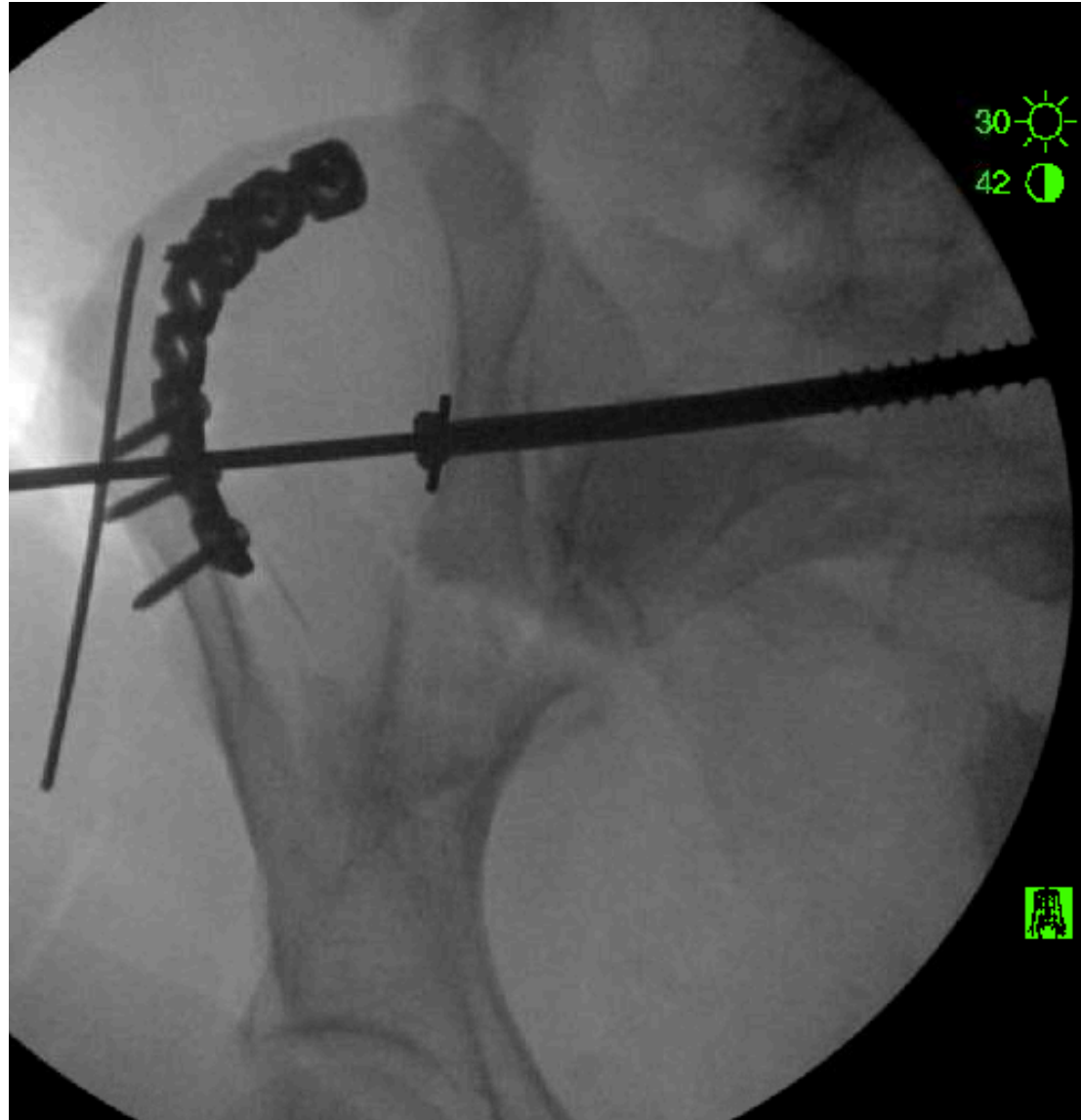


FIG 7. An LC2 screw was added AP
Obturator Oblique and Iliac Oblique views

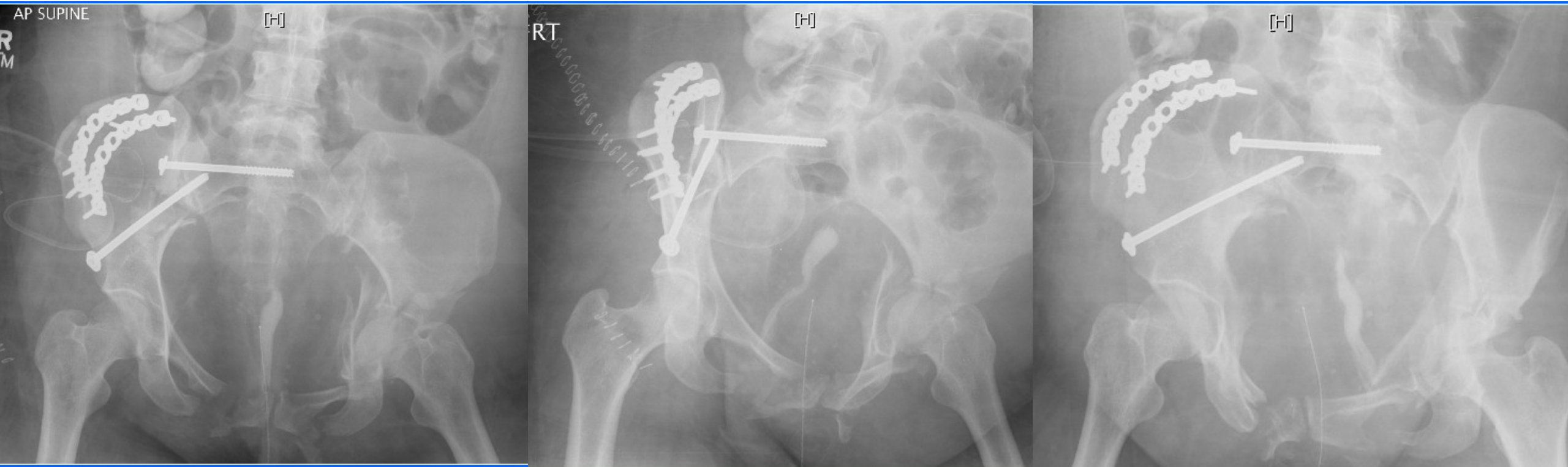


FIG 8 Left side fixed starting in the back by stabilizing the SI partial injury with an SI Screw

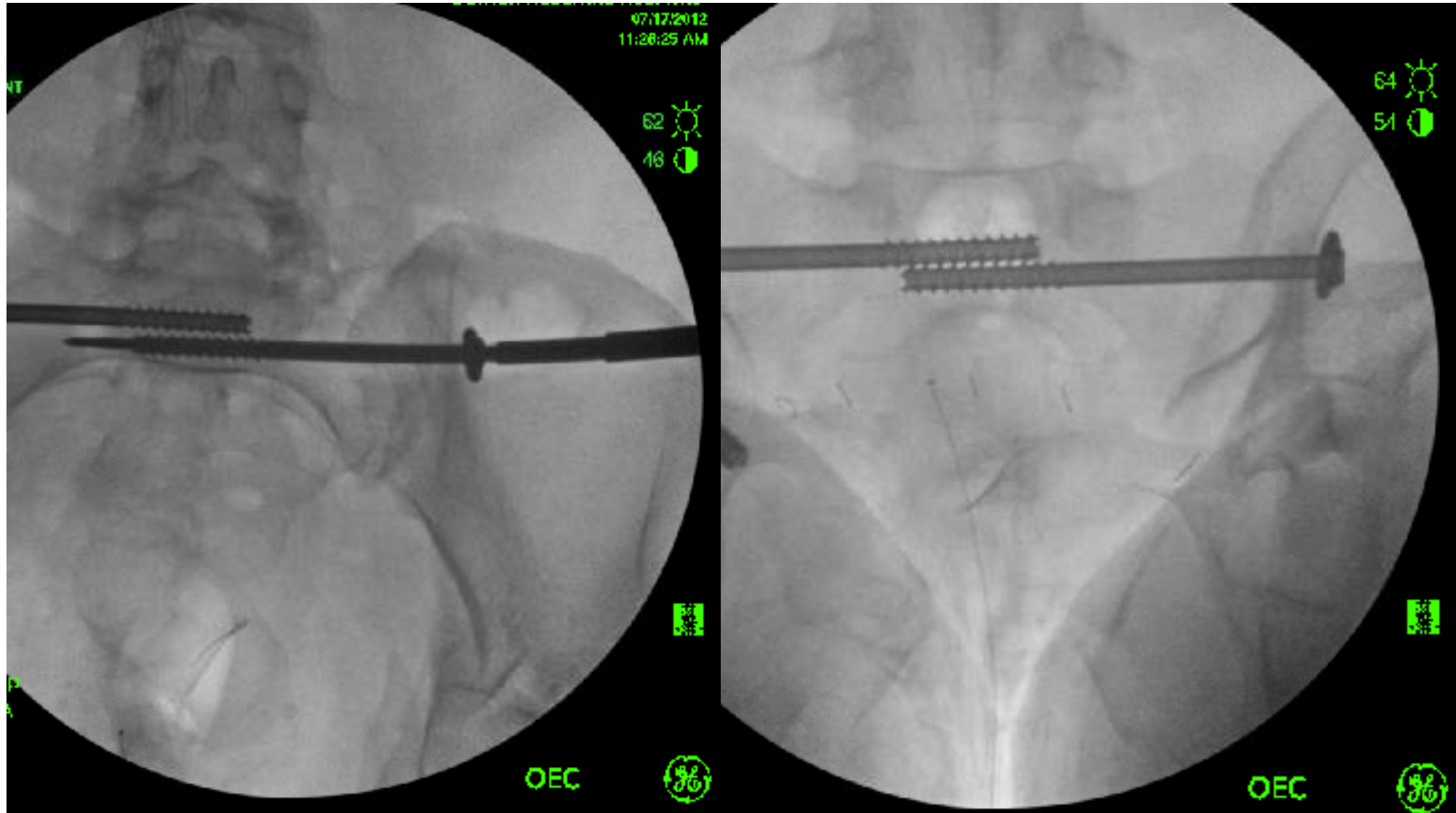


FIG 9 Reduction of iliac fracture, traction on the hip and acetabular dome

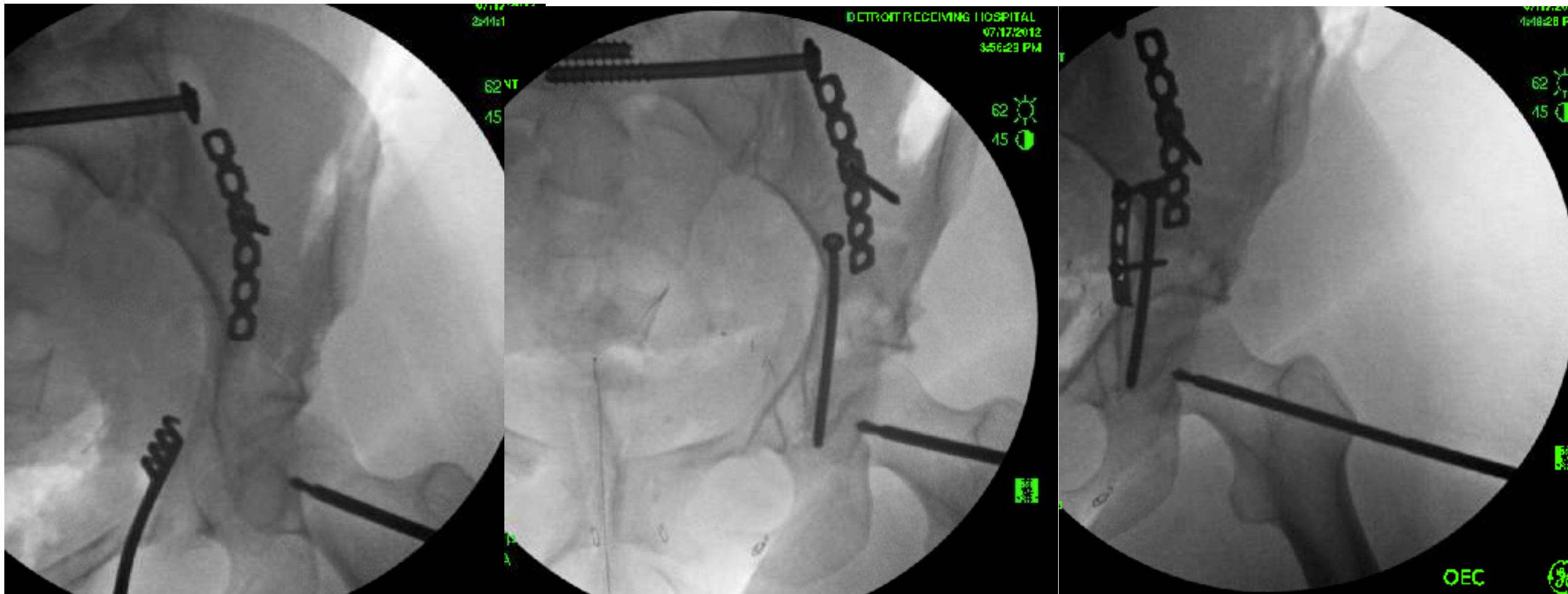


FIG 10 Anterior column and quadrilateral plate buttress and a front to back AILS toward PSIS screw to hold the low anterior column fragment

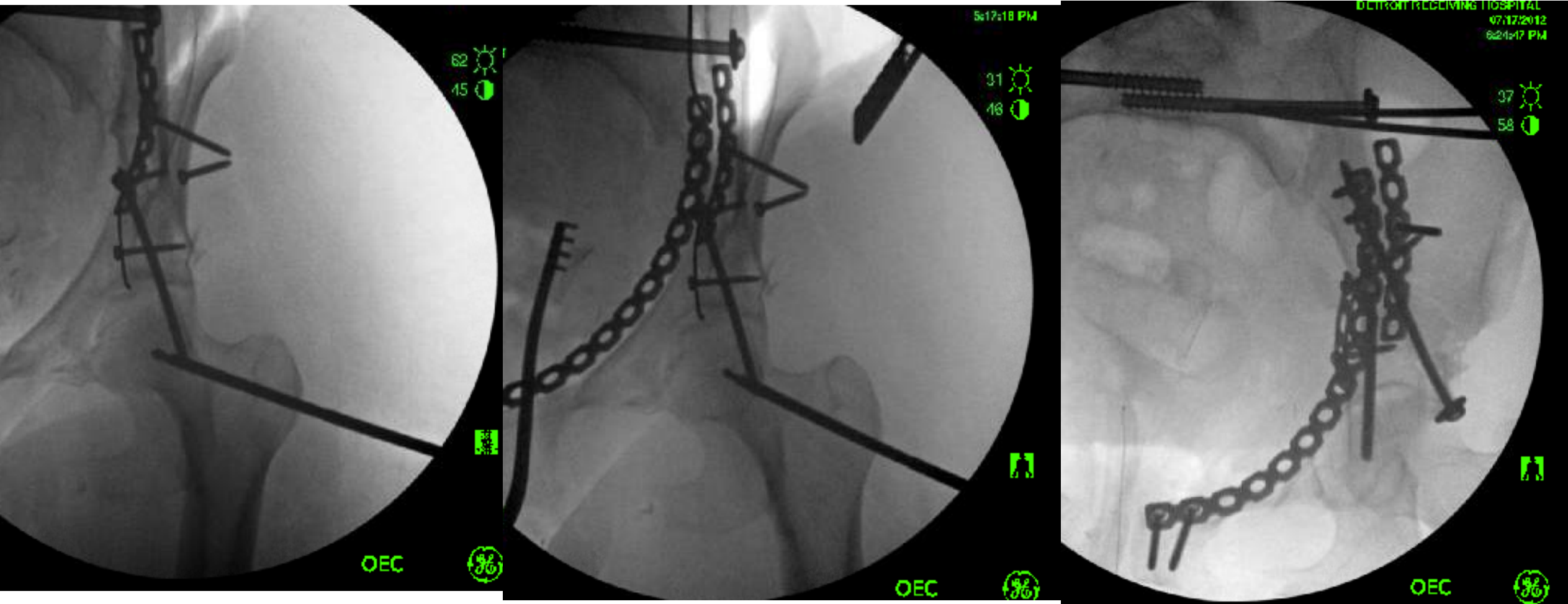


FIG 11 The patient started bleeding deep in the wound which had to be packed and the patient transfused. We stopped progression of the surgery

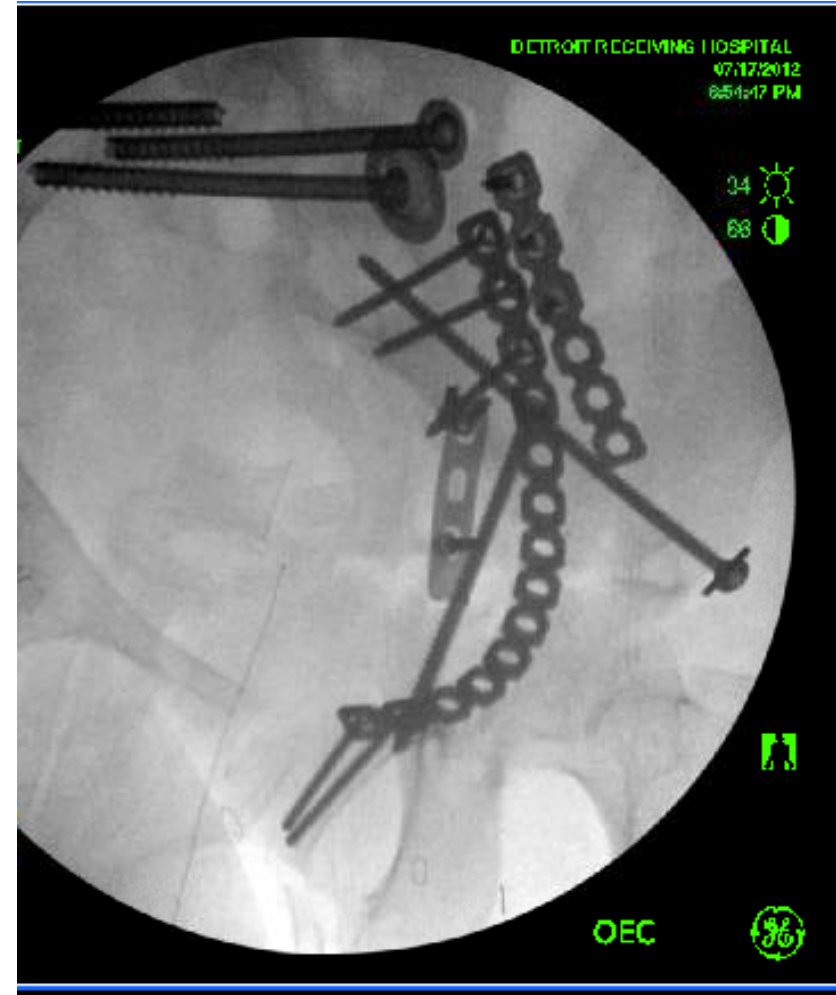
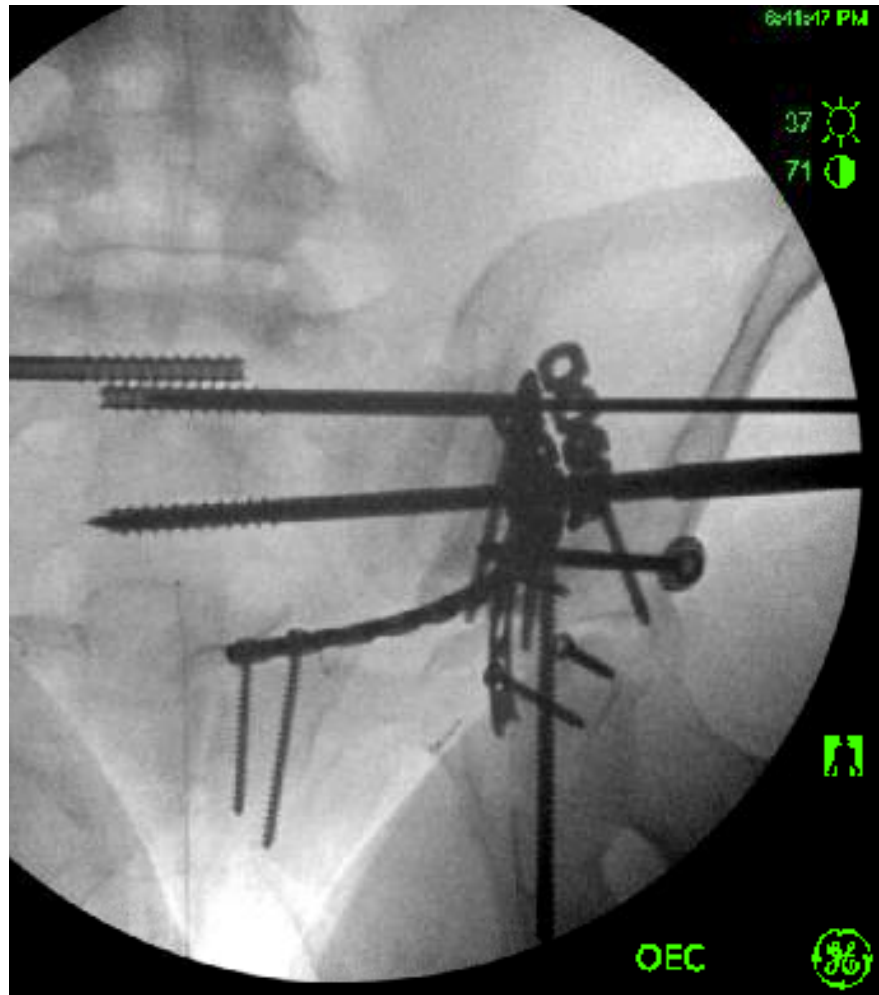


FIG 12 AP and INLET views

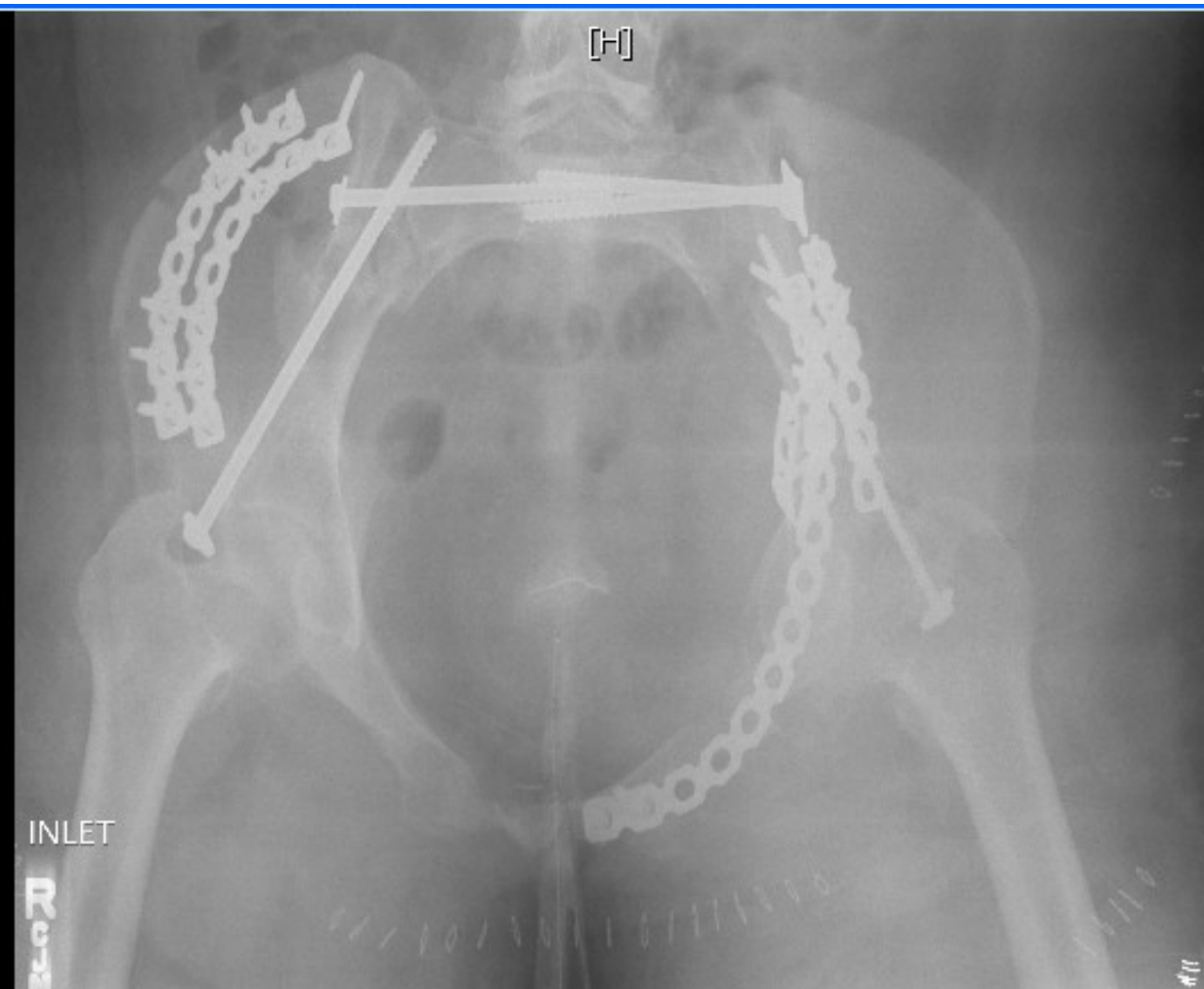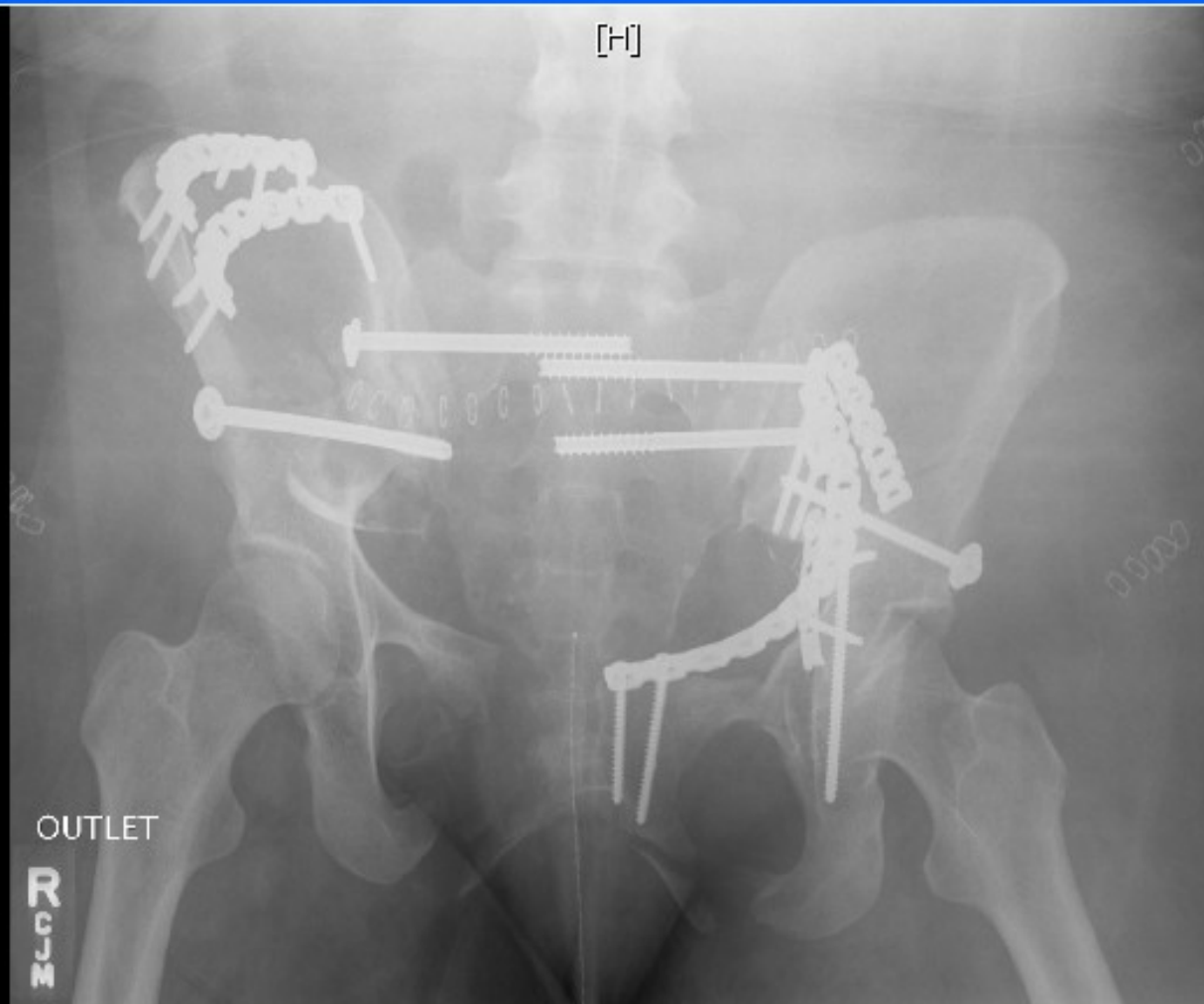


FIG 13 JUDET views

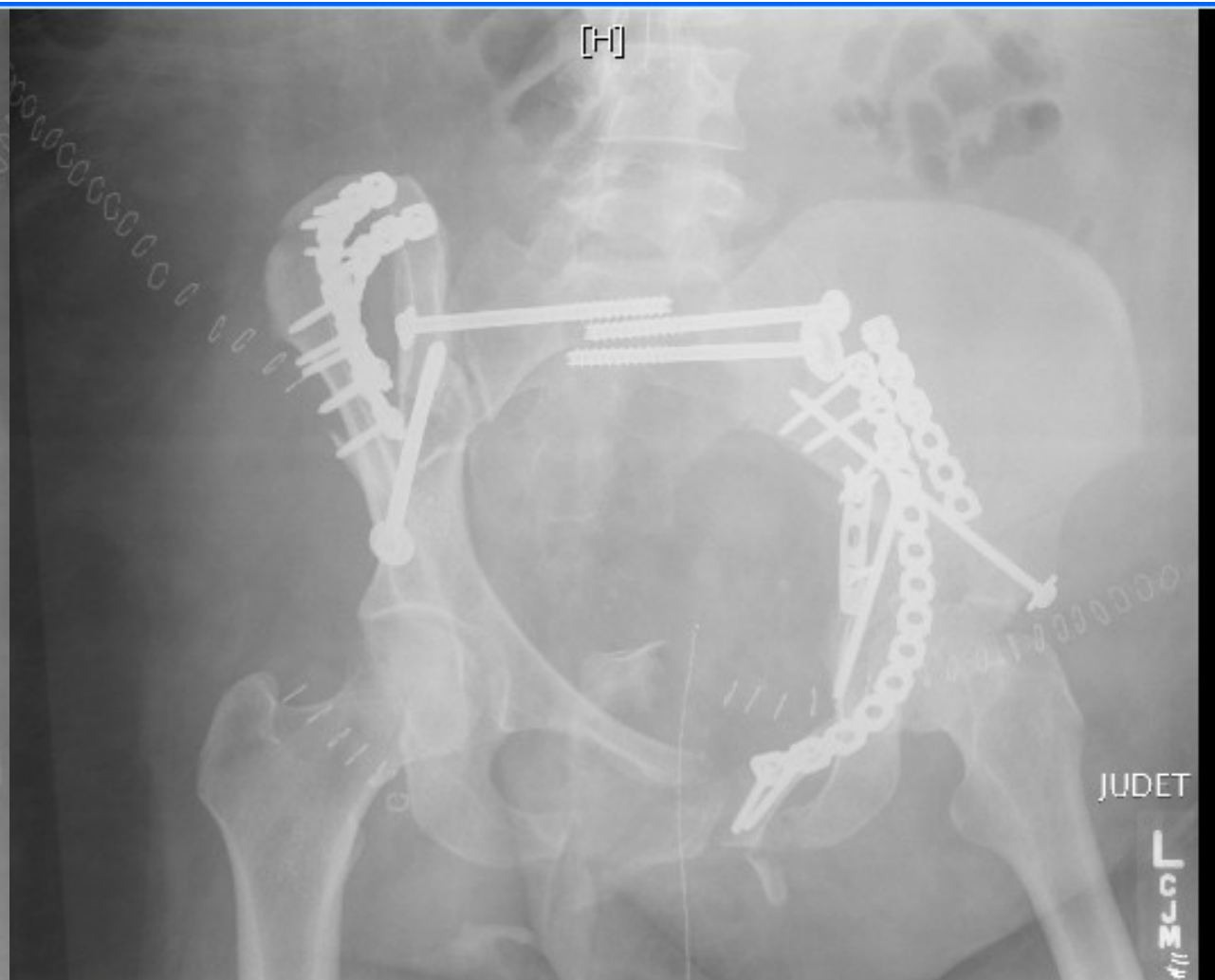
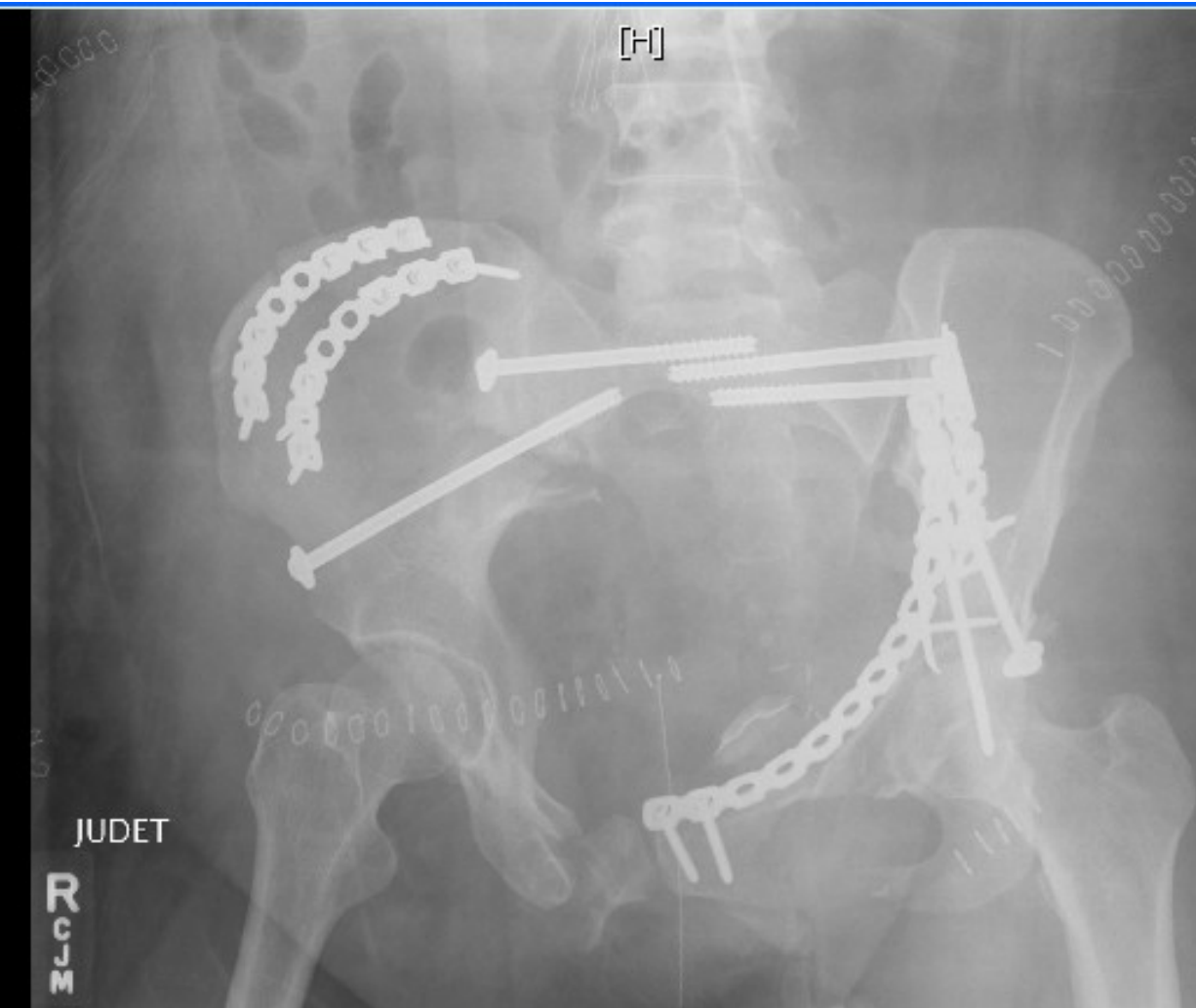


FIG 14 Subsequent bridging fixation with
INFIX 2 days later

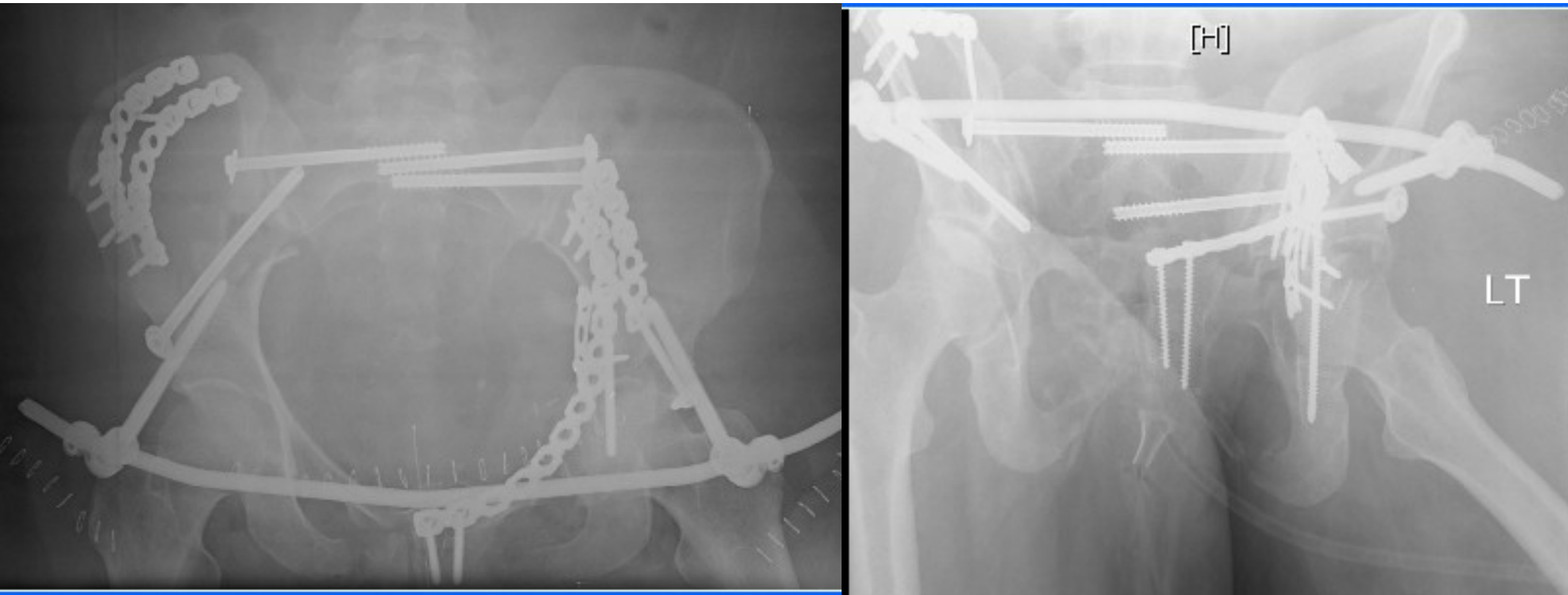


FIG 15
2 year FU
after INFIX
removal .
Patient goes
on to OA and
collapse of
the
acetabulum

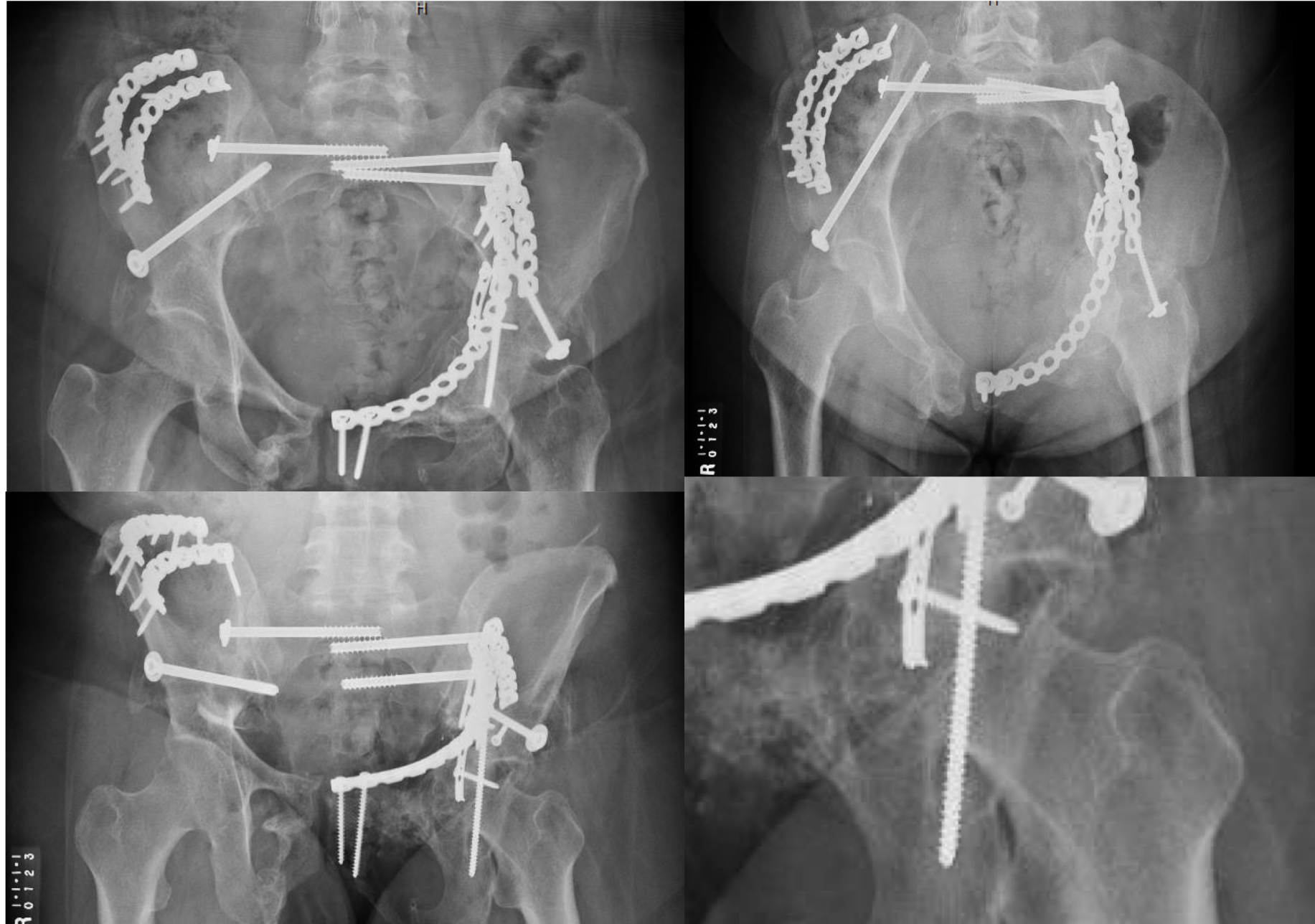

FIG 16
With subsequent
THA

