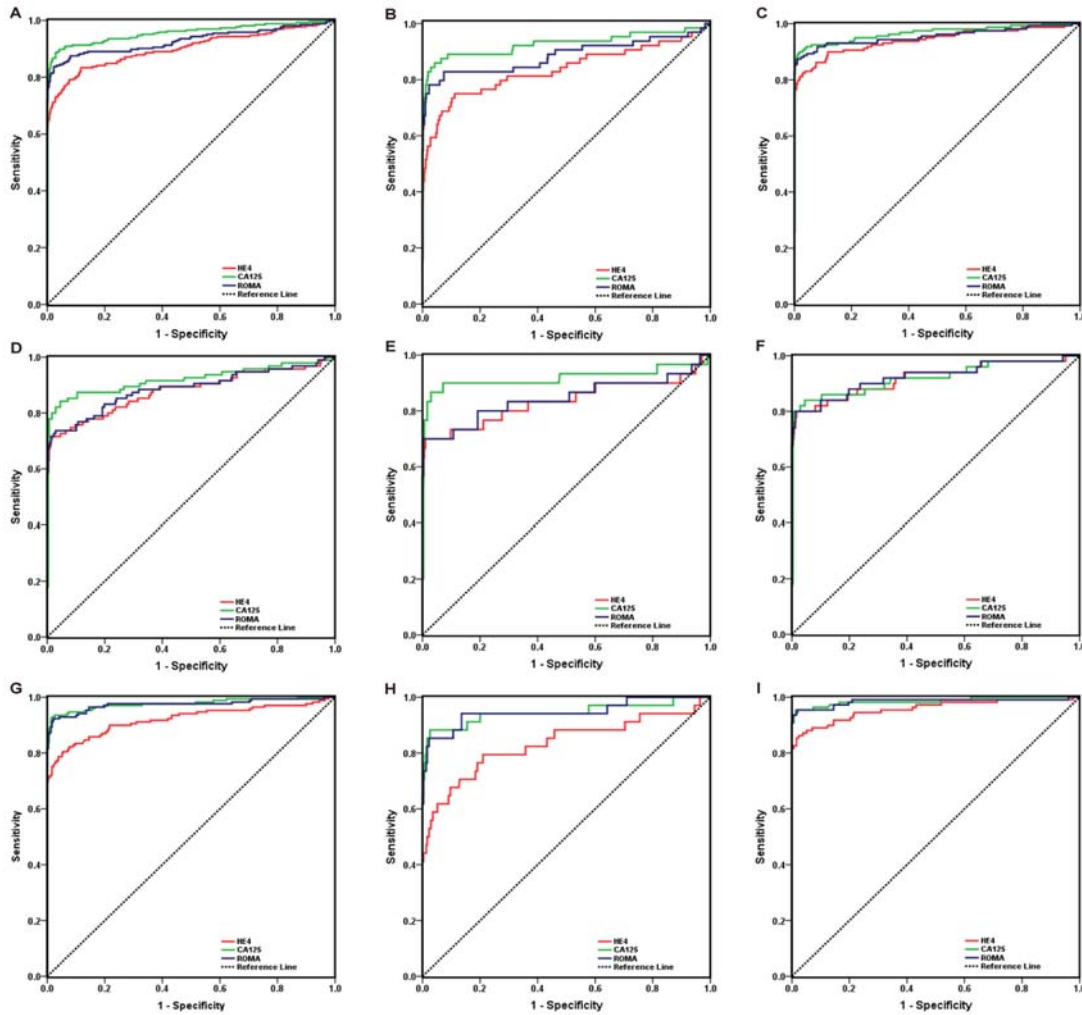


**Supplementary Figure 1.** Diagnostic accuracy of HE4, CA125, and ROMA in discriminating HC and EOC. (A): HC versus EOC; (B): HC versus Early stage EOC; (C): HC versus Advanced stage EOC; (D): Premeno HC versus EOC; (E): Premeno HC versus Early stage EOC; (F): Premeno HC versus Advanced stage EOC; (G): Postmeno HC versus EOC; (H): Postmeno HC versus Early stage EOC; (I): Postmeno HC versus Advanced stage EOC; HC: healthy control; EOC: epithelial ovarian cancer.



**Supplementary Figure 2.** Diagnostic accuracy of HE4, CA125, and ROMA in discriminating BPM and EOC. (A): BPM versus EOC; (B): BPM versus Early stage EOC; (C): BPM versus Advanced stage EOC; (D): Premeno BPM versus EOC; (E): Premeno BPM versus Early stage EOC; (F): Premeno BPM versus Advanced stage EOC; (G): Postmeno BPM versus EOC; (H): Postmeno BPM versus Early stage EOC; (I): Postmeno

BPM versus Advanced stage EOC; BPM: benign pelvic mass; EOC: epithelial ovarian cancer.

