

AN UNUSUAL USE OF THE CRONIN BREAST PROSTHESIS

Case Report

ROGER J. BARTELS, M.D., JOSEPH E. O'MALLEY, M.D., WILLIAM M. DOUGLAS, M.D., AND ROY G. WILSON, M.D.

Orlando, Fla.

The use of tissue from the buttocks to augment the breast is a time-honored procedure. In the following case the breast repays its debt to the buttocks.

CASE REPORT

A 33-year-old white female presented with a history of "sinking in" of her left buttock,

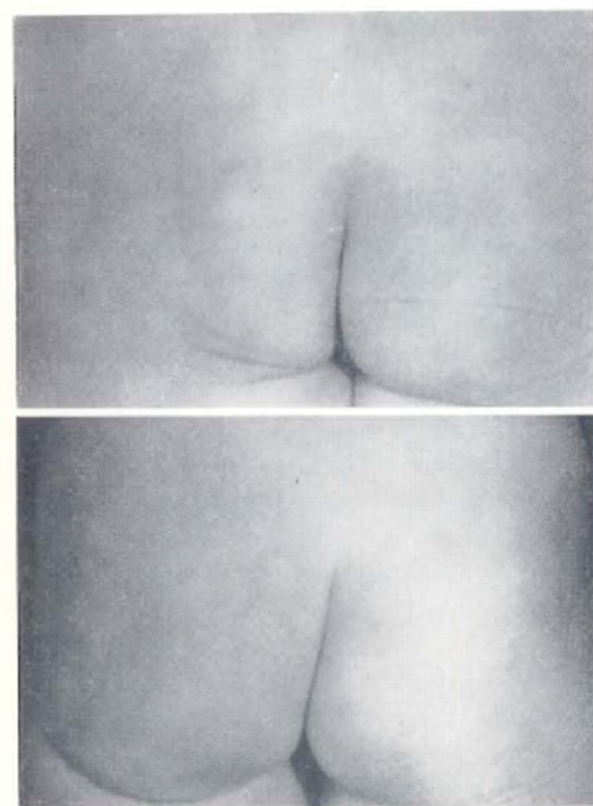


FIG. 1. Preoperative and postoperative appearance.

which began at age 26 and was progressive over the next 7 years. A few months prior to her hospital admission sitting became painful—presumably due to pressure on the sciatic nerve. There was no history of trauma or illness preceding the atrophy.

Examination of the patient revealed marked atrophy of the left gluteal muscles. The remainder of the physical examination, including the neurological examination, was normal. Roentgenograms of the chest, pelvis and lumbosacral spine were not remarkable; a myelogram was also normal.

The patient's left gluteal area was explored through an incision made in the inferior fold. No gluteal musculature could be found. The sciatic nerve appeared normal. A medium-sized Cronin breast prosthesis was then placed in the appropriate location and the wound closed. Her postoperative course was uncomplicated.

Following the operation her buttocks had a pleasing appearance—indeed the left side was somewhat better than the right (Fig. 1). She has experienced no pain on sitting.

The patient has been followed 5 years since her surgery; she retains her pain-free status and buttocks contour.

SUMMARY

A case is presented of idiopathic gluteal atrophy, treated with a Cronin breast prosthesis.

*Roger J. Bartels, M.D.
94 West Underwood St.
Orlando, Fla.*

From the Department of Plastic Surgery, Orange Memorial Hospital.