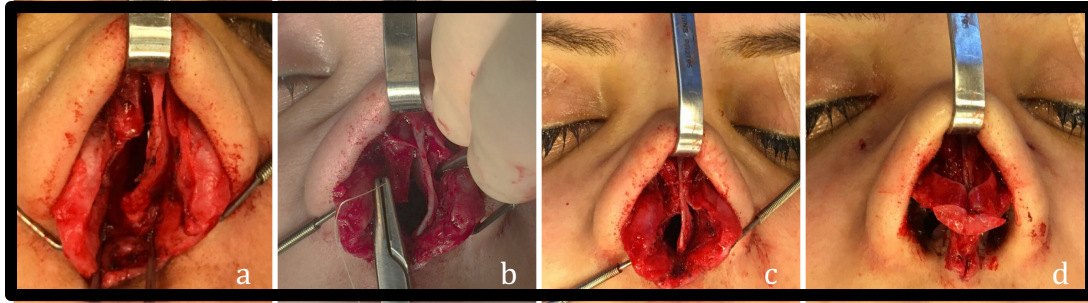


*Supplemental figure 1: Underlying Cartilaginous Framework: Case 1*



a.) Severe caudal septal deviation demonstrated. b.) illustrating spreader flap in-folding. c.) straightened septal cartilage after caudal septal trim, midvault reconstruction with bilateral spreader flaps, septal straightening after suture. d.) butterfly graft placement depicted