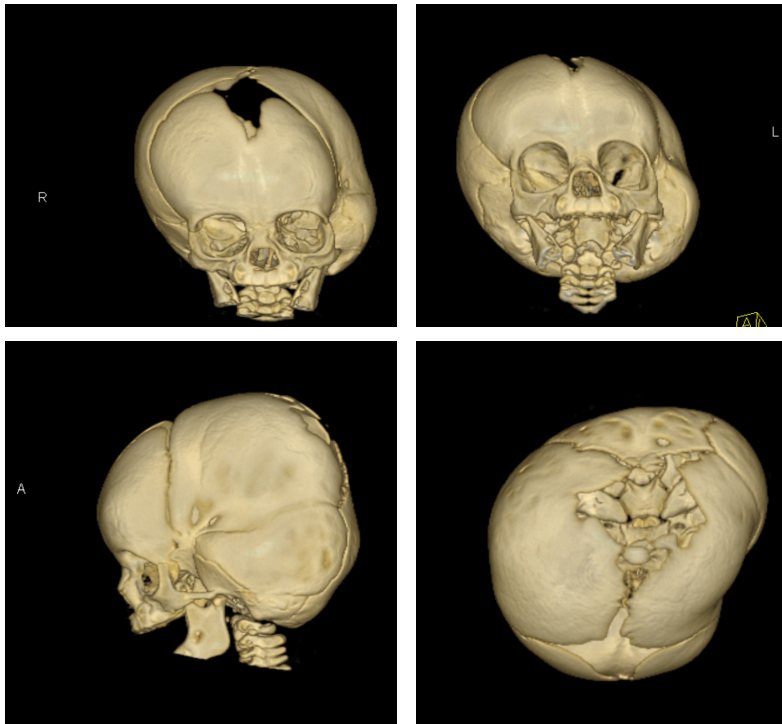
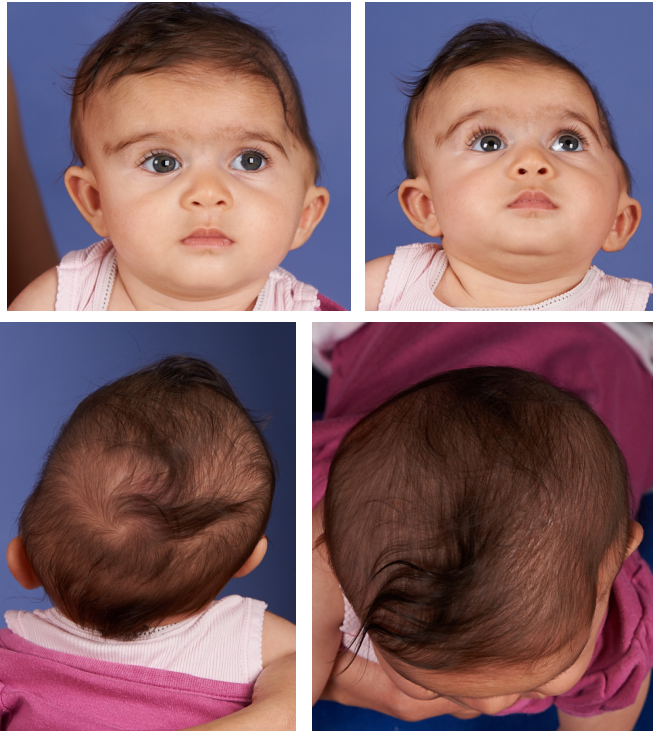
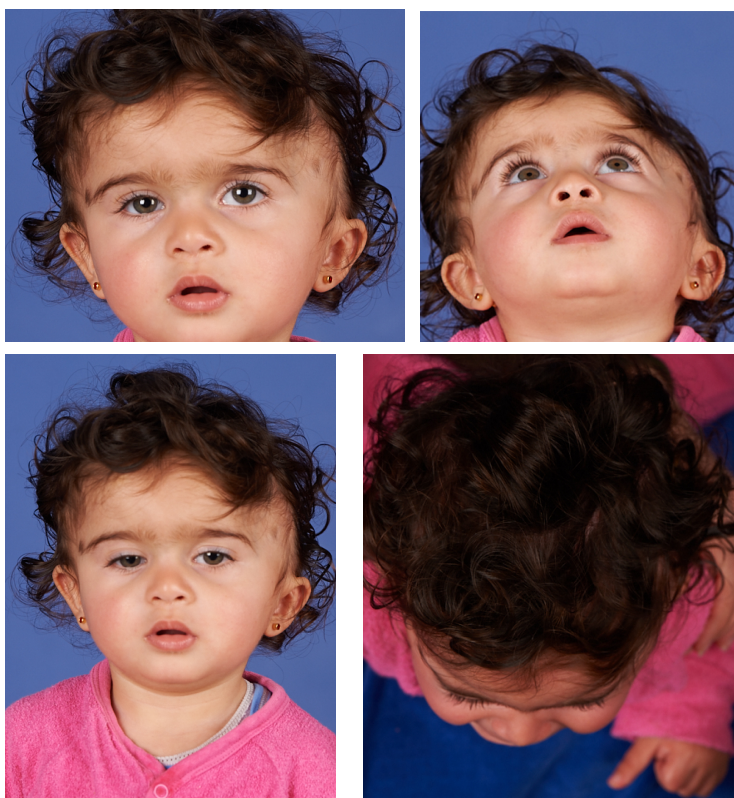Supplemental Digital Content 1. Pre-operative CT scans; child aged 5 months old.



Supplemental Digital Content 2. Pre-operative photos taken at the initial consultation in the Craniofacial Clinic; child aged 4 months old.



Supplemental Digital Content 3. Photos taken at 9 months' post-surgery; child aged 15 months old.

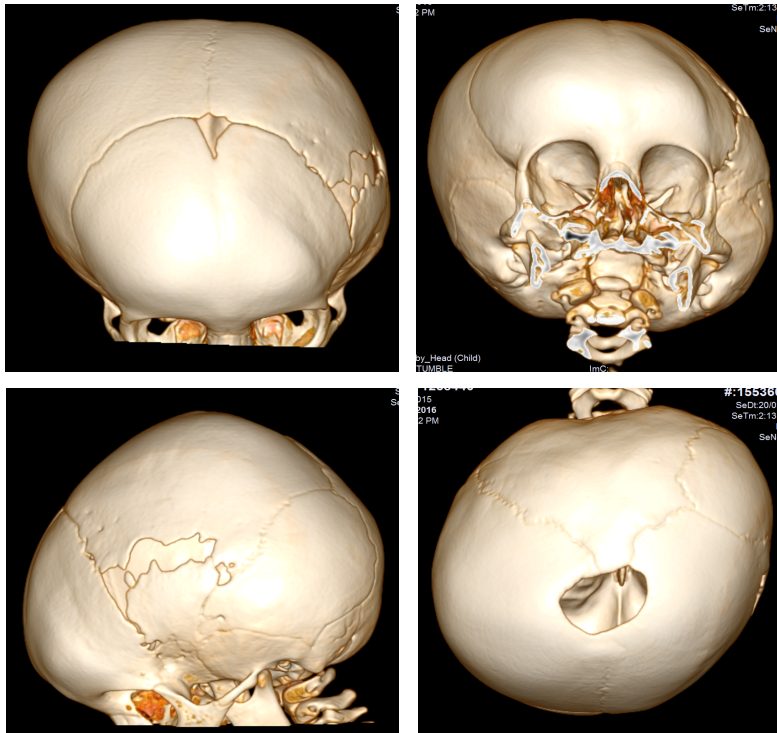


Figure 4. Post-operative CT scans, performed 9 months' post-surgery; child aged 15 months old.