


Microsurgical Scalp Replantation after Avulsion

Total scalp avulsion (TSA), a severe soft tissue injury, is often treated through microvascular scalp replantation



However, aesthetic concerns remain

Microsurgical scalp replantation in a 21-year-old woman with TSA

Day 0

- Re-anastomosis of the superficial temporal artery using an 8 cm vein graft
- Re-anastomosis of two veins

Successful replantation

Day 21

- Excision of necrosis caused by a pressure-induced lesion
- Application of split-thickness skin graft

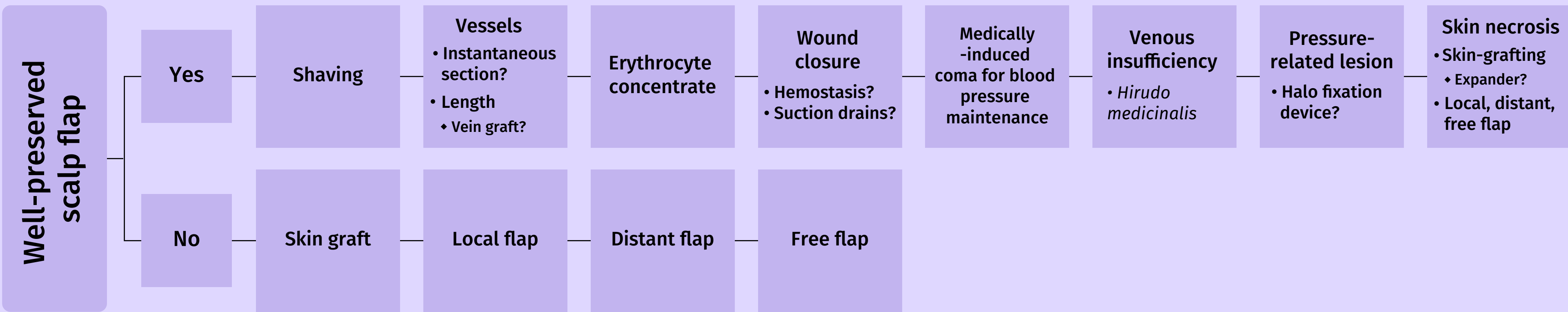
Hairless area at the occiput

Month 8

- Explantation of expander to cover hairless area

Excellent aesthetic outcomes

Flowchart for clinical decision-making



Scalp replantation should be the first choice of treatment in cases of total scalp avulsion, and good aesthetic outcomes can be achieved using an expander despite partial skin necrosis