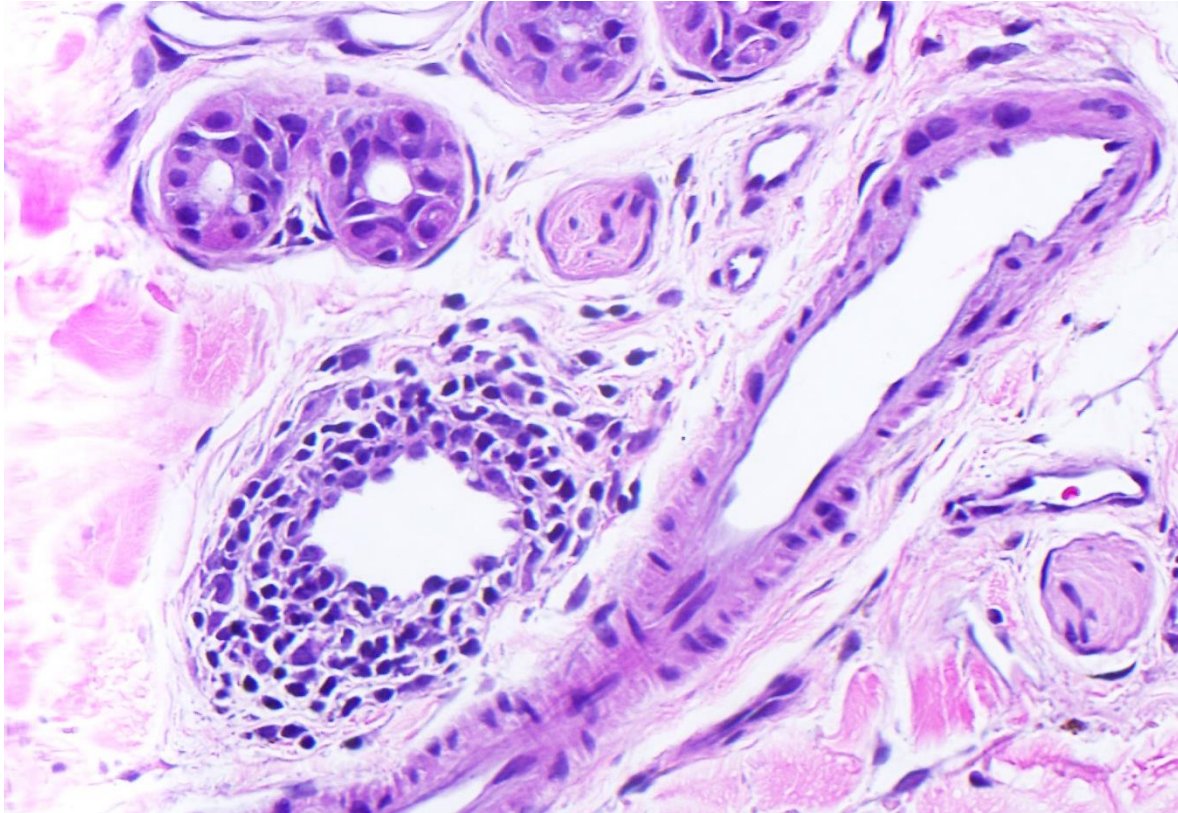


Lymphocytic Vasculitis Associated with Mild Rejection in a Vascularized Composite Allograft Recipient: A Clinicopathological Study



- **Canada's first facial Vascularized Composite Allograft (34 biopsies over 430 days)**
- **Retrospective histological review of the dermal inflammatory infiltrates and vascular damage (lymphocytic vasculitis) associated with mild rejection**
- **Lymphocytic vasculitis in mild acute rejection may indicate insufficient immunosuppression**

SF Roy et al. *Transplantation*. July 2020

@SimonRoyMD
@TransplantJrnl

Copyright © 2020 Wolters Kluwer Health, Inc. All rights reserved

Transplantation®

