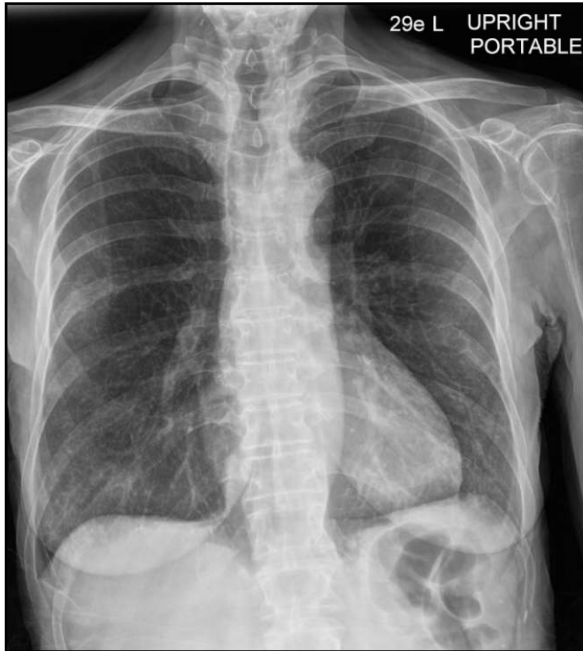

Supplement

Hospital Day 1



Hospital Day 6

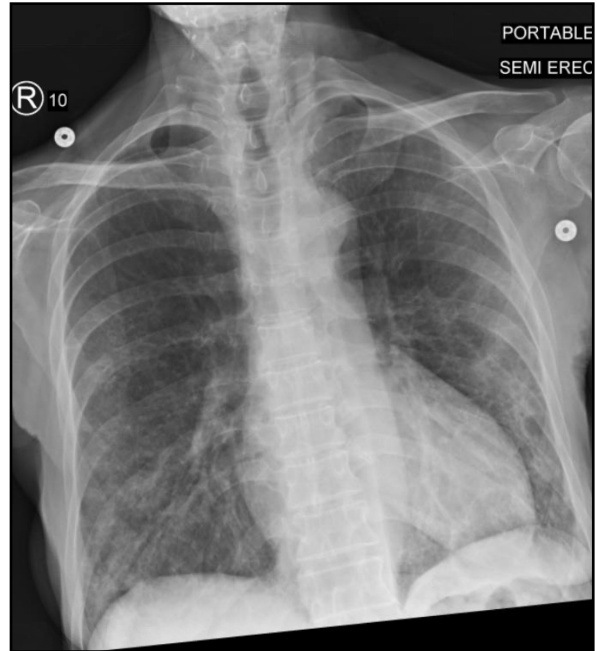


Figure S1. Imaging, X-Ray, Day of admission and hospital day 6. Subtle hazy opacities and emphysematous changes were evident in the lower lung fields bilaterally on the day of admission and hospital day 6.

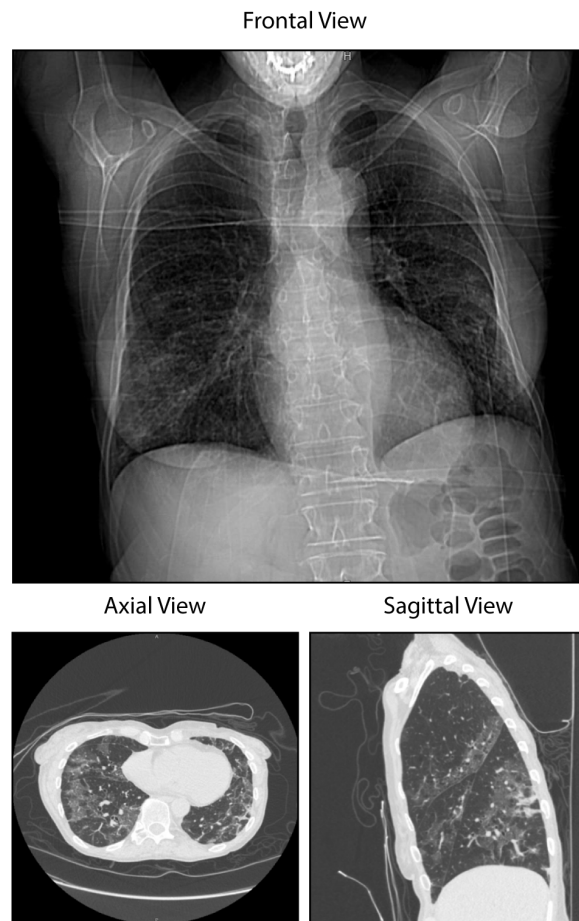


Figure S2. Imaging, Pulmonary CT, hospital day 8. Bilateral multifocal basilar groundglass infiltrates consistent with COVID-19 pneumonia were evident on CT imaging.

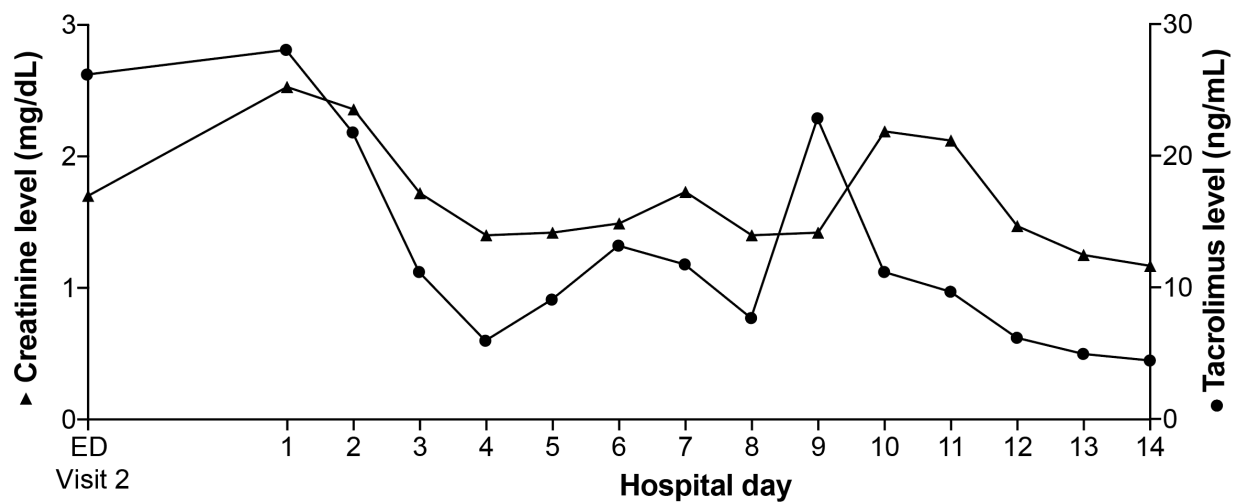


Figure S3. Correlation between creatine and tacrolimus levels. Tacrolimus peaks preceded creatinine kinase peaks.