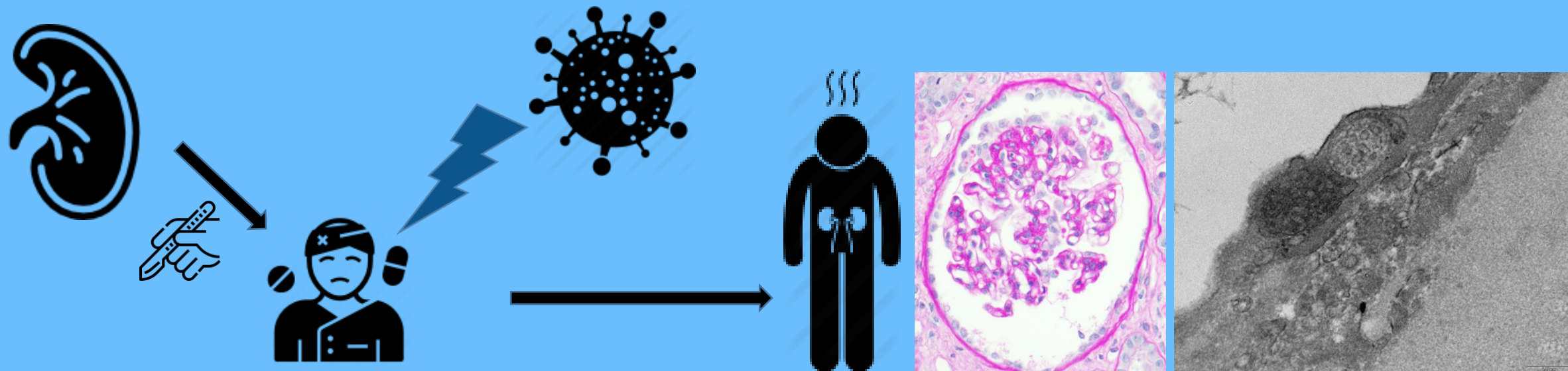


De novo focal and segmental glomerulosclerosis after COVID-19 in a patient with a transplanted kidney from a donor with a high-risk APOL1 variant

Kidney transplantation with a high risk donor *APOL1* genotype (G2/G2)

Non severe COVID-19 five weeks after kidney transplantation

Two weeks after COVID-19, nephrotic syndrome associated with de novo FSGS and endothelial tubulo-reticular inclusions



Conclusion :

SARS-CoV2 infection may act as a second hit for FSGS after kidney transplantation from donor with high risk *APOL1* variants

Oniszczyk et al. *Transplantation*. 2021

@TransplantJrnl

Copyright © 2021 Wolters Kluwer Health, Inc. All rights reserved

Transplantation®

