

# A 64-year-old man acutely developed right hemianopsia

TEACHING *NEUROIMAGES*  
*NEUROLOGY*  
RESIDENT AND FELLOW SECTION

# VIGNETTE

- Neurological examination: right hemianopsia
- Physical examination: hemangioma on the left side of the neck
- No identifiable cerebro-vascular risk factor was detected

# IMAGING

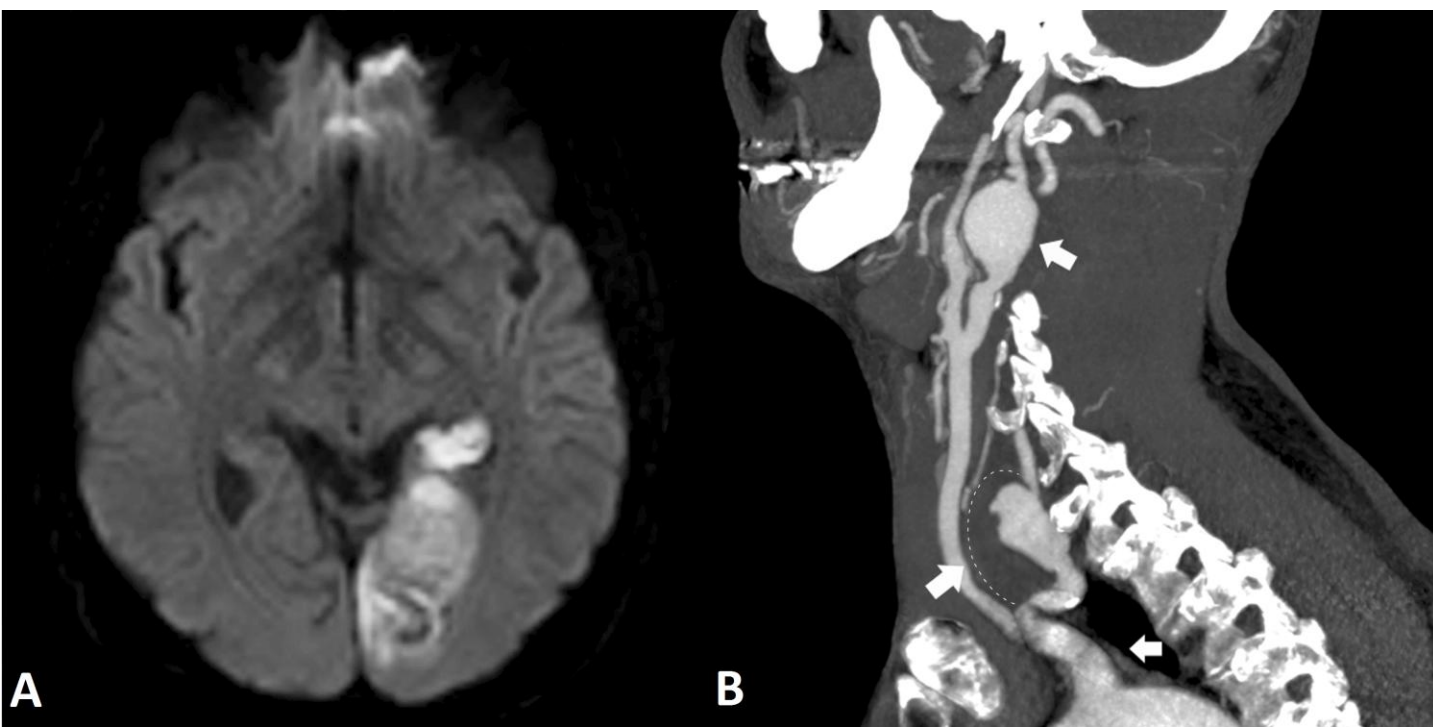


Figure 1

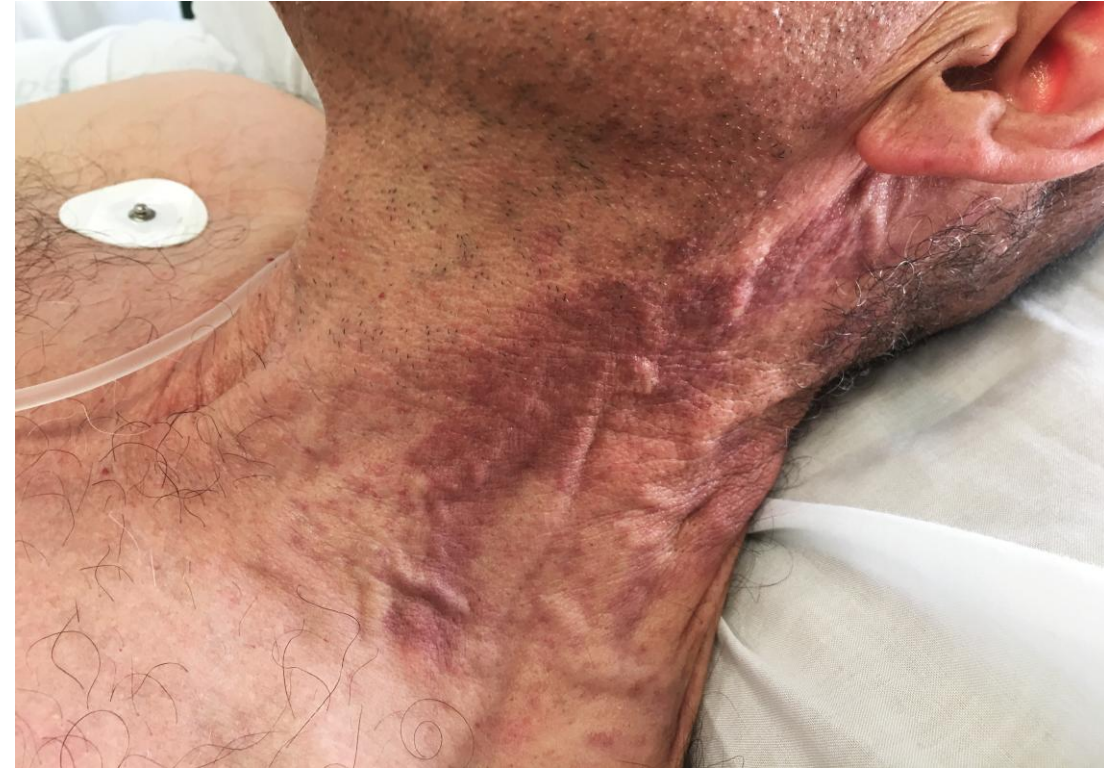

Figure 2

# A cutaneous vascular malformation hides giant cerebral aneurysms

## Conclusions:

- Embolization from thrombosed aneurysm is a possible cause of stroke
- Cutaneous vascular malformations in the face or neck areas can be associated with cerebrovascular malformations and should prompt an evaluation of the cerebral circulation