

# A 29 year old man with head jerks

Teaching NeuroImages

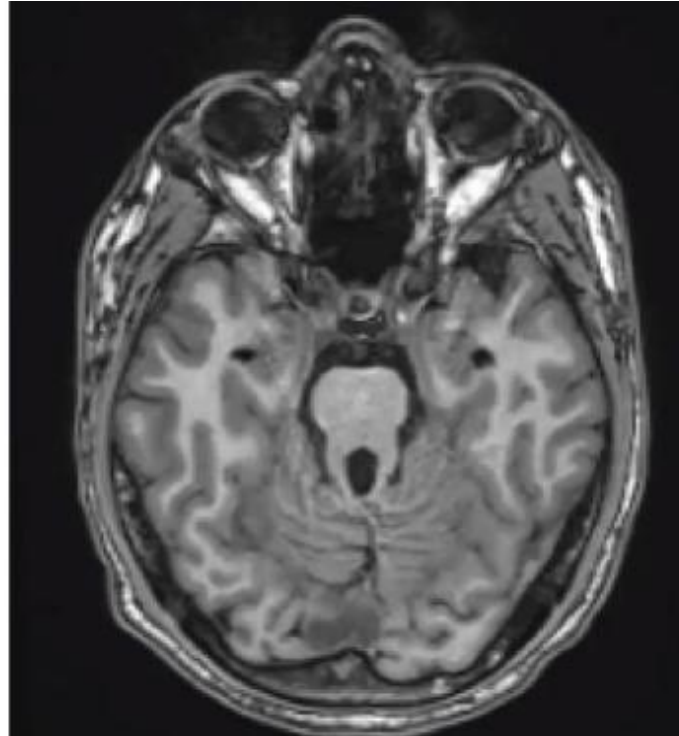
*Neurology*

Resident & Fellow Section

# Vignette

- 29 year old man
- Repetitive head jerks since first year of life
- Previous diagnosis of a tic disorder based on head jerking movements
- Examination revealed difficulties initiating voluntary saccades in the horizontal plane and disturbed hand-eye coordination with compensatory head thrusts

# Imaging



# Video



# Characteristic head jerks in congenital oculomotor apraxia due to Joubert syndrome

- Joubert syndrome is a rare autosomal-recessive ciliopathy with genetic heterogeneity<sup>1</sup>
- It is a common etiology of congenital oculomotor apraxia (COMA)
- COMA was first described by Cogan, who considered compensatory head jerks diagnostic<sup>2</sup>