

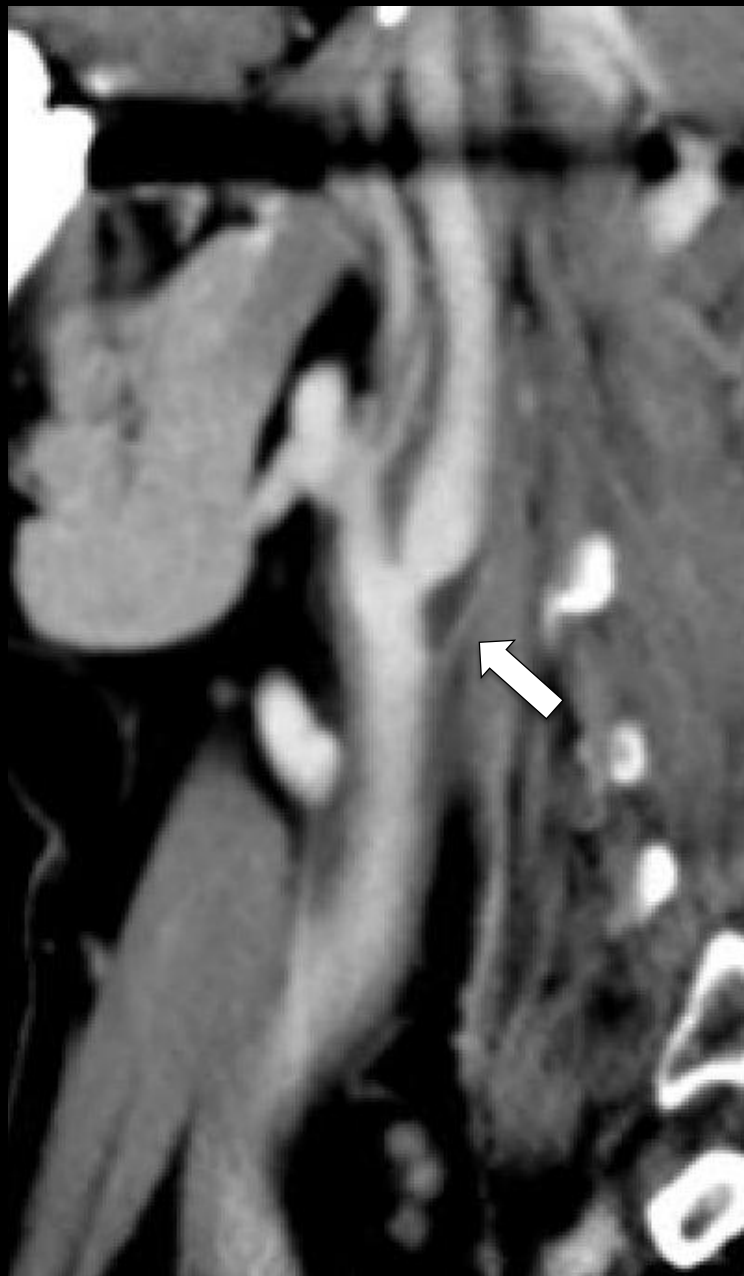
# Teaching Neuroimages

Neurology Resident and Fellow  
Section

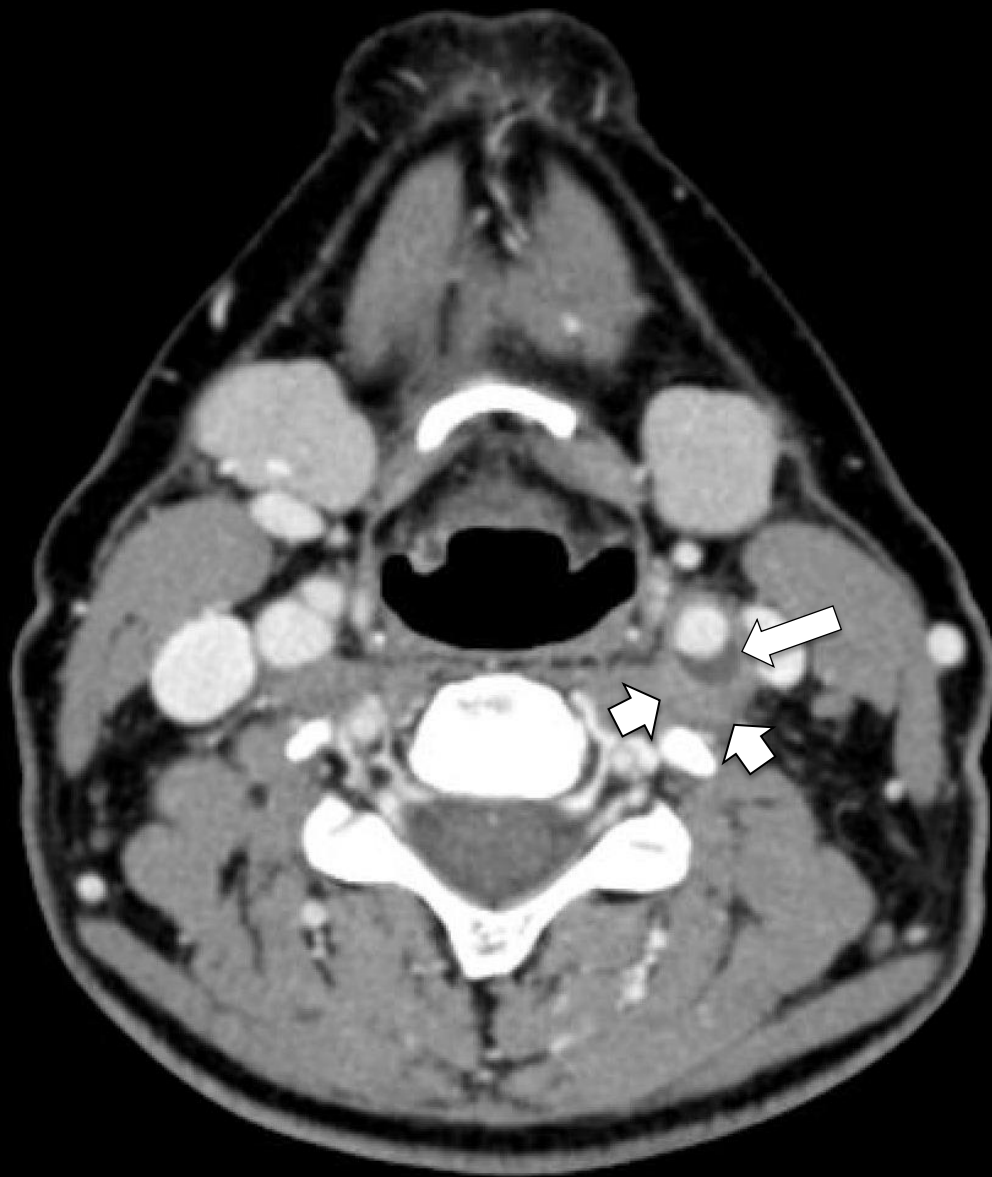
**A 54-year woman with neck pain**

# Vignette

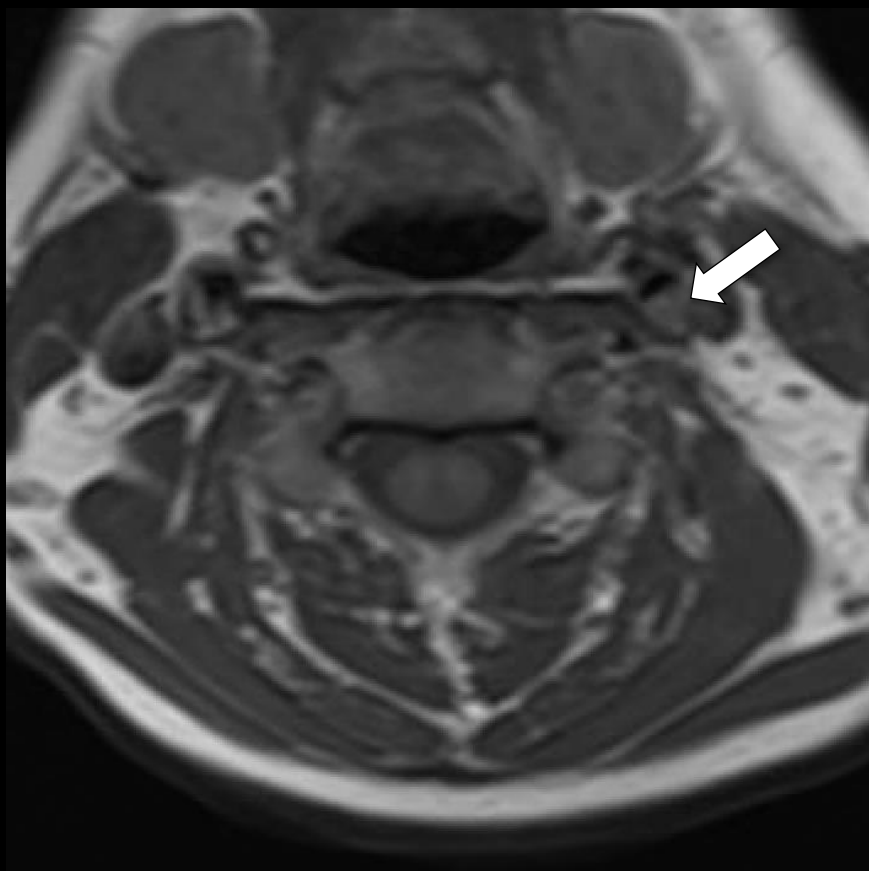
- A healthy 54-year-old woman developed spontaneous acute onset of sharp left-sided neck and facial pain and odynophagia following a brief flu-like illness.
- Physical exam and neurological exam were unremarkable



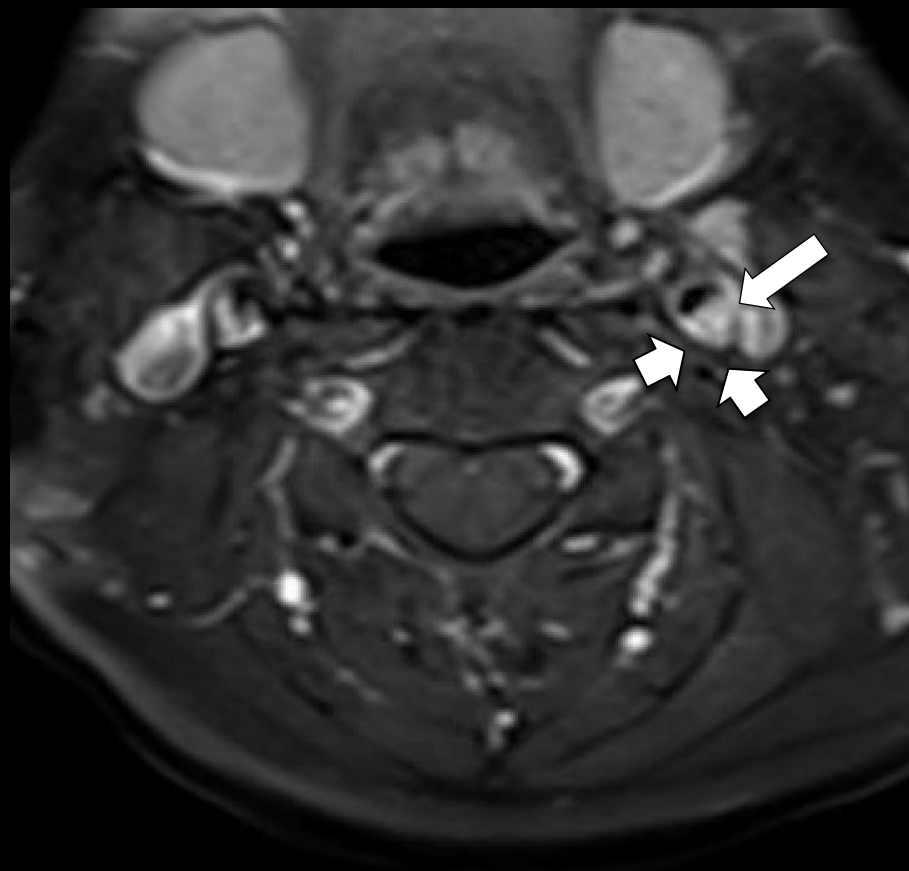
A. CT Angiogram (sagittal)



B. CT Angiogram (axial)



A. Non-contrast T1WI



B. T1 fat-sat post gadolinium

# Transient Perivascular Inflammation of the Carotid Artery (TIPIC)

- Transient Perivascular Inflammation of the Carotid artery (TIPIC), is a rare, self-limited entity distinguishable on vascular imaging from extracranial dissection by lack of luminal narrowing and marked perivascular inflammation.
- Reported treatments include NSAIDs, antiplatelet agents, and steroids. There is no known associated risk of stroke. Pain typically resolves within two weeks, with radiological improvement by three months.