A 59-year-old man with acute callosal disconnection

Teaching NeuroImages

Neurology®

Resident & Fellow Section

AMERICAN ACADEMY OF NEUROLOGY®

Vignette

- A 59-year-old right-handed hypertensive diabetic and previously alcoholic man.
- Acute confusional state followed by apathy, dysexecutive syndrome, clumsy left hand, and apraxic gait.
- A year later, his wife noticed impaired hearing (audiometry revealed left neurossensorial loss).
- Neurologic examination: marked callosal apraxia (non-dominant limb ideomotor apraxia, disconnection variant), left stereoagnosis, and left hand agraphia (without aphasia).

AMERICAN ACADEMY OF NEUROLOGY®

Mourão LO, *et al.*

Video

AMERICAN ACADEMY OF NEUROLOGY®

Mourão LO, *et al.*

Images: MRI and Fluorescein Retinography

Figure 1

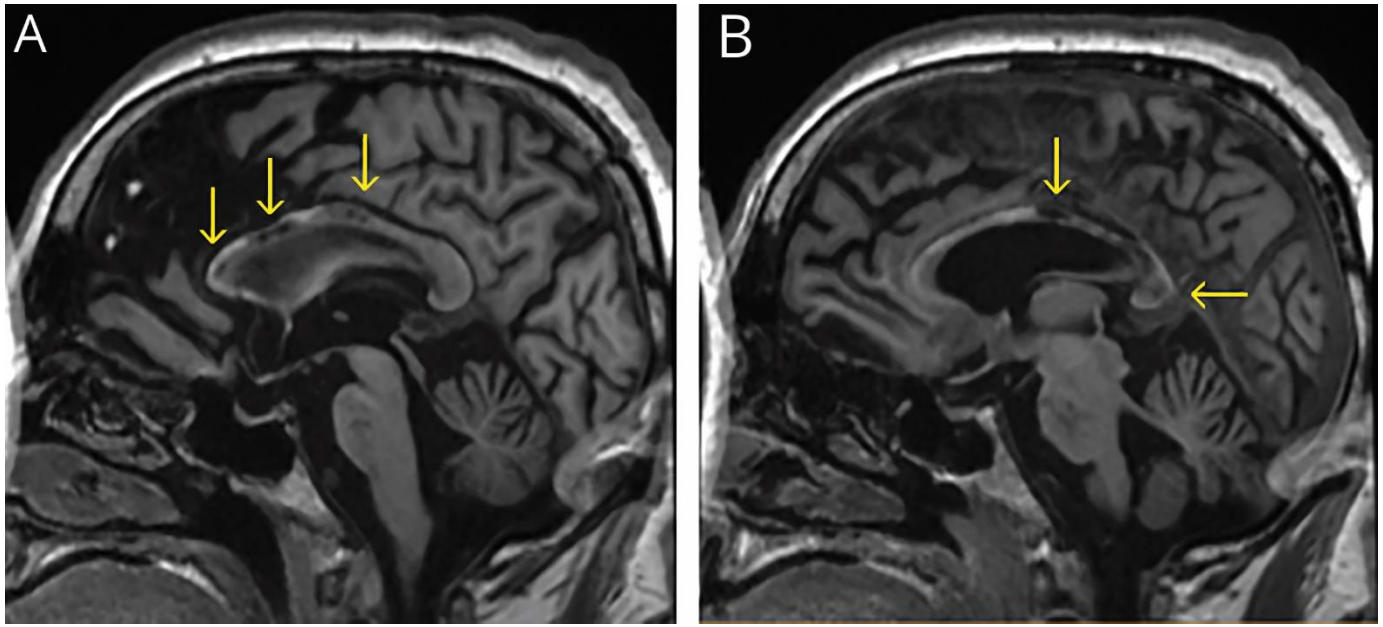

Figure 2

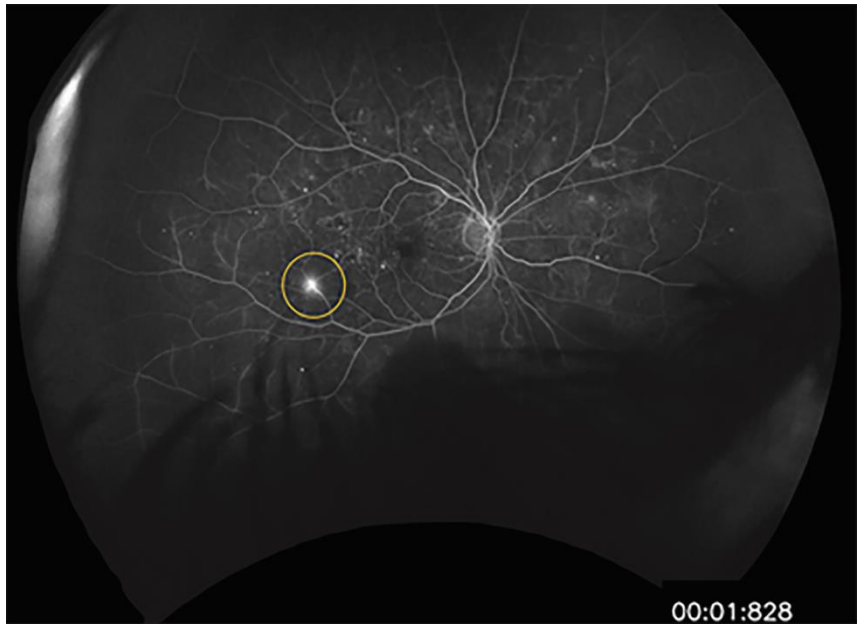

AMERICAN ACADEMY OF NEUROLOGY®

Mourão LO, *et al.*

Susac syndrome´s acute onset callosal disconnection

- Stereoagnosis due to callosal disconnection: tactile sensitivity is preserved but right hemisphere primary sensitivity cortex information cannot access the patient´s left hemisphere lexical region, therefore preventing him from naming objects he feels the shape with his left hand.
- MRI showed “punched out” holes through corpus callosum, sparing the calloso-septal interface.
- Audiometry revealed left neurossensorial lossFluorescein retinography demonstrated hyperfluorescence of arterial vessel wall. This exam should be performed whenever there is suspicion of Susac syndrome since patients may not have visual symptoms.
- Follow-up may be necessary: at disease onset only 13% of subjects have Susac triad 1 (encephalopathy 2, neurossensorial loss, and retinal endotheliopathy).

AMERICAN ACADEMY OF NEUROLOGY®

Mourão LO, *et al.*