

A 49-year-old woman with severe low back pain

Teaching NeurolImages

Neurology[®]

Resident & Fellow Section



Vignette

- A 49-year-old woman presented to orthopedic department with chief complaint of severe low back pain for 2 years
- On physical exam, no neurological deficiency were found.
- Laboratory investigations revealed no abnormalities. The serum uric acid was 351 μ mol/L.

Imaging

Figure 1

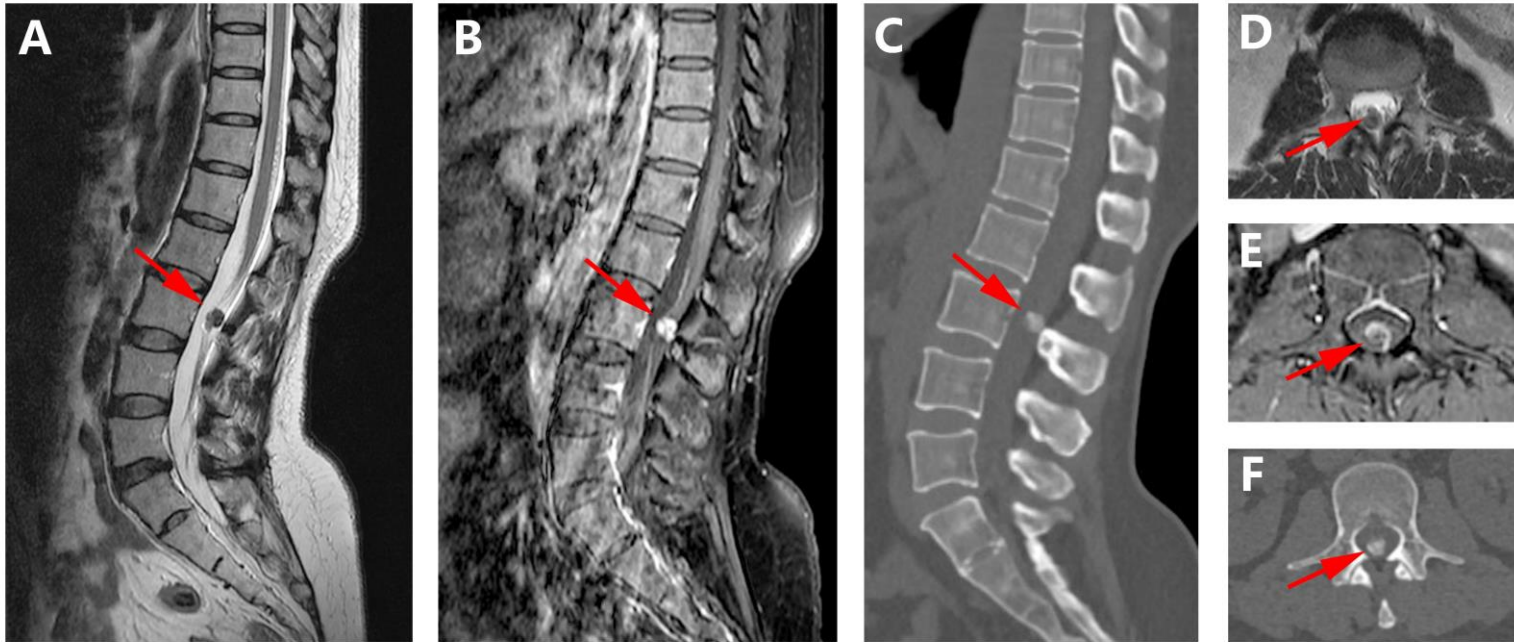
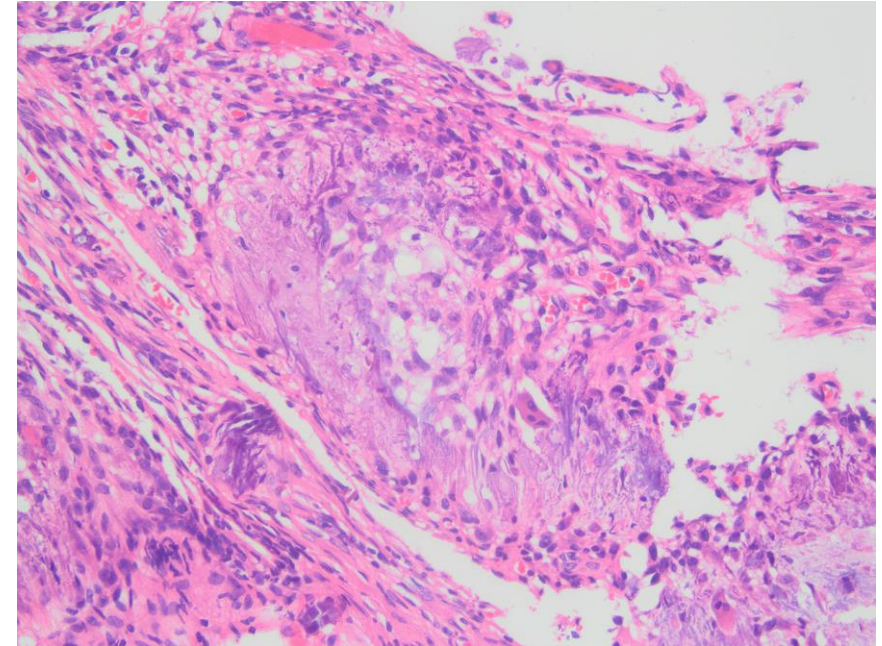


Figure 2



Intraspinal gouty tophus

- The mass containing tophaceous deposits was removed surgically.
- The pathology diagnosis was gouty tophus eventually, which is rarely presented in the spinal canal.^{1,2}
- After the surgery, the severe low back pain was disappeared.