

# Hutchinson's sign in Herpes Zoster Ophthalmicus

Teaching NeuroImages

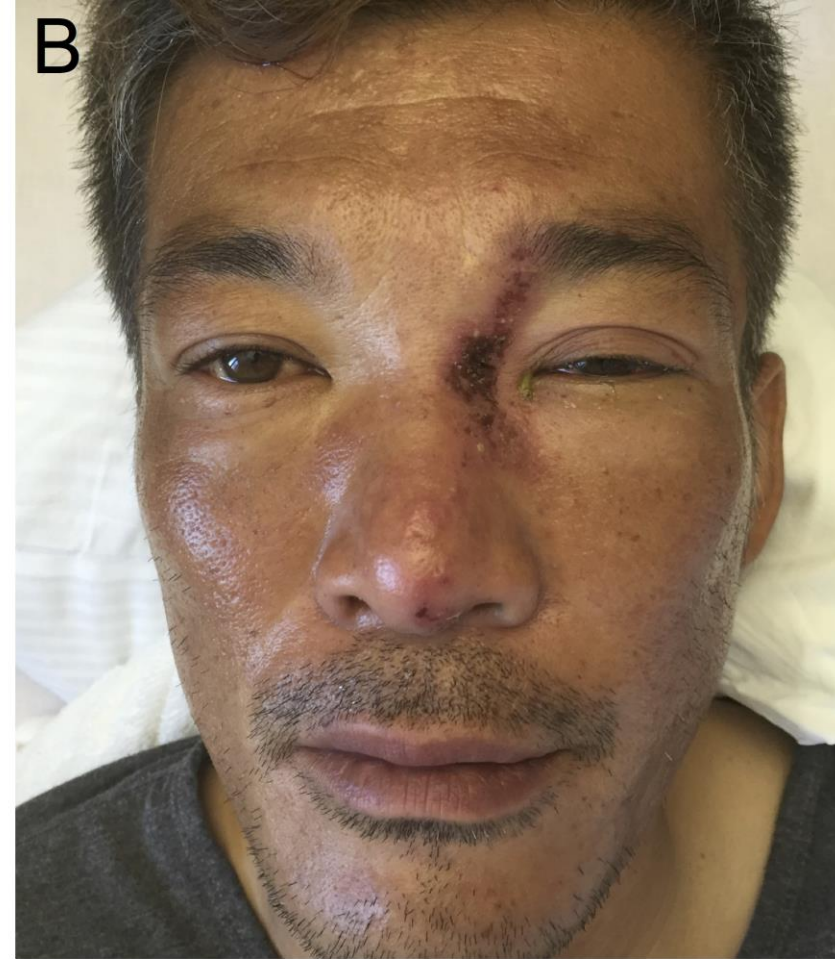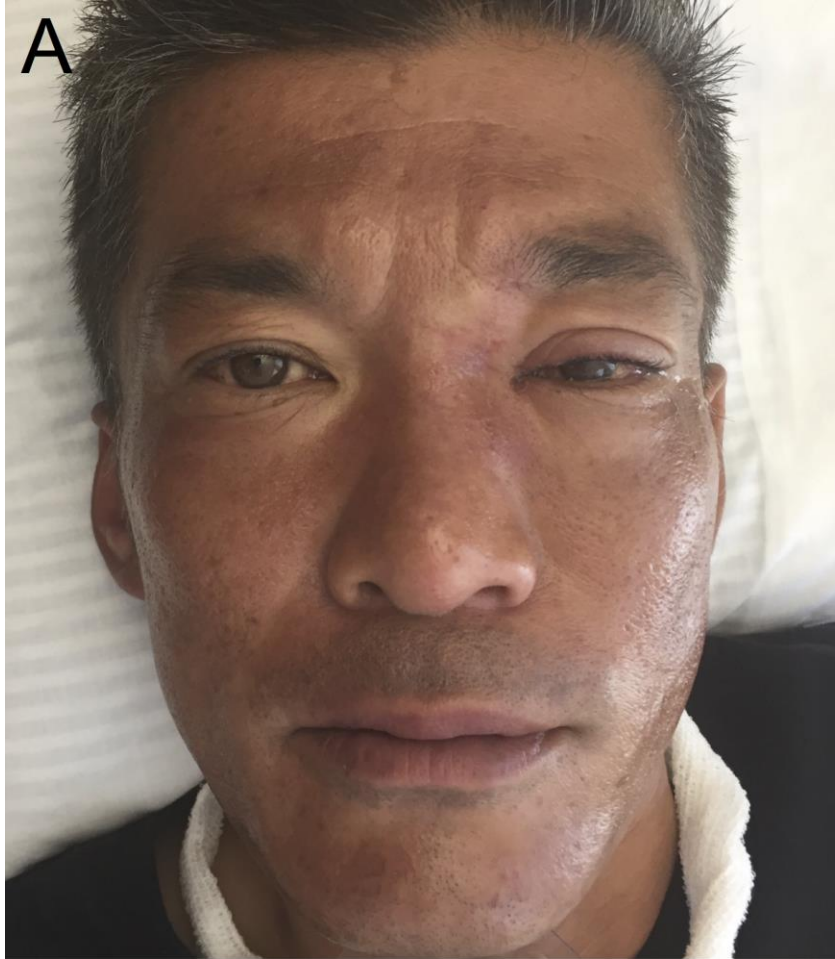*Neurology*

Resident and Fellow Section

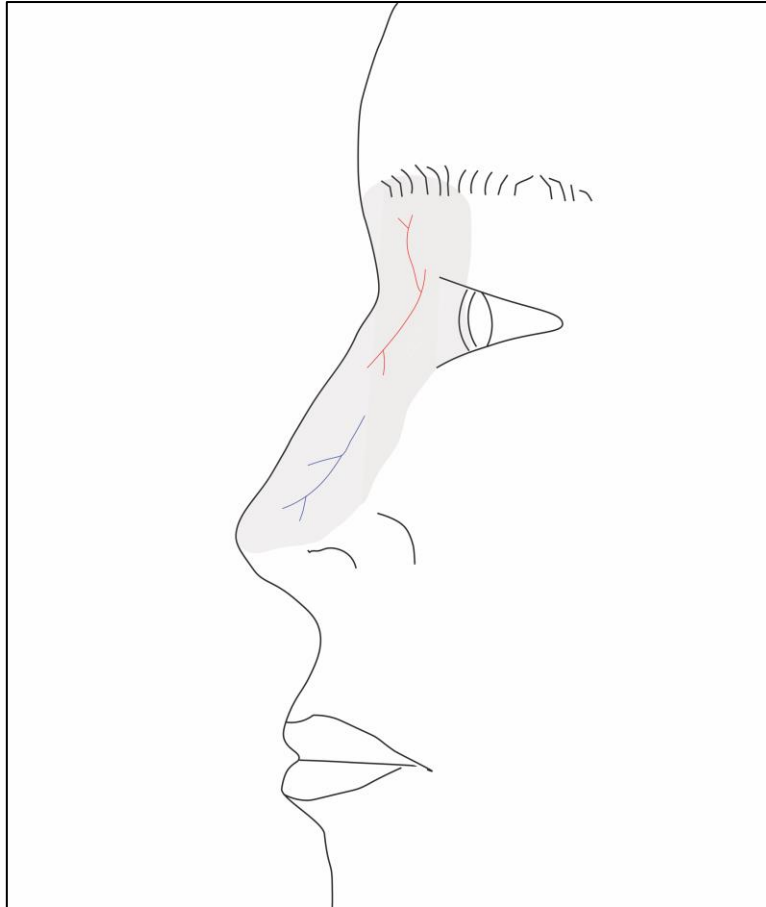
# Vignette

- 42-year-old man
  - Left-sided orbital and temporal stabbing pain
  - Ipsilateral lacrimation and conjunctival injection
  - Periorbital edema
- 
- On day 10, the rash in the root, dorsum, and apex of the nose became evident.
  - When the rash appeared, the patient had severe keratoconjunctivitis and iritis.

# Imaging



# Imaging



# Hutchinson's sign in Herpes Zoster Ophthalmicus

- Hutchinson's sign indicates the involvement of the nasociliary nerve.
- The nasociliary nerve is a branch of ophthalmic nerve innervating the eyelid, nose, and eye.
- The strong predictor of the ocular complications of Hepes Zoster Ophthalmicus.