

A 57-year-old woman with oropharynx pain

Teaching Neurolimages

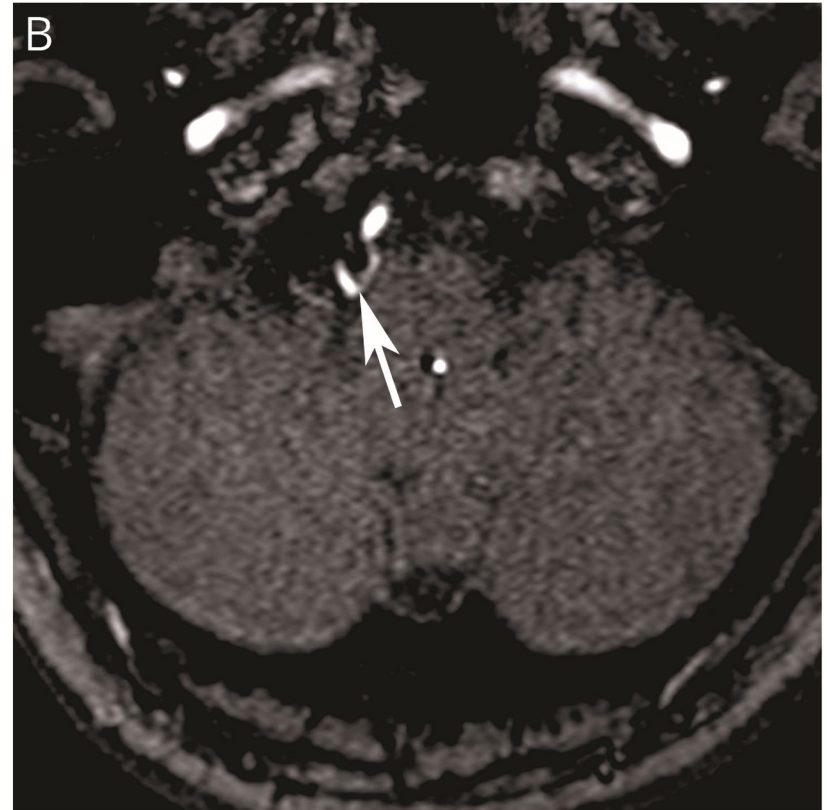
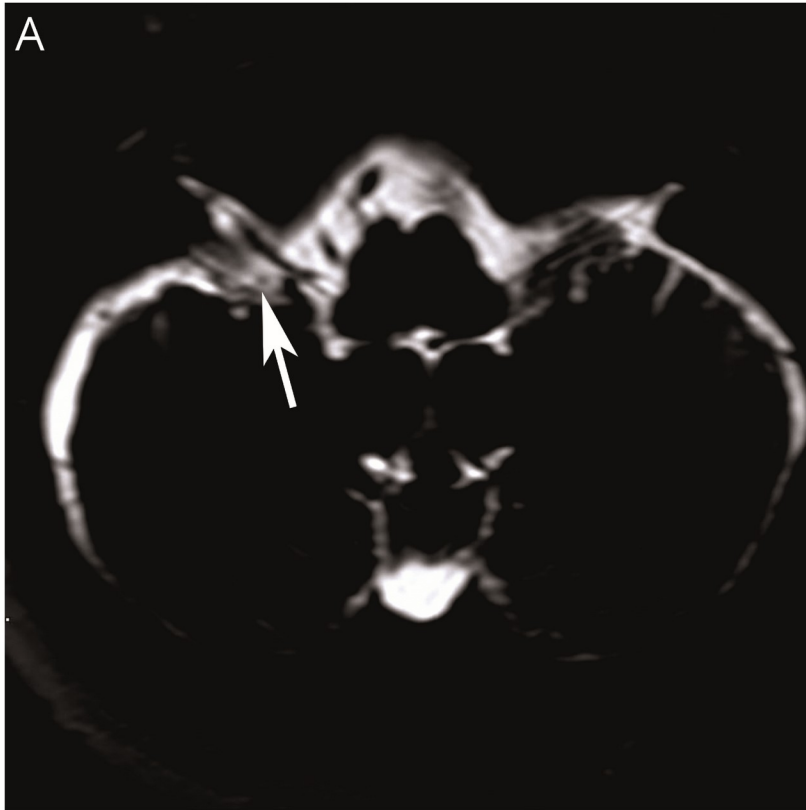
Neurology[®]

Resident & Fellow Section

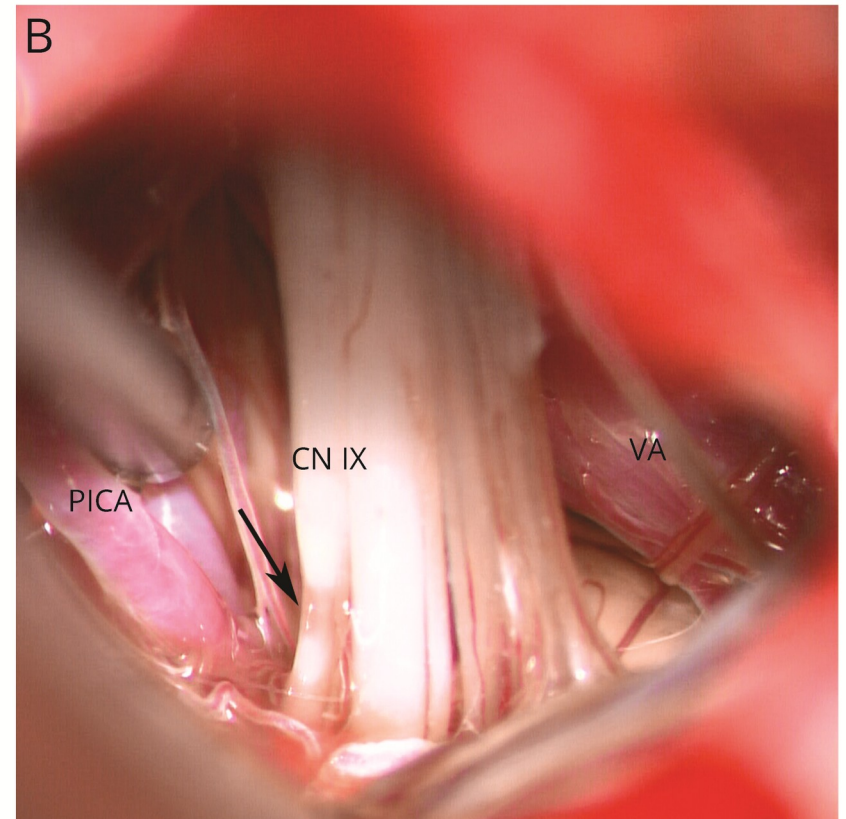
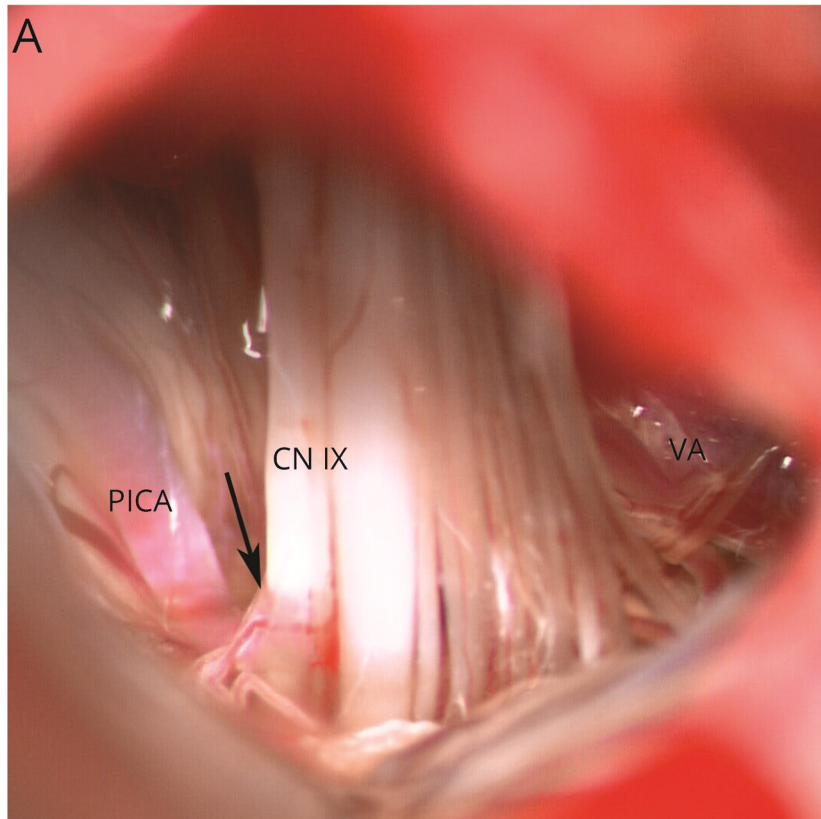
Presentation

- 1-year history of frequent, sharp, prickling pain in the right oropharynx.
- Symptom often triggered by swallowing or talking.
- Oxcarbazepine, Pregabalin and Mecobalamin were tried but pain relief was not satisfactory.

Imaging



Imaging



Glossopharyngeal Neuralgia

- Glossopharyngeal neuralgia is a rare condition characterized by paroxysmal sharp pain in the oropharynx.
- It is often caused by vascular compression of the glossopharyngeal nerve.
- Focal pressure atrophy of the nerve may be observed during microvascular decompression surgery , highlighting mechanic force as the cause for Glossopharyngeal neuralgia.