

# Teaching Video Neurolmages


*Neurology*<sup>®</sup>

Resident & Fellow Section

# VIGNETTE

- A 72- year- old man presented with fluctuating right eyelid ptosis.
- During sustained gaze fixation without blinking, the blepharoptosis progressively increased to almost complete ptosis, because of fatigable weakness of the levator palpebrae superioris muscle
- The patient was asked to close his eyes forcefully for 30 seconds

# Imaging: Video



# Imaging: Figure 1

Figure 1A

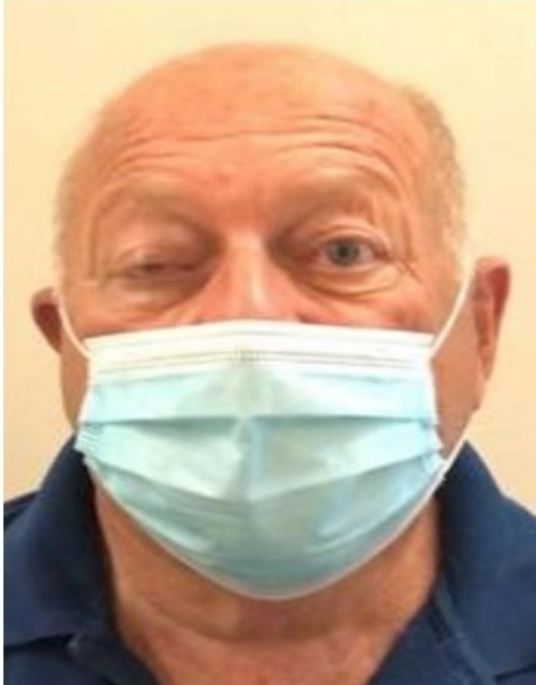

Figure 1B

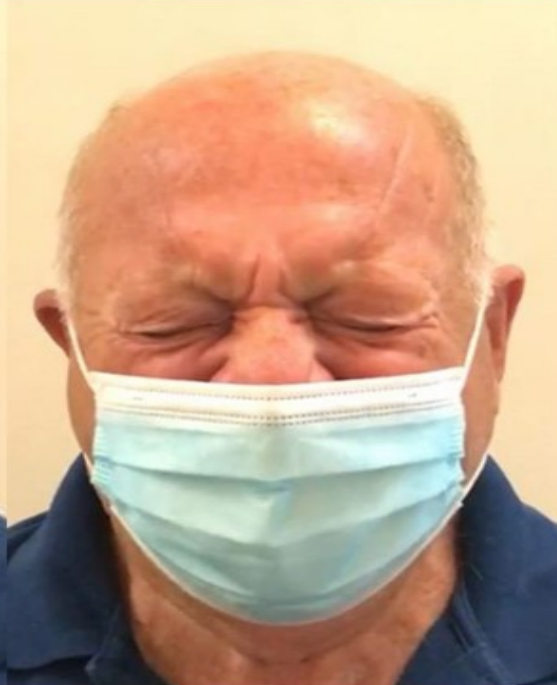
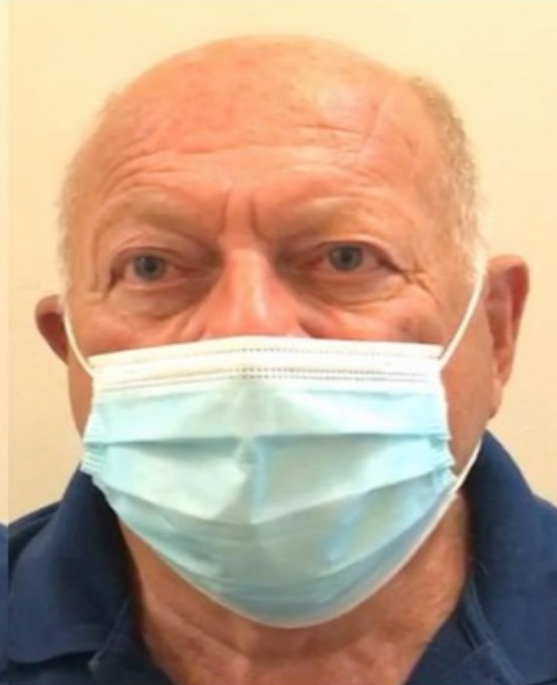
Figure 1C





# Resolution of Ptosis After Forceful Eye Closure: Bedside Diagnosis of Myasthenia Gravis

- The diagnosis is acetylcholine receptor antibody-positive ocular myasthenia gravis.
- The diagnostic bedside maneuver is called Bienfang's test, with a sensitivity and specificity of 94% and 91%, respectively.