

A 56 year old woman with recurrent
spontaneous vertigo and tinnitus

Teaching Video NeurolImages

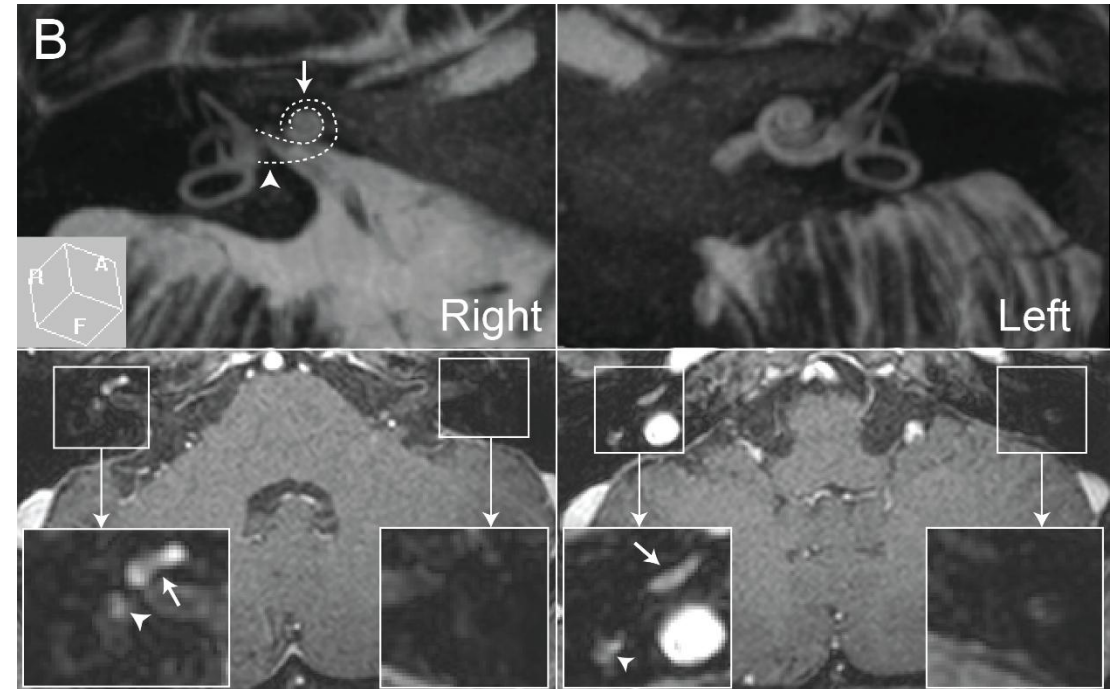
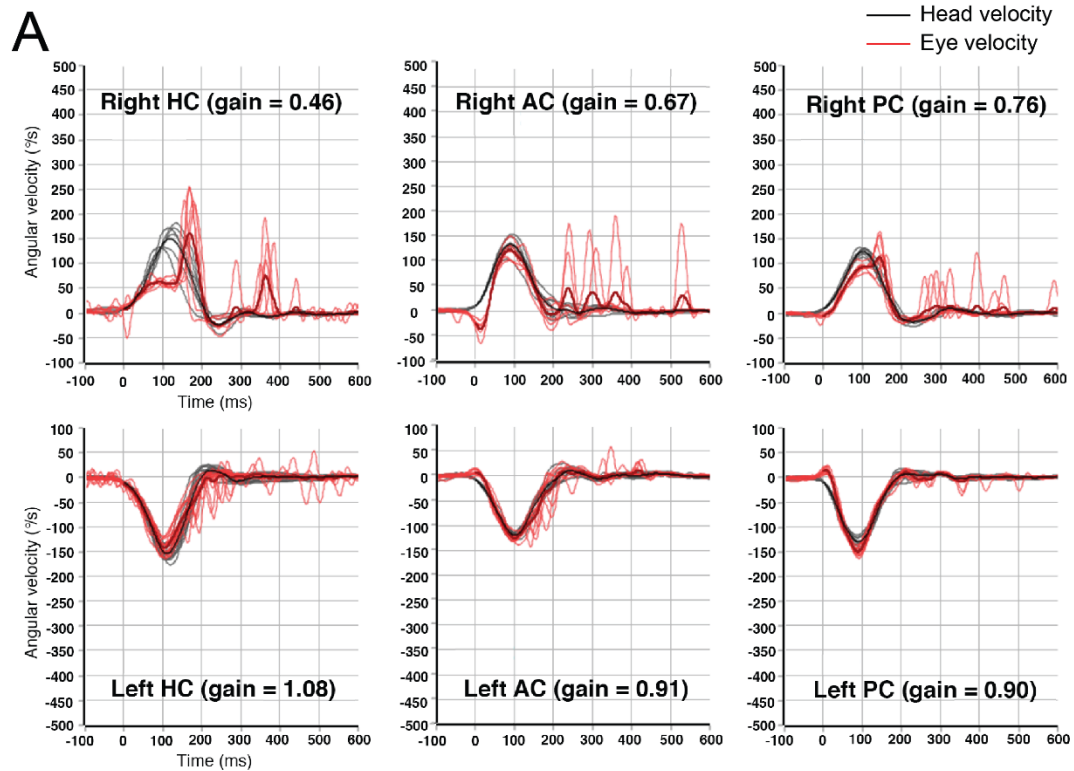
Neurology

Resident & Fellow Section


Vignette

- 56 year old woman
- Recurrent spontaneous vertigo, and fluctuating tinnitus and fullness in the right ear
- Spontaneous nystagmus beating leftward and counter-clockwise, which changed into right-beating during rightward gaze and after hyperventilation
- Positive head impulse tests, caloric paresis of 94%, and sensorineural hearing loss in the right ear
- MRI showed intralabyrinthine schwannoma in the right labyrinth

Video head-impulse test and MRIs



Video-oculography



Intralabyrinthine schwannoma masquerading as Meniere's disease

- Intralabyrinthine schwannoma is a rare and under-recognized cause of recurrent audiovestibulopathy, masquerading as Meniere's disease.¹
- High resolution MRIs allow antemortem diagnosis,² and labyrinthectomy may be attempted when refractory with medication.¹