

Neurology®

The most widely read and highly cited
peer-reviewed neurology journal


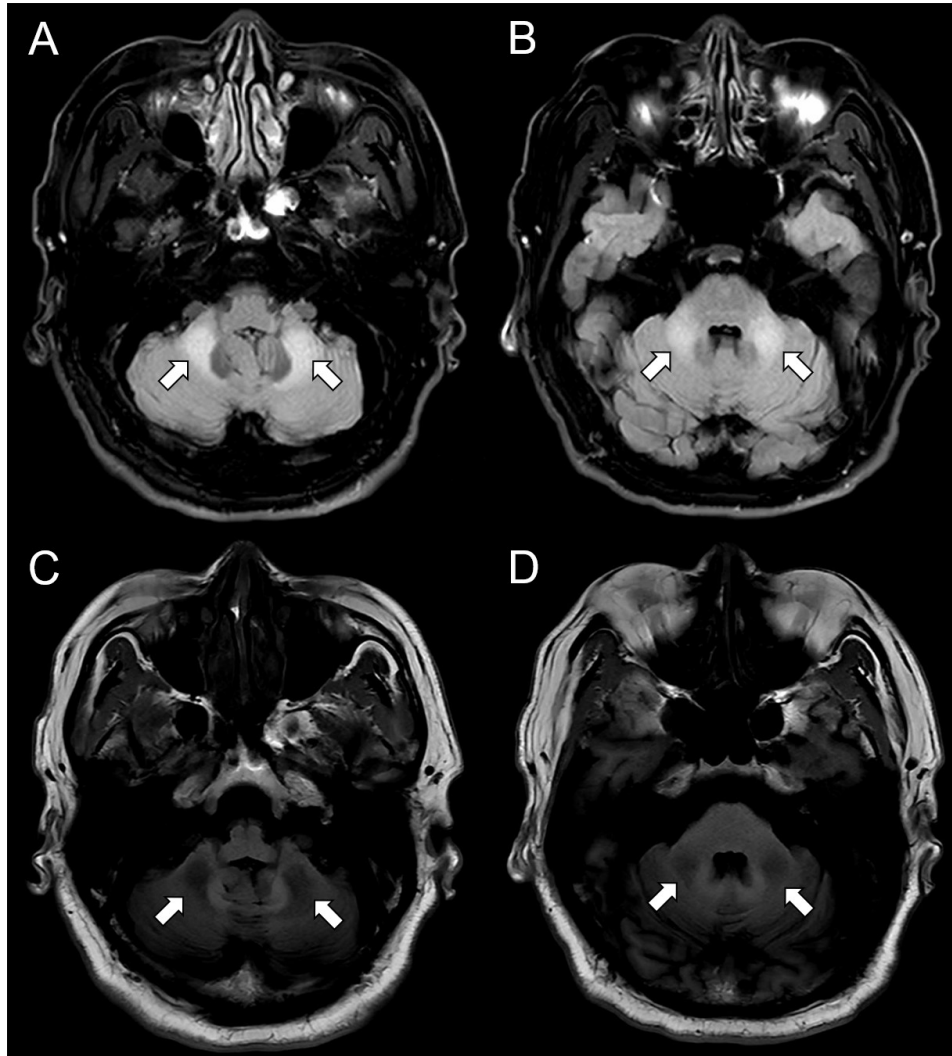
Resident & Fellow Section Teaching Video NeuroImages

A 63-Year-Old Male With Tremor and Cerebellar Ataxia

Vignette

- A 63-year-old male presented with a 3-year history of tremors.
- He had a head tremor, a lower limbs rest tremor, an irregular postural and intention tremor of distal upper limbs, and cerebellar ataxia.

Imaging



Fragile X-associated tremor/ataxia syndrome (FXTAS)

- FXTAS is an X-linked, late-onset, progressive neurodegenerative disease.¹
- T2-weighted brain MRI shows bilateral symmetric hyperintensities in the middle cerebellar peduncles.
- The characteristic MRI pattern should prompt confirmation of the diagnosis with genetic testing for *FMR1* premutations (55-200 CGG repeats).¹
- Fragile X syndrome, associated with *FMR1* full mutations (> 200 CGG repeats), should be differentiated.¹