

A 28-year-old man with new-onset binocular diplopia

By Edward Margolin and Seema Emami

Teaching Video NeuroImages

Neurology

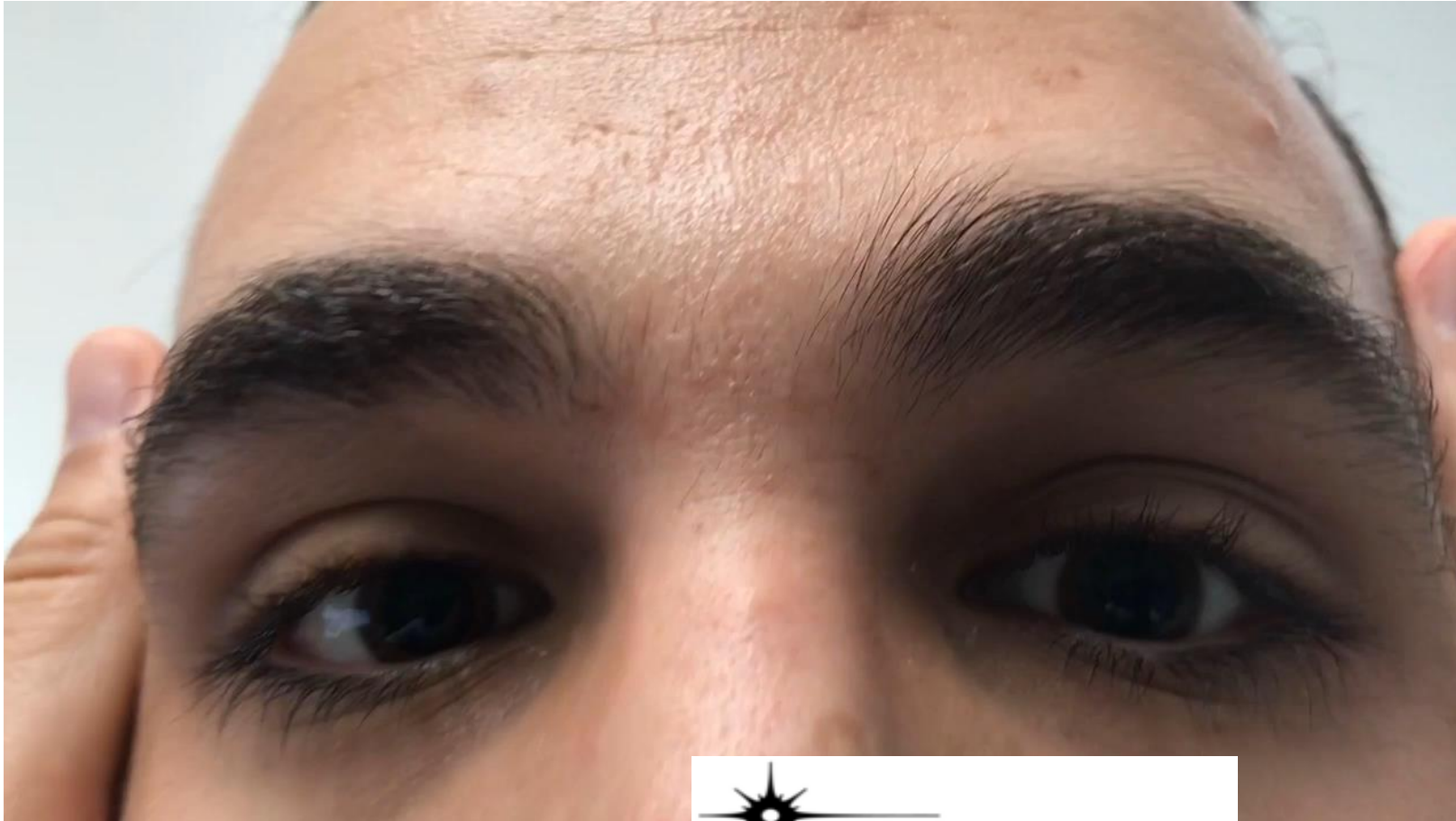Resident & Fellow Section

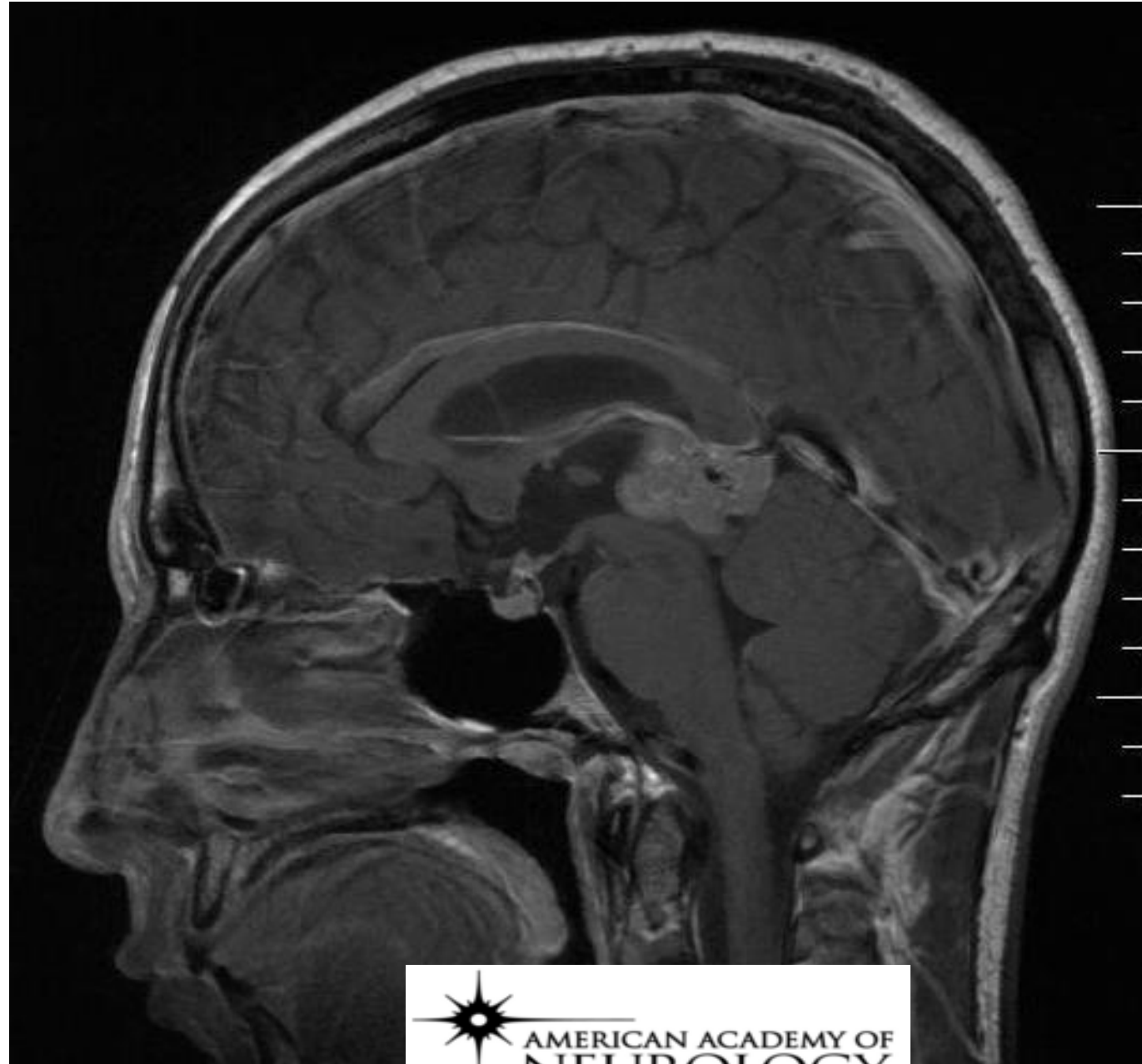


VIGNETTE

- A 28-year-old previously healthy man presented with 2 months' history of binocular diplopia, nocturnal polyuria and polydipsia.
- Extraocular motility testing demonstrated bilateral jerky convergence movements on attempted upgaze with mild lid retraction (Video 1).

Video





Margolin, et al

Convergence retraction nystagmus due to compressive lesion of the dorsal midbrain

- An urgent MRI of the brain demonstrated a large mass in the dorsal midbrain region causing compression of the hypothalamus. Low-dose radiotherapy was commenced for biopsy-proven germinoma.
- In this case, recognition of convergence retraction nystagmus allowed rapid localization of the lesion, unifying diagnosis, and eventually, treatment.