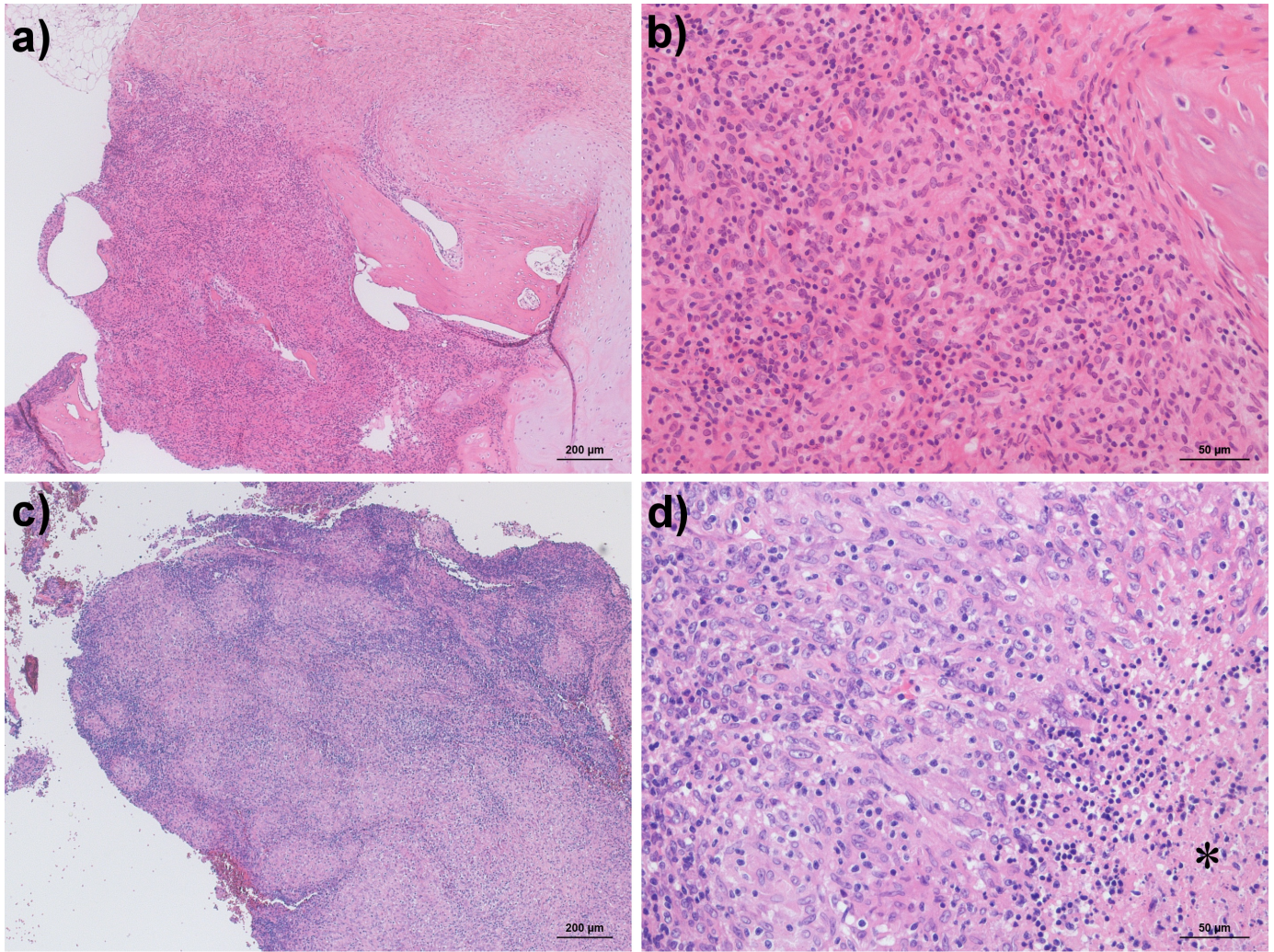


## Supplemental Digital Content



H&E stains of the first bone biopsy on the upper panel: a) Diffuse inflammatory infiltration of the bone marrow with scarring on the upper side and chondroid callus is shown on the right side. b) The inflammatory infiltrate consisted of macrophages, lymphocytes and granulocytes. Scarring and part of a bony trabeculum appear in the upper right. The lower panel shows H&E stains of the second bone biopsy six weeks later. c) Demarcated granulomatous infiltration of the bone marrow is apparent. d) The epitheloid cell wall surrounding a central necrosis (marked by asterisk) is shown.